

no CPXV DNA was amplifiable in the samples from the liver, lungs, or environment (online Technical Appendix Table 2).

CPXV infection may manifest in severe ocular forms along with self-limiting cutaneous pox (5). Our patient had keratitis with no other identifiable cause but CPXV. Culture and PCR from early conjunctival samples and serology confirmed the etiologic diagnosis.

Our case and that of another report (7) highlight the challenges of treating cowpox keratitis. Topical and systemic antiviral drugs and AMT appear ineffective during the acute phase. Corneal melting and scarring continued as long as CPXV was observed and until combined limbal stem cell and AMT treatment had favorable outcomes. Anamnesis of therapy-resistant keratitis should include information on rodent contacts.

We dated the infection to mid-August (incubation 7–21 days). Catching OPV-IgG-positive rodents close to the patient's home 2 months after onset showed that OPVs were circulating in the local rodent population and indicated the putative role of CPXV-infected voles as the source of infection.

The latest cowpox outbreak in Central Europe involved several humans and pets (8). This patient was born in 1977, after Finland ceased smallpox vaccinations. Declining cross-reactive smallpox-vaccination immunity enables emergence of unusual cowpox infections in humans (9).

Acknowledgments

We thank Katja Koskela with the Finnish Defence Forces for help with the sequence analysis program.

This research was partially funded by EU grant GOCE-2003-010284 EDEN.

References

- Putkuri N, Piiparinen H, Vaheri A, Vapalahti O. Detection of human orthopoxvirus infections and differentiation of smallpox virus with real-time PCR. *J Med Virol*. 2009;81:146–52. <http://dx.doi.org/10.1002/jmv.21385>
- Olson VA, Laue T, Laker MT, Babkin IV, Drosten C, Shchelkunov SN, et al. Real-time PCR system for detection of orthopoxviruses and simultaneous identification of smallpox virus. *J Clin Microbiol*. 2004;42:1940–6. <http://dx.doi.org/10.1128/JCM.42.5.1940-1946.2004>
- Pelkonen PM, Tarvainen K, Hynninen A, Kallio ERK, Henttonen H, Palva A, et al. Cowpox with severe generalized eruption, Finland. *Emerg Infect Dis*. 2003;9:1458–61. <http://dx.doi.org/10.3201/eid0911.020814>
- Mattila JS, Korsbäck A, Krootila K, Holopainen JM. Treatment of *Pseudomonas aeruginosa* keratitis with combined corneal cross-linking and human amniotic membrane transplantation. *Acta Ophthalmol*. 2013;91:e410–1. <http://dx.doi.org/10.1111/aos.12115>
- Haller SL, Peng C, McFadden G, Rothenburg S. Poxviruses and the evolution of host range and virulence. *Infect Genet Evol*. 2014;21:15–40. <http://dx.doi.org/10.1016/j.meegid.2013.10.014>
- Kinnunen PM, Henttonen H, Hoffmann B, Kallio ERK, Korthase C, Laakkonen J, et al. Orthopoxvirus infections in Eurasian wild rodents. *Vector Borne Zoonotic Dis*. 2011;11:1133–40. <http://dx.doi.org/10.1089/vbz.2010.0170>
- Graef S, Kurth A, Auw-Haedrich C, Plange N, Kern WV, Nitsche A, et al. Clinicopathological findings in persistent corneal cowpox infection. *JAMA Ophthalmol*. 2013;131:1089–91. <http://dx.doi.org/10.1001/jamaophthalmol.2013.264>
- Becker C, Kurth A, Hessler F, Kramp H, Gokel M, Hoffmann R, et al. Cowpox virus infection in pet rat owners: not always immediately recognized. *Dtsch Arztebl Int*. 2009;106:329–34.
- Rimoin AW, Mulembakani PM, Johnston SC, Lloyd Smith JO, Kisalu NK, Kinkela TL, et al. Major increase in human monkeypox incidence 30 years after smallpox vaccination campaigns cease in the Democratic Republic of Congo. *Proc Natl Acad Sci U S A*. 2010;107:16262–7. <http://dx.doi.org/10.1073/pnas.1005769107>

Address for correspondence: Paula M. Kinnunen, Finnish Food Safety Authority Evira, Mustialankatu 3, 00790 Helsinki, Finland; email: paula.kinnunen@helsinki.fi

Human Alveolar Echinococcosis, Czech Republic, 2007–2014

Libuše Kolářová, Jana Matějů, Jiří Hrdý, Hana Kolářová, Lubomíra Hozáková, Vita Žampachová, Herbert Auer, František Stejskal

Author affiliations: National Reference Laboratory for Tissue Helminthoses, General University Hospital, Prague, Czech Republic (L. Kolářová, J. Matějů); Charles University First Faculty of Medicine, Prague (L. Kolářová, J. Matějů, J. Hrdý, František Stejskal, H. Kolářová); University Hospital, Ostrava, Czech Republic (L. Hozáková); Masaryk University Faculty of Medicine, Brno, Czech Republic (V. Žampachová); St. Anne's University Hospital, Brno (V. Žampachová); Medical University Vienna, Austria (H. Auer)

DOI: <http://dx.doi.org/10.3201/eid2112.150743>

To the Editor: Human alveolar echinococcosis (AE) is a zoonotic parasitic disease caused by larvae of *Echinococcus multilocularis* tapeworms that manifests most often in the host's liver, although it can infect the lungs, brain, and other organs. Clinical symptoms usually develop after a long incubation period (5–15 years), causing considerable diagnostic difficulties and delay in treatment. The disease is reported in all countries neighboring the Czech Republic: Slovakia, Poland, Austria, and Germany (1,2). To complete data from central Europe, we present results on the occurrence of AE in the Czech Republic collected by the National Reference Laboratory for Tissue Helminthoses during 2007–2014.

In the Czech Republic, the occurrence of *E. multilocularis* in definitive (red fox, dog, cat, raccoon dog) and intermediate (bank vole) hosts was reported (3). After the first reports on detection of the parasites in foxes during 1995 (4; Figure), physicians started to request laboratory examinations for AE in persons with liver lesions, suspicious clinical symptoms, or both. During 1998–2014, examinations of 1,892 patients revealed 20 AE cases (12 women, 8 men); the first 2 cases were diagnosed during 2007 (5,6). In all cases, the diagnosis was based on AE characteristic imaging by using ultrasonography, computed tomography, magnetic resonance imaging, or a combination of these methods; in 19 (95%) cases, the results were confirmed by *E. multilocularis*-specific serology. In-house *E. multilocularis* crude-antigen was used for ELISA and Western blot testing and for ELISA IgG for detection of *E. multilocularis*. Em2–Em18 antibodies (Bordier Affinity Products SA, Crissier, Switzerland) were used for some laboratory examinations. Since 2009, in-house Western blot has been done by using a commercial set (LDBIO, Lyon, France).

In 18 cases, AE was also confirmed by characteristic histopathologic findings, species-specific molecular analysis of tissue biopsies, or both. PCR assay according to Schneider et al. (7) has been used in the National Reference Laboratory since 2011. In 17 (85%) patients, the liver was the only affected organ, and the infection was classified according to Brunetti et al. (8) as PN0M0; in 3 patients, liver and brain (PN0M1), retroperitoneum (PN1M0), or kidneys (PN1M0) were also affected.

Analysis of gender and age at the time of initial AE diagnosis showed that the youngest and the oldest patients were 21 and 82 years old, respectively. To examine

differences in non-Gaussian distributed variables between male and female patients, we used the 2-way Mann-Whitney nonparametric test (GraphPad, San Diego, CA, USA) to analyze age data. The mean and median age of patients were lower among women (mean 45, median 36.5 years) than in men (mean 53, median 60 years), but these differences were not statistically significant ($p>0.05$).

According to the site of residence, the patients originated from different parts of the Czech Republic (Figure). The disease was diagnosed in 18 native Czech citizens and in 2 citizens from Slovakia.

Physicians interviewed 17 of 20 patients in whom AE was diagnosed and completed questionnaires with patient data including clinical signs and symptoms, laboratory findings, and medical history (e.g., job, hobbies, travels abroad, ownership of animals) at the time of the first medical visit before diagnosis. Ten patients reported a prickling sensation and abdominal discomfort or pain. Three patients palpated a solid mass in the right hypochondrium before physical examination. Another 3 patients reported fever, fatigue, or malaise; 1 patient reported weight loss. The first clinical examinations by physicians revealed hepatomegaly in 16 patients; in addition, 3 of these patients had anemia and 1 had jaundice.

In the medical history, dog or cat ownership, gardening, farming, or hunting were recorded in some cases, which is similar to what was reported by Kern et al. (10). Of 15 persons interviewed who were native to the Czech Republic, 6 reported no travel outside the country (Figure). Because of the occurrence of *E. multilocularis* in animals (Figure), we assume that AE may have a characteristic of autochthonous infection in the Czech Republic.

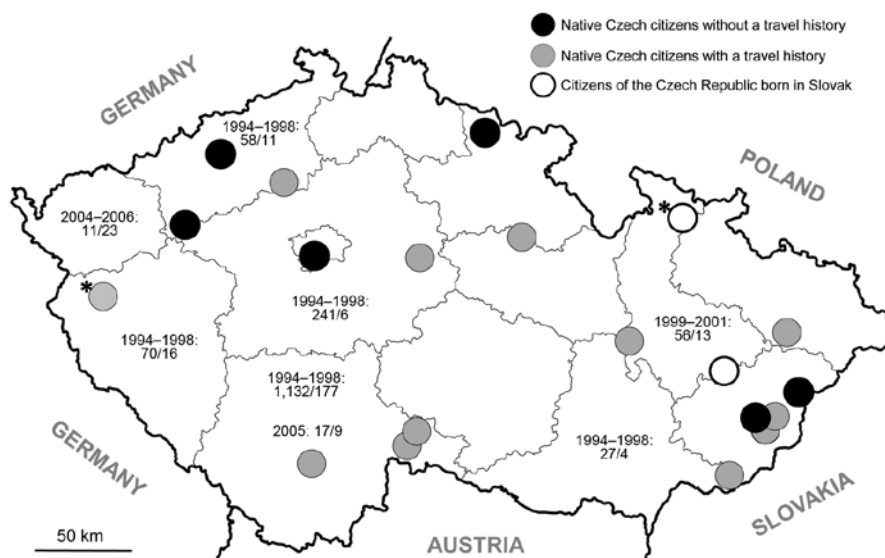


Figure. Distribution of human alveolar echinococcosis (AE) in the Czech Republic during 2007–2014, according to the site of residence of 20 case-patients, including their travel history. Asterisks (*) indicate AE cases already published (6,7). Six patients reported no travel outside the country; 2 patients were born in Slovakia and lived in the Czech Republic for 5 and 14 years before the time of initial AE diagnosis; the remaining patients traveled from the Czech Republic to various countries, including those to which AE is endemic. Nonperiodic examinations of red foxes (4,9) revealed the presence of *Echinococcus multilocularis* in the country. Date ranges indicate the period of examination; numbers separated by virgules indicate the number of foxes examined and those that tested positive, respectively.

The 2 patients from Slovakia lived in the Czech Republic for 5 (5) and 14 years, respectively, before the diagnosis of AE. Considering the long incubation period of the disease, these patients were likely infected in Slovakia, where occurrence of AE is also reported (7).

In summary, we report 20 cases of human AE in the Czech Republic during 1998–2014. However, because asymptomatic patients with only mild liver involvement are unlikely to seek clinical investigation, the actual number of patients in the Czech Republic who have AE is expected to be even higher than that reported here.

Acknowledgments

We thank Markéta Leissová and Petra Kotíková for technical assistance during the examination.

The study was supported by the Charles University in Prague (Research Programs PRVOUK No. P25/LF1/2 and UNCE–Grant No. 204017), and Grant Agency of the Ministry of Health IGA MZCR NT 13108-4/2012.

L.K. conceived and wrote the paper. J.M., J.H., H.K., L.H., V.Z., H.A., and F.S. participated in the design of the analysis, commented on the first draft of the paper, and approved the final version.

References

- Antolová D, Miterpáková M, Radoňák J, Hudačková D, Szilagyiová M, Žáček M. Alveolar echinococcosis in a highly endemic area of northern Slovakia between 2000 and 2013. *Euro Surveill*. 2014;19: 1560–7917. <http://dx.doi.org/10.2807/1560-7917.ES2014.19.34.20882>
- Nahorski W, Knap J, Pawlowski ZS, Krawczyk M, Polański J, Stefaniak J, et al. Human alveolar echinococcosis in Poland 1990–2011. *PLOS Negl Trop Dis*. 2013;7:e1986. <http://dx.doi.org/10.1371/journal.pntd.0001986>
- Svobodová V, Stejskal F, Kolářová L, Pijáček M. Risk of zoonotic echinococcosis in the Czech Republic [in Czech]. *Veterinarství*. 2014;64:515–21.
- Pavlásek I. Actual situation in the occurrence of *Echinococcus multilocularis* in foxes from Europe and the Czech Republic [in Czech]. *Rem-Klin mikrobiol* 1998;2:233–240.
- Hozáková-Lukáčová L, Kolářová L, Rožnovský L, Hiemer I, Denemark L, Čuřík R, et al. Alveolar echinococcosis—a new emerging disease [in Czech] *Cas Lek Cesk*. 2009;148:132–6.
- Skalický T, Třešák V, Martinek K, et al. Alveolar echinococcosis—a scarce case of the liver impairment in the Czech Republic [in Czech]. *Ces Slov Gastroent Hepatol*. 2008;62:30–3.
- Schneider R, Gollackner B, Edel B, Schmid K, Wrba F, Tucek G, et al. Development of a new PCR protocol for the detection of species and genotypes (strains) of *Echinococcus* in formalin-fixed, paraffin-embedded tissues. *Int J Parasitol*. 2008;38:1065–71. <http://dx.doi.org/10.1016/j.ijpara.2007.11.008>
- Brunetti E, Kern P, Vuitton D, Writing Panel for the WHO-IWGE. Expert consensus for the diagnosis and treatment of cystic and alveolar echinococcosis in humans. *Acta Trop*. 2010;114:1–16. <http://dx.doi.org/10.1016/j.actatropica.2009.11.001>
- Žákovčik V, Cihlár D. Occurrence of *Echinococcus multilocularis* tapeworms in foxes at Vojenské újezdy [in Czech]. *Cas zamest Voj les stat CR*, s.p. 2007;2:14–16 [cited 2015 Sep 9]. <http://www.vojuzezd-hradiste.cz/soubory/4746/Echinokokoza.pdf>
- Kern P, Bardonnat K, Renner E, Auer H, Pawlowski Z, Ammann RW, et al. European echinococcosis registry: human alveolar echinococcosis, Europe, 1982–2000. *Emerg Infect Dis*. 2003;9:343–9. <http://dx.doi.org/10.3201/eid0903.020341>

Address for correspondence: Libuše Kolářová, National Reference Laboratory for Tissue Helminthoses, Studničkova 7, CZ-128 00 Prague 2, Czech Republic; email: libuse.kolarova@lf1.cuni.cz

Use of Capture–Recapture to Estimate Underreporting of Ebola Virus Disease, Montserrado County, Liberia

Etienne Gignoux, Rachel Idowu, Luke Bawo, Lindis Hurum, Armand Sprecher, Mathieu Bastard, Klaudia Porten

Author affiliations: Epicentre, Paris, France (E. Gignoux, M. Bastard, K. Porten); Centers for Disease Control and Prevention, Atlanta, Georgia, USA (R. Idowu); Ministry of Health and Social Welfare, Monrovia, Liberia (L. Bawo); Médecins Sans Frontières, Brussels, Belgium (L. Hurum, A. Sprecher)

DOI: <http://dx.doi.org/10.3201/eid2112.150756>

To the Editor: Underreporting of cases during a large outbreak of disease is not without precedent (1–5). Health systems in West Africa were ill-prepared for the arrival of Ebola virus disease (Ebola) (6). The Ebola outbreak in Liberia was declared on March 31, 2014, and peaked in September 2014. However, by mid-June, the outbreak had reached Montserrado County, where the capital, Monrovia, is located. In response, the Liberia Ministry of Health and Social Welfare (MOHSW) created a National Ebola Hotline: upon receipt of a call, a MOHSW case investigation team was dispatched to the site of the possible case. Additionally, persons could seek care at an Ebola Treatment Unit (ETU) or be referred to an ETU by another health care facility. During June 1–August 14, 2014, MOHSW, Médecins Sans Frontières, and the US nongovernment organization Samaritan’s Purse managed 3 ETUs in Montserrado County, including 2 in Monrovia operated by Eternal Love Winning Africa (ELWA).

In August 2014, to assess the extent of underreporting in the midst of the Ebola outbreak, we analyzed 2 sources of data collected during June 1–August 14. The first comprised data collected by MOHSW case investigation teams. These data were collected on MOHSW case forms and entered into a database emulating these forms using Epi Info version 7 software (Centers for Disease Control and Prevention, Atlanta, GA, USA). The second data source