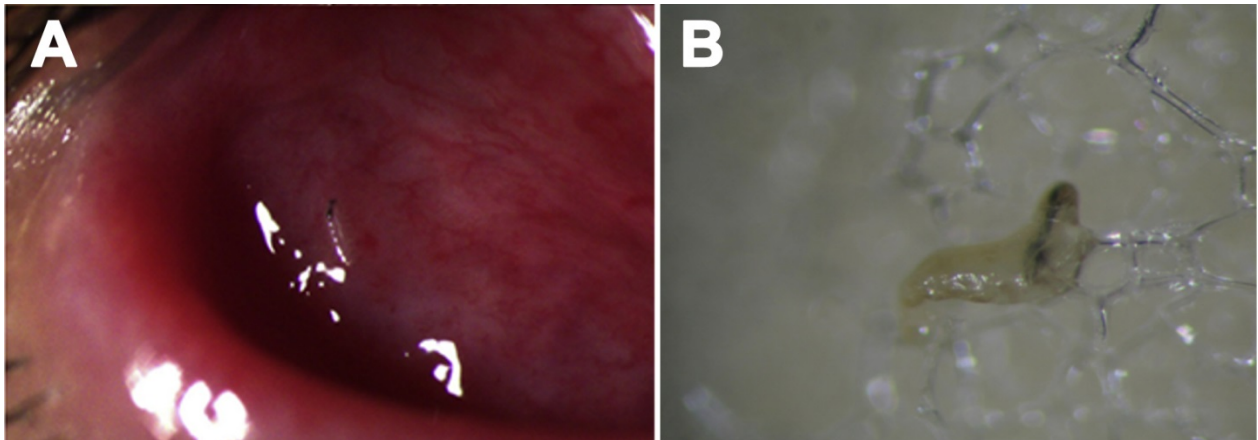


Clustered Cases of *Oestrus ovis* Ophthalmomyiasis after Three-Week Festival, Marseille, France, 2013

Technical Appendix



Technical Appendix Figure. *Oestrus ovis* larva on the eye of case-patient 1 and after collection. A) *Fornix conjunctiva* of case-patient 1 showing chemosis (conjunctival edema) and larva of *Oestrus ovis*. B) Larva collected from *Fornix conjunctiva* on swab.