

(i.e., East Anacapa and Santa Barbara Islands) or high prevalence (i.e., San Miguel and Santa Rosa Islands).

Future studies comparing long-term dynamics on islands and related mainlands are needed to examine the possibility that insular systems provide unique opportunities to understand the factors affecting pathogen dynamics and human risk. Given the substantial variation in mouse population density among different habitats within these islands and variation in prevalence among trapping areas in our study (Table) and others (4), we also recommend that future studies focus on the diverse array of habitats where *P. maniculatus* is found on the islands to more completely characterize within-island risk.

Acknowledgments

We thank T. Rusca for outstanding assistance with data collection; the National Park Service, especially the staff at the Channel Islands National Park, for providing essential logistical support; C. Fritz, R. Davis, and B. Enge for sample processing; and C. Schwemm and W. Ryberg for helpful suggestions on drafts of the manuscript.

This work was supported by National Science Foundation grant DEB-0502069 to J.L.O. and a National Fish and Wildlife Foundation Budweiser Conservation Scholarship to B.F.A. All protocols were approved by the Institutional Animal Care and Use Committee at the University of California, Santa Barbara.

John L. Orrock and Brian F. Allan

Author affiliation: Washington University, St. Louis, Missouri, USA

DOI: 10.3201/eid1412.080935

References

- Childs JE, Ksiazek TG, Spiropoulou CF, Krebs JW, Morzunov S, Maupin GO, et al. Serologic and genetic identification of *Peromyscus maniculatus* as the primary rodent reservoir for a new hantavirus in the southwestern United States. *J Infect Dis.* 1994;169:1271–80.
- Jay M, Ascher MS, Chomel BB, Madon M, Sesline D, Enge BA, et al. Seroepidemiologic studies of hantavirus infection among wild rodents in California. *Emerg Infect Dis.* 1997;3:183–90.
- Childs JE, Mackenzie MS, Richt JA, editors. Pre-spillover prevention of emerging zoonotic diseases: what are the targets and what are the tools? *Wildlife and emerging zoonotic diseases: the biology, circumstances and consequences of cross-species transmission*; Berlin: Springer; 2007. p. 389–443.
- Graham TB, Chomel BB. Population dynamics of the deer mouse (*Peromyscus maniculatus*) and Sin Nombre virus, California Channel Islands. *Emerg Infect Dis.* 1997;3:367–70.
- Feldmann H, Sanchez A, Morzunov S, Spiropoulou CF, Rollin PE, Ksiazek TG, et al. Utilization of autopsy RNA for the synthesis of the nucleocapsid antigen of a newly recognized virus associated with hantavirus pulmonary syndrome. *Virus Res.* 1993;30:351–67. DOI: 10.1016/0168-1702(93)90101-R
- Mills JN, Ksiazek TG, Peters CJ, Childs JE. Long-term studies of hantavirus reservoir populations in the southwestern United States: a synthesis. *Emerg Infect Dis.* 1999;5:135–42.
- Madhav NK, Wagoner KD, Douglass RJ, Mills JN. Delayed density-dependent prevalence of Sin Nombre virus antibody in Montana deer mice (*Peromyscus maniculatus*) and implications for human disease risk. *Vector Borne Zoonotic Dis.* 2007;7:353–64. DOI: 10.1089/vbz.2006.0605
- Schwemm CA, Coonan TJ. Status and ecology of deer mice (*Peromyscus maniculatus* subsp.) on Anacapa, Santa Barbara, and San Miguel Islands, California: summary of monitoring 1992–2001. Ventura (CA): United States Department of Interior, National Park Service, Channel Islands National Park; 2001.

Address for correspondence: John L. Orrock, Department of Biology, Washington University, 1 Brookings Dr, St. Louis, MO 63130, USA; email: orrock@wustl.edu

The opinions expressed by authors contributing to this journal do not necessarily reflect the opinions of the Centers for Disease Control and Prevention or the institutions with which the authors are affiliated.

***Parachlamydia acanthamoebae* Infection and Abortion in Small Ruminants**

To the Editor: Abortion in ruminants is of worldwide economic importance. Moreover, several abortigenic agents have a zoonotic potential, i.e., *Brucella abortus*, *Coxiella burnetii*, and *Chlamydophila abortus*. *C. abortus*, which causes ovine enzootic abortion, may also infect pregnant women who have had contact with *C. abortus*-infected sheep and goats, and such infection can lead to miscarriage (1).

Parachlamydia acanthamoebae (2) is a *Chlamydia*-related organism considered as an emerging agent of pneumonia in humans. Recently, we reported its role in the setting of bovine abortion (3). Here, we investigated the prevalence of *C. abortus* and *P. acanthamoebae* infections in abortions in small ruminants.

Formalin-fixed placenta, fetal lung and liver, or both, were available from abortion products from 144 goats and 86 sheep (n = 211). These specimens had previously been investigated for several abortigenic agents (4). Placentas and fetal organs were analyzed by histopathologic examination and by specific real-time PCR and immunohistochemical protocols that detect members of the *Chlamydiaceae* family and *P. acanthamoebae*.

DNA from paraffin blocks was extracted as described (5) by using the DNeasy Tissue kit (QIAGEN, Hilden, Germany). The real-time PCR for *Chlamydiaceae* was conducted on an ABI 7500 (Applied Biosystems, Foster City, CA, USA) by using a modified version of Everett's PCR (6). Primers Ch23S-F (5'-CTGAAACCAGTAGCTTATAAGCGGT-3'), Ch23S-R (5'-ACCTCGCCGTTTAACTTA ACTCC-3'), and probe Ch23S-p (5'-FAM-CTCATCATGCAAAGGCA CGCCG-TAMRA-3') were used to

amplify and detect a 111-bp product specific for members of the family *Chlamydiaceae*. Chlamydial species identification of real-time PCR positive cases was performed with the ArrayTube Microarray (Clondiag, Jena, Germany) as described (7).

The *Parachlamydia*-specific real-time PCR was performed with the ABI Prism 7000 sequence detection system (Applied Biosystems), as reported (8). This PCR is genus-specific, as demonstrated by the absence of PCR positivity with DNA extracted from other *Parachlamydiaceae* (*Protochlamydia* spp./*Neochlamydia hartmannellae*). To confirm positive results, another specific PCR, which targeted the *tlc* gene, was performed (9).

Paraffin sections from specimens positive in real-time PCR were further examined by immunohistochemical tests. A *Chlamydiaceae*-specific mouse monoclonal antibody directed against the chlamydial lipopolysaccharide (Progen, Heidelberg, Germany) and a specific mouse polyclonal antibody against *Parachlamydia* spp. was used as described (3,5,10). These antibodies were applied at dilutions of 1:200 and 1:1,000, respectively. Detection was performed with a detection kit (ChemMate; Dako, Glostrup, Denmark). Antigen retrieval was performed by enzyme digestion for 10 minutes (Pro-nase; Dako) for the *Chlamydiaceae* antibody and repeated microwave treatment in citrate buffer (ChemMate; Dako) for the *Parachlamydia* antibody, respectively. Double immunohistochemical labeling was performed on the sheep abortion specimen identified as simultaneously infected with *Chlamydiaceae* and *Parachlamydia* spp. Immunohistochemical analysis for both pathogens was performed subsequently by using diaminobenzidine as substrate for the *Chlamydiaceae* antibody (brown labeling) and by using 3-amino-9-ethylcarbazole as substrate for the *Parachlamydia* antibody (red labeling). Specificity of PCR and immunohistochemical tests for *Chla-*

mydiaceae and *Parachlamydia* spp., respectively, was assessed by using negative control placentas taken from 2 healthy ruminants (both specimens were negative in all tests).

Results of real-time PCR showed that 55 (26.1%) of 211 specimens were positive for *Chlamydiaceae*. All 55 cases could be identified as *C. abortus* by ArrayTube Microarray (Clondiag). Of these, 42 (76.4%) could be confirmed by immunohistochemical analysis with the anti-*Chlamydiaceae* antibody.

Of the 211 specimens, only 2 (0.9%) were positive for *Parachlamydia* spp. by real-time PCR, and

both cases could be confirmed by immunohistochemical testing with the parachlamydial antibody. These 2 specimens were negative for other common abortigenic agents such as *Toxoplasma gondii*, *C. burnetii*, and border disease virus (data not shown). One case was recorded among the 144 goat samples investigated. This placenta displayed necrotizing placentitis and was positive for *Parachlamydia* spp. by 16S rRNA-specific real-time PCR (cycle threshold [Ct] 40.5) and immunohistochemical testing, but negative for *Chlamydiaceae*. Results of this PCR was confirmed by another PCR, targeting the *tlc* gene (Ct 36.7),

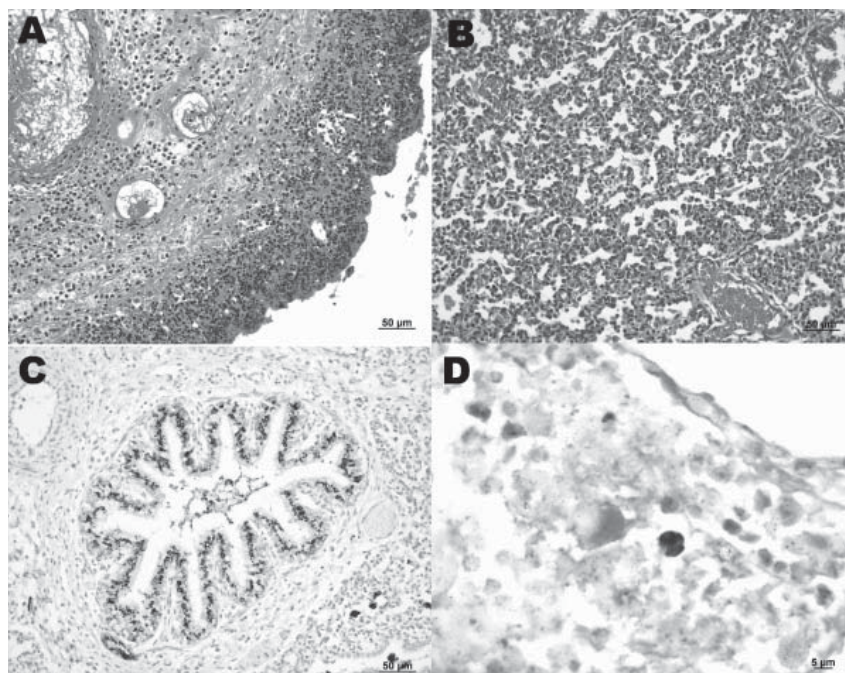


Figure. A) Sheep placenta positive by real-time PCR and immunohistochemistry for *Parachlamydia* spp. and *Chlamydiaceae*. *Chlamydomphila abortus* was identified by ArrayTube Microarray. Necrotizing placentitis and vasculitis are shown (hematoxylin and eosin stain; magnification $\times 200$). B) Fetal lung of the sheep abortion specimen positive by real-time PCR and immunohistochemical tests for *Parachlamydia* spp. and *Chlamydiaceae*; interstitial pneumonia is shown (hematoxylin and eosin stain; magnification $\times 200$). C) Fetal lung that was positive by real-time PCR and immunohistochemical testing for *Parachlamydia* spp. Positive granular material can be seen within the lung tissue. Antigen detection (immunohistochemistry) was carried out with a polyclonal antibody directed against *Parachlamydia* spp. 3-amino-9-ethylcarbazole/peroxidase method (hematoxylin counterstain; magnification $\times 200$). D) Double immunohistochemical labeling of the sheep placenta that was positive by real-time PCR and immunohistochemical tests for *Chlamydiaceae* and *Parachlamydia* spp. The simultaneous presence of *Chlamydiaceae* and *Parachlamydia* spp. granular reaction is shown within necrotic trophoblastic epithelium and neutrophilic exudate (diaminobenzidine/AEC/peroxidase method, hematoxylin counterstain; magnification $\times 1,000$). A color version of this figure is available online (www.cdc.gov/EID/content/14/12/1966-F.htm).

which excluded false-positive results because of amplicon contamination.

The second case was identified among the 86 sheep investigated. Placenta and fetal lung and liver exhibited necrotizing placentitis and vasculitis (Figure, panel A), interstitial pneumonia (Figure, panel B), and mixed cellular periportal hepatitis. Fetal liver was negative by parachlamydial 16S rRNA real-time PCR and immunohistochemical analysis, but the fetal lung was positive by parachlamydial 16S rRNA real-time PCR (Ct 40.7) and immunohistochemical tests (Figure, panel C), but negative with the *tlc* PCR. Fetal lung and liver were positive by real-time PCR for *Chlamydiaceae* (mean Ct for both organs 36.7), but negative by immunohistochemical tests. The placenta was positive for *Chlamydiaceae* by immunohistochemical tests and real-time PCR (mean Ct 23.3), and *C. abortus* was identified by ArrayTube Microarray. Brown (*Chlamydiaceae*) and red (*Parachlamydia* spp.) granular reaction was demonstrated within the necrotic lesions of the placenta by double immunohistochemical labeling (Figure, panel D).

We report *Parachlamydia* infection in small ruminant abortion. *C. abortus* and *Parachlamydia* spp. were simultaneously present in an aborted sheep placenta. *Parachlamydia* spp. could be further detected in the lung of the aborted sheep fetus by real-time PCR and immunohistochemistry. *Parachlamydia* was also detected in a goat placenta. Thus, *Parachlamydia* spp. should be considered as a new abortigenic agent in sheep and goats. Persons in contact with small ruminants should be informed about the zoonotic potential of these abortigenic agents.

Acknowledgments

We are grateful to the laboratory staff (in particular, Carmen Kaiser) of the Institute of Veterinary Pathology, Vetsuisse Faculty, University of Zurich.

This study was supported by the State Secretary for Education and Research, Bern, Switzerland (project number C05.0141), as part of the COST Action 855 (Animal Chlamydiosis and Zoonotic Implications).

G.G. is supported by the Leenards Foundation through a career award entitled "Bourse Leenards pour la relève académique en médecine clinique à Lausanne."

**Silke Ruhl, Genevieve Goy,
Nicola Casson, Rudolf Thoma,
Andreas Pospischil, Gilbert
Greub, and Nicole Borel**

Author affiliations: University of Zurich, Zurich, Switzerland (S. Ruhl, A. Pospischil, N. Borel); University of Lausanne, Lausanne, Switzerland (G. Goy, N. Casson, G. Greub); and Cantonal Laboratory of Veterinary Bacteriology, Chur, Switzerland (R. Thoma)

DOI: 10.3201/eid1412.080582

References

1. Longbottom D, Coulter LJ. Animal chlamydioses and zoonotic implications. *J Comp Pathol.* 2003;128:217–44. DOI: 10.1053/jcpa.2002.0629
2. Greub G, Raoult D. *Parachlamydiaceae*: potential emerging pathogens. *Emerg Infect Dis.* 2002;8:625–30.
3. Borel N, Ruhl S, Casson N, Kaiser C, Pospischil A, Greub G. *Parachlamydia* spp. and related *Chlamydia*-like organisms and bovine abortion. *Emerg Infect Dis.* 2007;13:1904–7.
4. Chanton-Greutmann H, Thoma R, Corboz L, Borel N, Pospischil A. Abortion in small ruminants in Switzerland: investigations during two lambing seasons (1996–1998) with special regard to chlamydial abortions [in German]. *Schweiz Arch Tierheilkd.* 2002;144:483–92. DOI: 10.1024/0036-7281.144.9.483
5. Borel N, Thoma R, Spaeni P, Weilenmann R, Teankum K, Brugnera E, et al. *Chlamydia*-related abortions in cattle from Graubünden, Switzerland. *Vet Pathol.* 2006;43:702–8. DOI: 10.1354/vp.43-5-702
6. Everett KD, Bush RM, Andersen AA. Emended description of the order *Chlamydiales*, proposal of *Parachlamydiaceae* fam. nov. and *Simkaniaceae* fam. nov., each containing one monotypic genus, revised taxonomy of the family *Chlamydiaceae*, including a new genus and five new species, and standards for the identification of organisms. *Int J Syst Bacteriol.* 1999;49:415–40.
7. Borel N, Kempf E, Hotzel H, Schubert E, Torgerson P, Slickers P, et al. Direct identification of *chlamydiae* from clinical samples using a DNA microarray—a validation study. *Mol Cell Probes.* 2008;22:55–64. DOI: 10.1016/j.mcp.2007.06.003
8. Casson N, Posfay-Barbe KM, Gervais A, Greub G. New diagnostic real-time PCR for specific detection of *Parachlamydia acanthamoebae* DNA in clinical samples. *J Clin Microbiol.* 2008;46:1491–3. DOI: 10.1128/JCM.02302-07
9. Greub G, Berger P, Papazian L, Raoult D. *Parachlamydiaceae* as rare agents of pneumonia. *Emerg Infect Dis.* 2003;9:755–6.
10. Casson N, Entenza JM, Greub G. Serological cross-reactivity between different *Chlamydia*-like organisms. *J Clin Microbiol.* 2007;45:234–6. DOI: 10.1128/JCM.01867-06

Address for correspondence: Nicole Borel, Institute of Veterinary Pathology, Vetsuisse Faculty, University of Zurich, 8057 Zurich, Switzerland; email: n.borel@access.uzh.ch

Candidate New Species of *Kobuvirus* in Porcine Hosts

To the Editor: Picornaviruses (family *Picornaviridae*) are small, nonenveloped viruses with single-stranded, positive-sense genomic RNA, currently divided into 8 genera: *Enterovirus*, *Aphthovirus*, *Cardiovirus*, *Hepatovirus*, *Parechovirus*, *Erbovirus*, *Teschovirus*, and *Kobuvirus* (1). To date, the genus *Kobuvirus* consists of 2 species, *Aichi virus* and *Bovine kobuvirus*, each possessing 1 serotype. *Aichi virus* (strain A846/88) was first isolated from a stool sample obtained from a person with acute gastroenteritis in 1991 (2). Bovine kobuvirus (strain U-1) was detected in bovine