

**Jyh-Hsiung Huang,
Cheng-Fen Yang, Chien-Ling Su,
Shu-Fen Chang, Chia-Hsin Cheng,
Sheng-Kai Yu, Chien-Chou Lin,
and Pei-Yun Shu**

Author affiliation: Centers for Disease Control, Taipei, Taiwan, Republic of China

DOI: 10.3201/eid1511.090398

References

1. Powers AM, Brault AC, Tesh RB, Weaver SC. Re-emergence of chikungunya and o'nyong-nyong viruses: evidence for distinct geographical lineages and distant evolutionary relationships. *J Gen Virol*. 2000;81:471-9.
2. Powers AM, Logue CH. Changing patterns of chikungunya virus: re-emergence of a zoonotic arbovirus. *J Gen Virol*. 2007;88:2363-77. DOI: 10.1099/vir.0.82858-0
3. Shu PY, Yang CF, Su CL, Chen CY, Chang SF, Tsai KH, et al. Two imported chikungunya cases, Taiwan. *Emerg Infect Dis*. 2008;14:1326-7.
4. Peyrefitte CN, Rousset D, Pastorino BAM, Pouillot R, Bessaud M, Tock F, et al. Chikungunya virus, Cameroon, 2006. *Emerg Infect Dis*. 2007;13:768-71.
5. Yergolkar PN, Tandale BV, Arankalle VA, Sathe PS, Sudeep AB, Gandhe SS, et al. Chikungunya outbreaks caused by African genotype, India. *Emerg Infect Dis*. 2006;12:1580-3.
6. Bonilauri P, Bellini R, Calzolari M, Angelini R, Venturi L, Fallacara F, et al. Chikungunya virus in *Aedes albopictus*, Italy. *Emerg Infect Dis*. 2008;14:852-4. DOI: 10.3201/eid1405.071144
7. Pagès F, Peyrefitte CN, Mve MT, Jarjaval F, Brisse S, Itean I, et al. *Aedes albopictus* mosquito: the main vector of the 2007 chikungunya outbreak in Gabon. *PLoS One*. 2009;4:e4691. DOI: 10.1371/journal.pone.0004691
8. Santhosh SR, Dash PK, Parida MM, Khan M, Tiwari M, Lakshmana Rao PV. Comparative full genome analysis revealed E1: A226V shift in 2007 Indian chikungunya virus isolates. *Virus Res*. 2008;135:36-41. DOI: 10.1016/j.virusres.2008.02.004
9. de Lamballerie X, Leroy E, Charrel RN, Tsetsarkin K, Higgs S, Gould EA. Chikungunya virus adapts to tiger mosquito via evolutionary convergence: a sign of things to come? *Virology*. 2008;5:33. DOI: 10.1186/1743-422X-5-33
10. Schuffenecker I, Itean I, Michault A, Murri S, Frangeul L, Vaney MC, et al. Genome microevolution of chikungunya viruses causing the Indian Ocean outbreak. *PLoS Med*. 2006;3:e263. DOI: 10.1371/journal.pmed.0030263

Address for correspondence: Pei-Yun Shu, Research and Diagnostic Center, Centers for Disease Control, Department of Health, 161, Kun-Yang St, Taipei, Taiwan, Republic of China; email: pyshu@cdc.gov.tw

Cutaneous Larva Migrans Acquired in Brittany, France

To the Editor: Hookworm-related cutaneous larva migrans is a parasitic dermatosis caused by the penetration of larvae, mostly of a dog or cat hookworm, into the epidermis of humans (1,2). This eruption is most commonly found in tropical and subtropical areas but was recently reported from western Europe, including Germany (3,4), England (5,6), Scotland (7), and southern France (8). We report a patient from the Netherlands who acquired hookworm-related cutaneous larva migrans while on a holiday in Brittany, France.

A previously healthy 40-year-old man from the Netherlands traveled to Brittany, France, to visit from September 1 to September 15, 2008. He and his partner slept in tents, sometimes camping rough (not on designated camping sites or on private property), and they stayed in low-budget hotels. They spent a lot of time on several beaches along the Atlantic Ocean on the southern shore of Brittany ($\approx 48^\circ\text{N}$). The weather during their stay was variable. The patient was frequently bitten by mosquitoes, especially on his feet. He had not traveled to the tropics before and did not own any pets.

After his return to the Netherlands, the area around 2 presumed mosquito bites at the lateral side of his right foot became red, swollen, and itchy. This area evolved into a

1-cm pustule that later turned into a bulla. On November 10, he visited his general practitioner, who made a diagnosis of cellulitis and started the patient on amoxicillin/clavulanic acid 625 mg, 3 \times /day for 10 days. During antimicrobial drug treatment, skin inflammation improved, but after 2 days the patient noticed that an itching red streak had developed, extending from the lesions on the lateral side of the right foot to the whole width of the sole of the foot. The tip of the streak proceeded along the sole of the foot at the rate of 2 cm/day. On the fifth day, he was referred to our Tropical Diseases outpatient clinic.

Physical examination showed 2 elevated, ulcerative lesions on the lateral side of the right foot, and from each originated an elevated serpiginous lesion (Figure, panels B and C). These were typical tortuous lesions 2 cm in width. One of the lesions ran across the whole sole of the right foot and was 14 cm in length (Figure, panels A and C). The medial end of the lesion was fervently erythematous. Based on clinical signs, we diagnosed the skin lesion as hookworm-related cutaneous larva migrans with secondary impetiginization. The patient was subsequently treated with a single oral dose of 12 mg ivermectin. The itch and the progression of the lesion halted instantly and the lesion disappeared during the following weeks. The larva was not extirpated and thus not further identified.

Hookworm-related cutaneous larva migrans is usually caused by *Ancylostoma brasiliense*, *A. caninum* or, rarely, *Uncinaria stenocephala*. These zoonotic hookworms need a high temperature and a moist environment to develop from an embryo to filariforme larva (1,2). Hookworm-related cutaneous larva migrans is typically a disorder of tropical and subtropical zones and it is rather common among tourists who visit tropical beaches. This was the first patient we had seen with this disease who became infected in west-

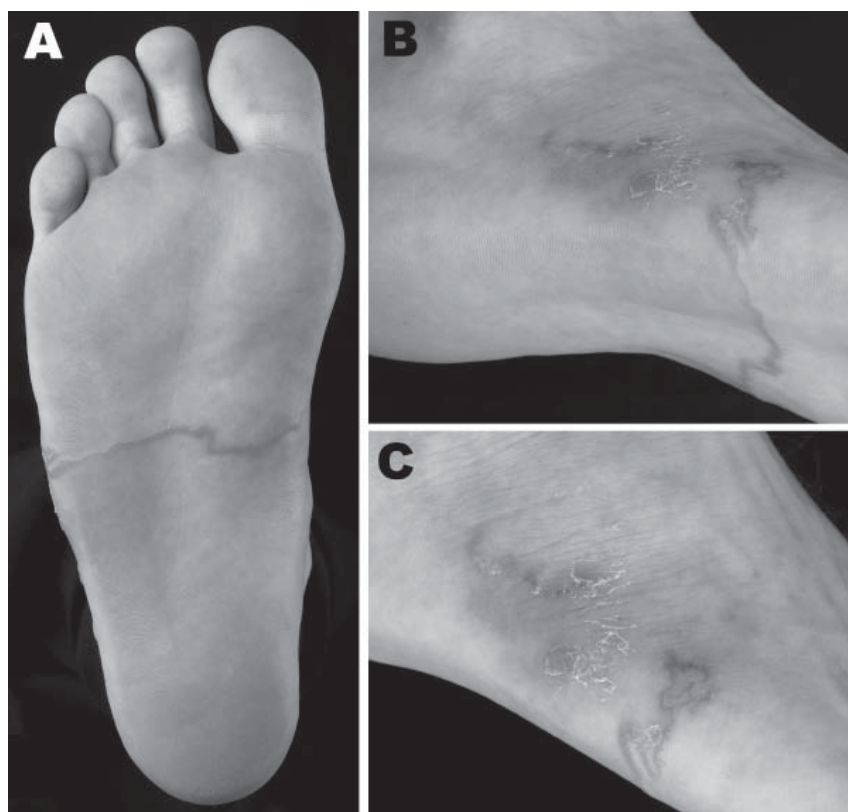


Figure. Right foot of a patient from Brittany, France, with a hookworm-related cutaneous larva migrans, showing an elevated serpiginous lesion on the sole of the foot (panels A, B) and ulcerative lesions at the origin of the lesions on the lateral side of the foot (panel C). A color version of this figure is available online (www.cdc.gov/EID/content/15/11/1856-F.htm).

ern Europe. Apart from an exceptionally hot day on August 30 (maximum 26°C), the weather was not particularly warm during the summer of 2008 in Brittany; during the first 2 weeks of September the average minimum and maximum temperatures were 11°C and 17°C, respectively. Rainfall was moderate and humidity was ≈86% (9). However, the overall warmer climate, including warmer winters, might have created the conditions for zoonotic hookworm infections in humans in western Europe (10).

Our patient may have been infected by *U. stenocephala*, a nematode of dogs that is common in temperate zones but rarely causes hookworm-related cutaneous larva migrans. An increase in ambient temperature might increase the incidence of these zoonot-

ic infections in northern regions. Only 4 cases of hookworm-related cutaneous larva migrans were previously reported in France, all from southern regions (8). A northern spread of hookworm-related cutaneous larva migrans could thus point to expansion of the global distribution of the more tropical hookworms or altered conditions that favor the emergence of infection by a zoonotic hookworm such as *U. stenocephala*. Either explanation calls for screening of infection in cats and dogs and preventing pet animals and possibly stray animals from accessing beaches. Clinicians should be aware of the possibility of hookworm-related cutaneous larva migrans in patients who have traveled to western Europe and, in particular, those who have stayed on the beaches.

Acknowledgments

We thank the Department of Medical Photography and Illustration of the Academic Medical Center, Amsterdam for providing the photographs.

**Nienke Tamminga,
Wouter F.W. Bierman,
and Peter J. de Vries**

Author affiliations: Academic Medical Center, Amsterdam, the Netherlands (N. Tamminga, W.F.W. Bierman, P.J. de Vries); University Medical Center Groningen, Groningen, the Netherlands (N. Tamminga); and VU University Medical Center, Amsterdam (W.F.W. Bierman)

DOI: 10.3201/eid1511.090261

References

1. Heukelbach J, Feldmeier H. Epidemiological and clinical characteristics of hookworm-related cutaneous larva migrans. *Lancet Infect Dis.* 2008;8:302–9. DOI: 10.1016/S1473-3099(08)70098-7
2. Hochedez P, Caumes E. Hookworm-related cutaneous larva migrans. *J Travel Med.* 2007;14:326–33. DOI: 10.1111/j.1708-8305.2007.00148.x
3. Kienast A, Bialek R, Hoeger PH. Cutaneous larva migrans in northern Germany. *Eur J Pediatr.* 2007;166:1183–5. DOI: 10.1007/s00431-006-0364-0
4. Klose C, Mravak S, Geb M, Bienzle U, Meyer CG. Autochthonous cutaneous larva migrans in Germany. *Trop Med Int Health.* 1996;1:503–4. DOI: 10.1046/j.1365-3156.1996.d01-86.x
5. Diba VC, Whitty CJ, Green T. Cutaneous larva migrans acquired in Britain. *Clin Exp Dermatol.* 2004;29:555–6. DOI: 10.1111/j.1365-2230.2004.01592.x
6. Roest MA, Ratnavel R. Cutaneous larva migrans contracted in England: a reminder. *Clin Exp Dermatol.* 2001;26:389–90. DOI: 10.1046/j.1365-2230.2001.00841.x
7. Beattie PE, Fleming CJ. Cutaneous larva migrans in the west coast of Scotland. *Clin Exp Dermatol.* 2002;27:248–9. DOI: 10.1046/j.1365-2230.2002.09852.x
8. Zimmermann R, Combemale P, Piens MA, Dupin M, Le Coz C. Cutaneous larva migrans, autochthonous in France. Apropos of a case [in French]. *Ann Dermatol Venereol.* 1995;122:711–4.
9. Weather in Brest, France, from September 1st to 15th, 2008 [cited 2009 Jan 25]. Available from <http://weeronline.nl/eurostdf.htm>

10. McMichael AJ, Woodruff RE, Hales S. Climate change and human health: present and future risks. *Lancet*. 2006;367:859–69. DOI: 10.1016/S0140-6736(06)68079-3

Address for correspondence: Wouter F.W. Bierman, Department of Internal Medicine, VU University Medical Center, De Boelelaan 1117, 1081 HV, Amsterdam, the Netherlands; e-mail: w.bierman@vumc.nl

European Perspective of 2-Person Rule for Biosafety Level 4 Laboratories

To the Editor: Recently, the directors of Biosafety Level 4 (BSL-4) laboratories in the United States published their views of the requirement of having ≥ 2 persons present at all times while biological work is undertaken in a BSL-4 laboratory (1). They concluded that safety and security would be better assured in some situations by video monitoring systems rather than by the presence of a fellow scientist. As members of the European Network of Biosafety Level-4 laboratories (Euronet-P4) who have developed guidelines in this area (2–4), we discussed the article during a recent network meeting. Biosafety and biosecurity are the major concerns for all involved in BSL-4 activities, and we support the authors' initiative and broadly agree with their position. The consensus among European BSL-4 experts is that, in the interest of safety, standard practice should be for all laboratories to perform a risk assessment before any activity is undertaken. This preliminary assessment is the best way to determine procedures to be used, including whether 2 persons should work together as part of

laboratory procedure. A 2-person rule is inappropriate simply because the best approach is not to have inflexible rules that are not objectively assessed according to laboratory-specific circumstances.

Surveillance video monitoring and data storing have their place in protecting laboratory facilities from unauthorized access and theft of materials, but their effectiveness for ensuring proper handling of pathogens is quite limited. Finally, we agree with the authors that both biosafety and biosecurity must be founded on careful selection and monitoring of staff, without which even the most sophisticated of control systems would fail.

Giuseppe Ippolito, Carla Nisii, Antonino Di Caro, David Brown, Robin Gopal, Roger Hewson, Graham Lloyd, Stephan Gunther, Markus Eickmann, Ali Mirazimi, Tuija Koivula, Marie-Claude Georges Courbot, Hervé Raoul, and Maria R. Capobianchi

Author affiliations: National Institute for Infectious Diseases, Rome, Italy (G. Ippolito, C. Nisii, A. Di Caro, M.R. Capobianchi); Health Protection Agency, London, UK (D. Brown, R. Gopal); Health Protection Agency, Salisbury, UK (R. Hewson, G. Lloyd); Bernhard Nocht Institute for Tropical Medicine, Hamburg, Germany (S. Gunther); Institute of Virology, Marburg, Germany (M. Eickmann); Swedish Institute for Infectious Disease Control, Solna, Sweden (A. Mirazimi, T. Koivula); and French National Institute for Health and Medical Research, Lyon, France (M.-C. Georges Courbot, H. Raoul)

DOI: 10.3201/eid1511.091134

References

1. Le Duc JW, Anderson K, Bloom ME, Carrion R Jr, Feldmann H, Fitch JP, et al. Potential impact of a 2-person security rule on Biosafety Level 4 laboratory workers. *Emerg Infect Dis* [cited 2009 Jul 28]. Available from <http://www.cdc.gov/EID/content/15/7/e1.htm> DOI: 10.3201/eid1507.081523
2. The European Network of P4 Laboratories 2005–2007 [Euronet–P4]. Brussels: European Commission; 2008 [cited 2009 Jul 28]. Available from http://ec.europa.eu/health/ph_projects/2003/action2/action2_2003_19_en.htm and www.euronetp4.eu
3. Ippolito G, Nisii C, Capobianchi MR. Networking for infectious-disease emergencies in Europe. *Nat Rev Microbiol*. 2008;6:564. DOI: 10.1038/nrmicro1896-c1
4. Nisii C, Castilletti C, Di Caro A, Capobianchi MR, Brown D, Lloyd G, et al. The European Network of P4 Laboratories: enhancing European preparedness for new health threats. *Clin Microbiol Infect*. 2009 May 28 [Epub head of print].

Address for correspondence: Giuseppe Ippolito, National Institute for Infectious Diseases, "L. Spallanzani," 292 Via Portuense, I-00149 Rome, Italy; email: ippolito@inmi.it

Multidrug-Resistant *Mycobacterium tuberculosis* Strain from Equatorial Guinea Detected in Spain

To the Editor: Eleven years of molecular epidemiologic data allowed the Spanish Multidrug-resistant Tuberculosis (MDR TB) Surveillance Network to identify a specific MDR *Mycobacterium tuberculosis* strain that had been imported into Spain from Equatorial Guinea (1). Our study brings to light the potential dissemination of this strain (named MDR-TBEG) in Equatorial Guinea, a country where little is known about the extent and features of TB or MDR TB. It also highlights that MDR strains can spread across continents, and thus MDR TB's emergence in any country becomes a global problem.

Ten MDR *M. tuberculosis* isolates obtained from 10 patients from Equatorial