Differentiation of Prions from L-type BSE versus Sporadic Creutzfeldt-Jakob Disease

Simon Nicot, Anna Bencsik, Eric Morignat, Nadine Mestre-Francés, Armand Perret-Liaudet, and Thierry Baron

We compared transmission characteristics for prions from L-type bovine spongiform encephalopathy and MM2-cortical sporadic Creutzfeldt-Jakob disease in the Syrian golden hamster and an ovine prion protein–transgenic mouse line and isolated distinct prion strains. Our findings suggest the absence of a causal relationship between these diseases, but further investigation is warranted.

Among transmissible spongiform encephalopathies (TSEs), the L-type bovine spongiform encephalopathy (L-BSE) in cattle requires particular attention for public health. L-BSE is transmitted more efficiently than is classical BSE among primates (*1*–*3*) as well as among transgenic mice that express human prion protein (PrP) (*4*,*5*). We recently reported that L-BSE was readily transmissible by experimental oral inoculation in a nonhuman primate species, the grey mouse lemur (*Microcebus murinus*) (*3*). These findings raise the possibility that some human Creutzfeldt-Jakob disease (CJD) cases might result from exposure to the L-BSE agent; previous studies highlighted similarities between L-BSE and some human subtypes (type 2) of sporadic CJD (sCJD) (*1*,*6*).

To examine the possible relationship between L-BSE and sCJD, we evaluated a strain-typing strategy that relies on comparative transmission characteristics in the Syrian golden hamster and in a transgenic mouse line (TgOvPrP4) expressing ovine PrP (ARQ allele). Both of these species are susceptible to L-BSE prions from cattle (*7*,*8*). The transmission of L-BSE, including after a first passage in *Microcebus murinus* lemurs (*3*), was compared with that for the MM2-cortical subtype of sCJD (*9*); this subtype was chosen on the basis of a study that indicated higher levels of molecular similarities of L-BSE with this sCJD subtype than with the MV2 subtype (*1*).

Author affiliations: Agence Nationale de Sécurité Sanitaire (Anses), Lyon, France (S. Nicot, A. Bencsik, E. Morignat, T. Baron); INSERM U710, Montpellier, France; Université Montpellier 2, Montpellier; École Pratique des Hautes Études, Paris, France (N. Mestre-Francés); and Hôpitaux Civils de Lyon, Université Lyon 1, INSERM U1028, and Centre National de la Recherche Scientifique, Lyon (A. Perret-Liaudet)

DOI: http://dx.doi.org/10.3201/eid1812.120342

The Study

The TSE brain inocula used in this study, conducted during November 2010–December 2011, were derived from 2 natural L-BSE isolates from France (02-2528 and 08-0074); a lemur injected intracerebrally (i.c.) with the 02-2528 L-BSE cattle isolate (*3*); and a human patient with MM2-cortical sCJD. Consent was obtained for using tissues from the human patient in research, including genetic analyses. Animal experiments were performed in the biohazard prevention area (A3) of the Anses-Lyon animal facilities, in accordance with the guidelines of the French Ethical Committee (decree 87-848) and European Community Directive 86/609/EEC.

Six-week-old TgOvPrP4 mice and 4-week-old Syrian golden hamsters were injected i.c. with 20 and 30 µL, respectively, of 10% (wt/vol) brain homogenates in 5% sterile glucose. Serial passages were performed in TgOvPrP4 mice by i.c. inoculation of 1% (wt/vol) homogenates from mice positive for protease-resistant PrP (PrP^{res}). At the terminal stage of the disease, animals were euthanized, and their brains and spleens were collected for PrP^{res} analyses by Western blot and for histopathologic studies (*8*).

In hamsters, transmission of the MM2-cortical sCJD agent was inefficient. Clinical signs were absent up to 876 days postinoculation (dpi) (Table), and disease-associated PrP (PrP^{d}) in brain samples was not detected by paraffin-embedded tissue blot (PET-blot) (Figure 1, panel A), immunohistochemical (Figure 1, panel C), or Western blot (Figure 1, panels E, F) analyses. PrP^{res} was also undetectable in spleen tissues by Western blot (Table).

In contrast, the L-BSE agent passaged in a lemur was efficiently transmitted to hamsters, with a mean survival period of 529 ± 117 dpi, similar to that for L-BSE from cattle (622 ± 64 dpi) (Table). PET-blot analysis (Figure 1, panel B) showed widespread PrP^{res} distribution in the brain; immunohistochemical analysis (Figure 1, panel D) showed a granular type of PrP^{d} deposition that redefined the periphery of most of the blood vessels. Western blot analysis (Figure 1, panels E, F) showed PrP^{res} in the brains of hamsters inoculated with L-BSE from cattle and lemur and in 1/4 spleens of hamsters injected with L-BSE passaged in lemur (Table). Brain PrP^{res} was characterized by low apparent molecular mass (≈19 kDa for the unglycosylated band) associated with a lack of reactivity toward the N terminal 12B2 antibody, in contrast to that for the control animal with scrapie (Figure 1, panels E, F).

Table. Comparison of transmission of sCJD and L-BSE in hamsters and mice

Hosts and inoculum	Passage	Mean survival time, dpi ± SD	No. brain PrP^d positive/no. tested	No. spleen PrP^{res} positive/no. tested
Syrian golden hamsters				
sCJD MM2-cortical	1	833 ± 33	0/4	0/4
L-BSE lemur	1	529 ± 177	5/5	1/4
L-BSE cattle (02-2528)	1	622 ± 64†	4/5†	0/5
TgOvPrP4 mice				
sCJD MM2-cortical	1	639 ± 49	3/4	0/4
L-BSE lemur	1	509 ± 97	7/7	7/7
L-BSE cattle (02-2528)	1	627 ± 74‡	9/10‡	0/5§
L-BSE cattle (08-0074)	1	497 ± 49	6/8	0/9
sCJD MM2-cortical	2	111 ± 25	12/12	12/12
L-BSE lemur	2	194 ± 7	12/12	12/12
L-BSE cattle (02-2528)	2	202 ± 26‡	9/9‡	3/5
L-BSE cattle (08-0074)	2	186 ± 37	12/12	9/11

*Isolate identification numbers are shown in parentheses. sCJD, sporadic Creutzfeldt-Jakob disease; L-BSE, L-type bovine spongiform encephalopathy; TgOvPrP4, ovine prion protein–transgenic; dpi, days postinoculation; PrP^d, disease-associated prion protein; PrP^{res}, protease-resistant prion protein.
†Data from (*7*).
‡Data from (*8*).
§Data from (*10*).

In TgOvPrP4 mice, all TSEs were efficiently transmitted, as confirmed by PrP^d accumulation in the mouse brains (Table). After serial passages in additional TgOvPrP4 mice, the survival periods in each experiment became considerably shorter (Table; online Technical Appendix Figure 1, wwwnc.cdc.gov/EID/pdfs/12-0342-Techapp.pdf). No statistically significant differences in results were identified between the L-BSE sources ($p>0.6$). Mean survival period decreased to 111 ± 25 dpi at second passage in mice inoculated with the agent of MM2-cortical subtype sCJD, which differed significantly from that of mice inoculated with L-BSE ($p<0.0001$). A third passage of both cattle L-BSE and human sCJD did not reduce the survival periods in TgOvPrP4 mice (data not shown).

Western blot analyses of PrP^{res} from mouse brains showed partially similar features for MM2-cortical sCJD and L-BSE, including low molecular mass (≈19 kDa for the unglycosylated band) (Figure 2, panel A) and similar conformational stability of PrP^d after treatment with guanidinium hydrochloride (online Technical Appendix Figure 2). However, the proportions of diglycosylated, monoglycosylated, and unglycosylated bands of brain PrP^{res} differed between sCJD and L-BSE (Figure 2, panel C); higher proportions of diglycosylated PrP^{res} were found in sCJD-infected mice (mean 67% of the total signal) compared with L-BSE–infected mice (≈18% lower; $p<0.0001$). PrP^{res} was readily identified in the spleens of TgOvPrP4 mice at the second passage for sCJD and L-BSE

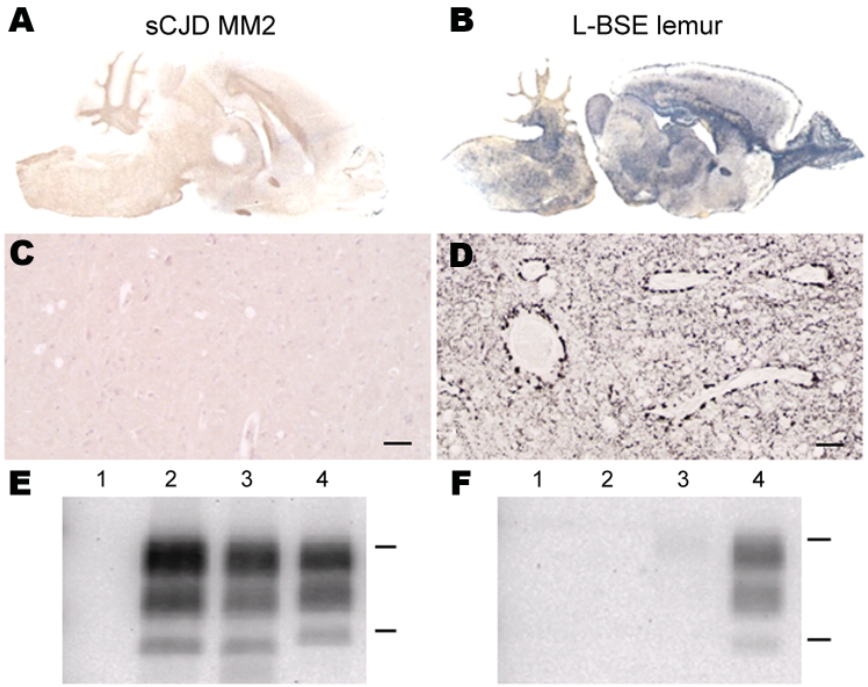

Figure 1. Susceptibility of Syrian golden hamsters to MM2-cortical subtype sporadic Creutzfeldt-Jakob disease (sCJD) and L-type bovine spongiform encephalopathy (L-BSE) prions. Disease-associated prion protein (PrP^d) was analyzed in brains of hamsters injected with human MM2-cortical sCJD and L-BSE from a mouse lemur by paraffin-embedded tissue blot (A, B), immunohistochemistry (C, D), or Western blot (E, F). Monoclonal antibodies against prion protein were SAF84 (A–D), SHa31 (E), and 12B2 (F). C, D) Scale bars = 200 µm. E, F) Controls were hamsters infected with L-BSE from cattle (isolate 02-2528) and with scrapie (experimental isolate SSBP/1 after a first passage in ovine prion protein–transgenic mice). Lane 1, sCJD MM2; lane 2, L-BSE from lemur; lane 3, L-BSE from cattle control; lane 4, scrapie control. Bars to the right indicate the 29.0- and 20.1-kDa marker positions.

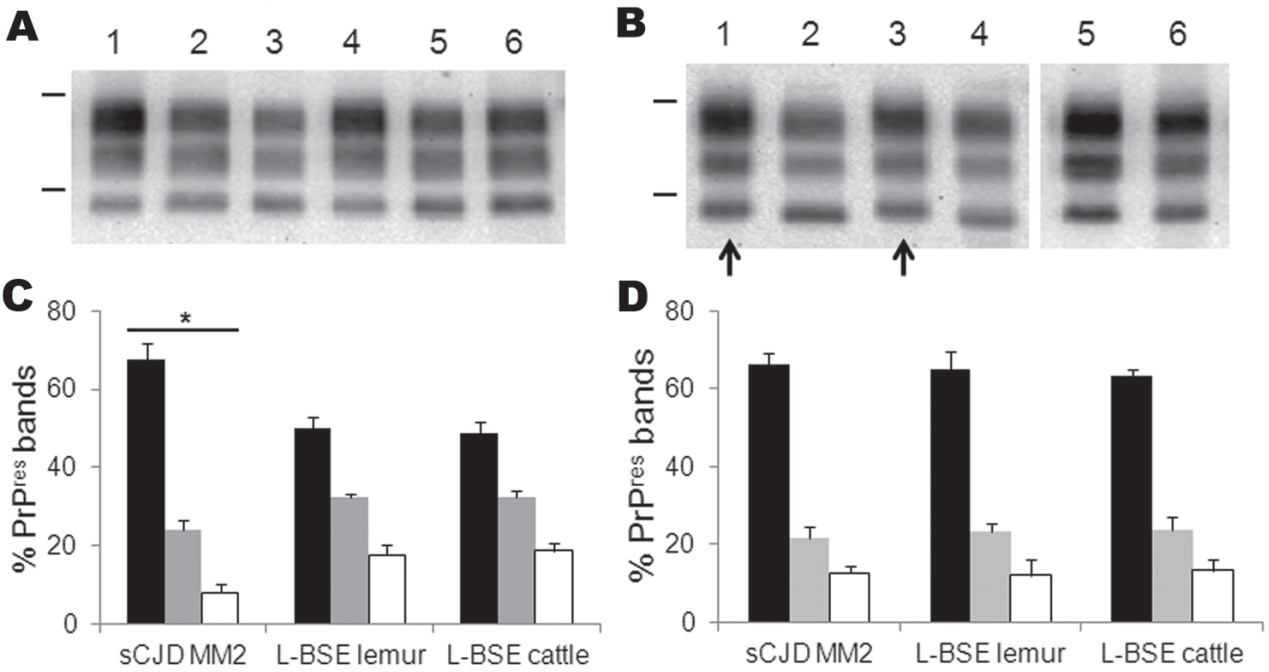

Figure 2. Western blot molecular typing of protease-resistant prion protein (PrP^{res}) in brain and spleen tissues of ovine prion protein–transgenic (TgOvPrP4) mice at second passage. PrP^{res} from mice infected with MM2-cortical subtype sporadic Creutzfeldt-Jakob disease (sCJD), L-type bovine spongiform encephalopathy (L-BSE) from lemur, and L-BSE from cattle (02-2528) were compared in brain (A) and spleen (B) tissues (monoclonal antibody SHa31). Bars to the left of Western blots indicate the 29.0- and 20.1-kDa marker positions. A) Lanes 1, 4, sCJD MM2; lanes 2, 5, L-BSE from lemur; lanes 3, 6, L-BSE from cattle control; B) lanes 1, 3, sCJD MM2; lanes 2, 4, 6, L-BSE from lemur; lane 5, L-BSE from cattle control. C, D) Proportions of PrP^{res} glycoforms in brain (C) and spleen (D) tissues. Error bars indicate SD. *Indicates $p<0.0001$ when comparing PrP^{res} proportions from mice infected with MM2-cortical sCJD with those infected with L-BSE.

from cattle and at the first passage for L-BSE from lemur (Table). No significant differences in the proportions of PrP^{res} glycoforms for sCJD-infected versus L-BSE–infected mice were observed in the spleens (Figure 2, panel D), but PrP^{res} was ≈0.5 kD higher in mice injected with sCJD (Figure 2, panel B, arrows).

Histopathologic analysis showed severe vacuolar lesions in TgOvPrP4 mice infected at second passage with sCJD and lemur-passaged L-BSE (online Technical Appendix Figure 3). However, in sCJD-infected mice, vacuolar lesions were mostly observed in the anterior parts of the brain (except the parietal cortex), whereas in mice infected with lemur-passaged L-BSE, the lesions were more widely distributed, involving the colliculi and the hypothalamus. In mice infected with sCJD and lemur-passaged L-BSE, PET-blot analyses showed that most of the PrP^{res} occurred in the frontal parts of the brain, but the intensity and appearance of PrP^{res} in the cortex, thalamus, and hippocampus were distinctly different. Immunohistochemical analyses of the hippocampus showed PrP^{d} deposition in the dentate gyrus in sCJD-infected mice, in contrast to a lack of deposition in lemur-passaged L-BSE–infected mice.

Conclusions

We report the isolation of 2 prion strains derived from L-BSE and MM2-cortical sCJD after transmission in Syrian hamsters and ovine PrP–transgenic mice. In hamsters, we did not transmit any disease with sCJD, but the transmission of L-BSE from lemur was efficient, as previously reported for L-BSE from cattle (*7*,*11*). This result suggests that L-BSE did not undergo major modifications after this cross-species transmission and could indicate a clear biologic difference between MM2-cortical sCJD and L-BSE. We also demonstrated the efficient transmission of both L-BSE and MM2-cortical sCJD in TgOvPrP4 mice, which enabled us to compare these diseases in a single model. Unexpectedly, during serial passages, we observed that the agent of MM2-cortical sCJD causes a much more rapidly fatal disease. Despite similar molecular features in sCJD and L-BSE, including the PrP^{res} electrophoretic mobility and the conformational stability of PrP^{d}, sCJD and L-BSE differed in PrP^{res} glycosylation for the mouse brains and gel migrations for the mouse spleens. Mice infected with MM2-cortical sCJD versus those infected with L-BSE also showed distinct lesion profiles and PrP^{d} distribution,

which confirms clear biologic differences between these diseases.

Although only 1 case of sCJD of a unique molecular subtype was examined in our study, our observations do not support the hypothesis of a causal relationship between L-BSE and this human sCJD subtype. Our study thus encourages further investigations using the proposed bioassay approach for a more complete evaluation of possible relationships between L-BSE and human prion diseases.

Acknowledgments

We thank the staff of the Plateforme d'Expérimentation Animale of Anses-Lyon for excellent animal care; Mikaël Leboidre and Jean-Michel Bridon for histotechnical assistance; Dominique Canal and Claire Aufauvre for biochemical assistance; and Françoise Didier and Nathalie Streichenberger for characterization of the human sporadic CJD case.

S.N. was supported by grants from the Agence Nationale de Sécurité Sanitaire and the Fondation pour la Recherche Médicale.

Mr Nicot is a PhD student at the Agence Nationale de Sécurité Sanitaire in Lyon. His primary research interests include characterization of the infectious agents and prion protein during intra- and interspecies transmission of animal and human prion diseases.

References

1. Comoy EE, Casalone C, Lescoutra-Etchegaray N, Zanusso G, Freire S, Marce D, et al. Atypical BSE (BASE) transmitted from asymptomatic aging cattle to a primate. PLoS ONE. 2008;3:e3017. http://dx.doi.org/10.1371/journal.pone.0003017
2. Ono F, Tase N, Kurosawa A, Hiyaoka A, Ohyama A, Tezuka Y, et al. Atypical L-type bovine spongiform encephalopathy (L-BSE) transmission to cynomolgus macaques, a non-human primate. Jpn J Infect Dis. 2011;64:81–4.
3. Mestre-Francés N, Nicot S, Rouland S, Biacabe AG, Quadrio I, Perret-Liaudet A, et al. Oral transmission of L-type bovine spongiform encephalopathy in primate model. Emerg Infect Dis. 2012;18:142–5. http://dx.doi.org/10.3201/eid1801.111092
4. Kong Q, Zheng M, Casalone C, Qing L, Huang S, Chakraborty B, et al. Evaluation of the human transmission risk of an atypical bovine spongiform encephalopathy prion strain. J Virol. 2008;82:3697–701. http://dx.doi.org/10.1128/JVI.02561-07
5. Béringue V, Herzog L, Reine F, Le Dur A, Casalone C, Vilotte JL, et al. Transmission of atypical bovine prions to mice transgenic for human prion protein. Emerg Infect Dis. 2008;14:1898–901. http://dx.doi.org/10.3201/eid1412.080941
6. Casalone C, Zanusso G, Acutis P, Ferrari S, Capucci L, Tagliavini F, et al. Identification of a second bovine amyloidotic spongiform encephalopathy: molecular similarities with sporadic Creutzfeldt-Jakob disease. Proc Natl Acad Sci U S A. 2004;101:3065–70. http://dx.doi.org/10.1073/pnas.0305777101
7. Nicot S, Baron T. Strain-specific barriers against bovine prions in hamsters. J Virol. 2011;85:1906–8. http://dx.doi.org/10.1128/JVI.01872-10
8. Baron T, Bencsik A, Biacabe AG, Morignat E, Bessen RA. Phenotypic similarity of transmissible mink encephalopathy in cattle and L-type bovine spongiform encephalopathy in a mouse model. Emerg Infect Dis. 2007;13:1887–94. http://dx.doi.org/10.3201/eid13112.070635
9. Parchi P, Giese A, Capellari S, Brown P, Schulz-Schaeffer W, Windl O, et al. Classification of sporadic Creutzfeldt-Jakob disease based on molecular and phenotypic analysis of 300 subjects. Ann Neurol. 1999;46:224–33. http://dx.doi.org/10.1002/1531-8249(199908)46:2<224::AID-ANA12>3.0.CO;2-W
10. Baron T, Bencsik A, Morignat E. Prions of ruminants show distinct splenotropisms in an ovine transgenic mouse model. PLoS ONE. 2010;5:e10310.
11. Shu Y, Masujin K, Okada H, Iwamaru Y, Imamura M, Matsuura Y, et al. Characterization of Syrian hamster adapted prions derived from L-type and C-type bovine spongiform encephalopathies. Prion. 2011;5:103–8. http://dx.doi.org/10.4161/pri.5.2.15847

Address for correspondence: Thierry Baron, Anses-Lyon, 31 Avenue Tony Garnier, 69364 Lyon Cedex 07, France; email: thierry.baron@anses.fr

Use of trade names is for identification only and does not imply endorsement by the Public Health Service or by the US Department of Health and Human Services.

Scan this QR Code with your smartphone and enjoy listening to our podcasts about the latest emerging infectious diseases.

http://wwwnc.cdc.gov/eid/podcasts.htm

EID PODCAST

Article DOI: http://dx.doi.org/10.3201/eid1812.120342

Differentiation of Prions from L-type BSE Versus Sporadic Creutzfeldt-Jakob Disease

Technical Appendix

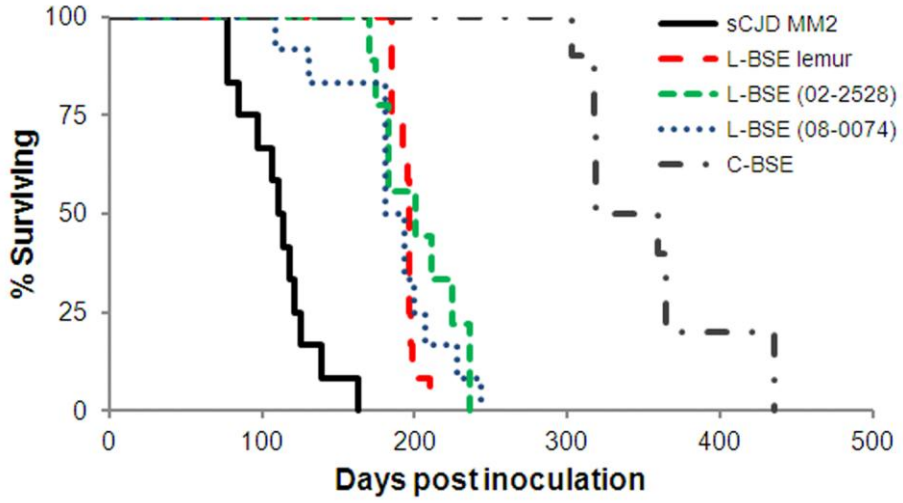

Technical Appendix Figure 1. Kaplan Meier survival curves for mice injected with MM2-cortical sporadic Creutzfeldt-Jakob disease (sCJD), L-type bovine spongiform encephalopathy (L-BSE) from lemur, L-BSE from cattle (02-2528 and 08-0074 isolates), and classical BSE (01-2281 isolate).

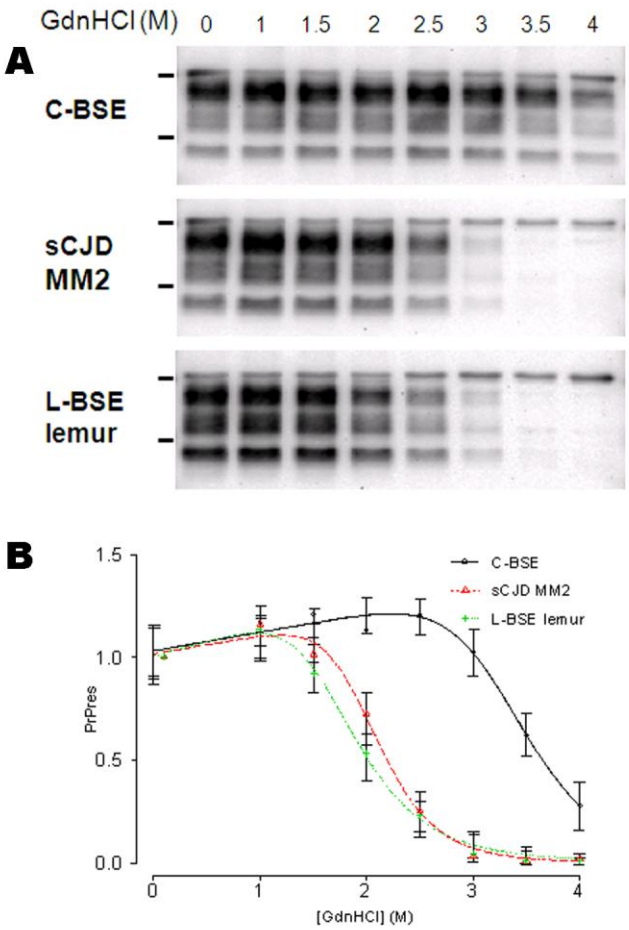

Technical Appendix Figure 2. Conformational stability assay of disease-associated prion protein (PrP^d) in brains of TgOvPrP4 mice at second passage. PrP^d was denatured with increasing concentrations (0 to 4 M) of guanidinium hydrochloride (GdnHCl) followed by digestion with proteinase K. Prion sources were classical bovine spongiform encephalopathy (C-BSE, 01-2281 isolate), MM2-cortical sporadic Creutzfeldt-Jakob disease (sCJD), and L-type BSE from lemur. GdnHCl denaturation curves were plotted as protease-resistant prion protein (PrP^{res}) Western blot signals (monoclonal antibody SHa31) (A) and fitted to a 5-parameter Brain-Cousens modified log-logistic model (B). The same tissue equivalents (0.4 mg) were loaded in each lane. Bars to the left of Western blots indicate the 29.0- and 20.1-kDa marker positions.

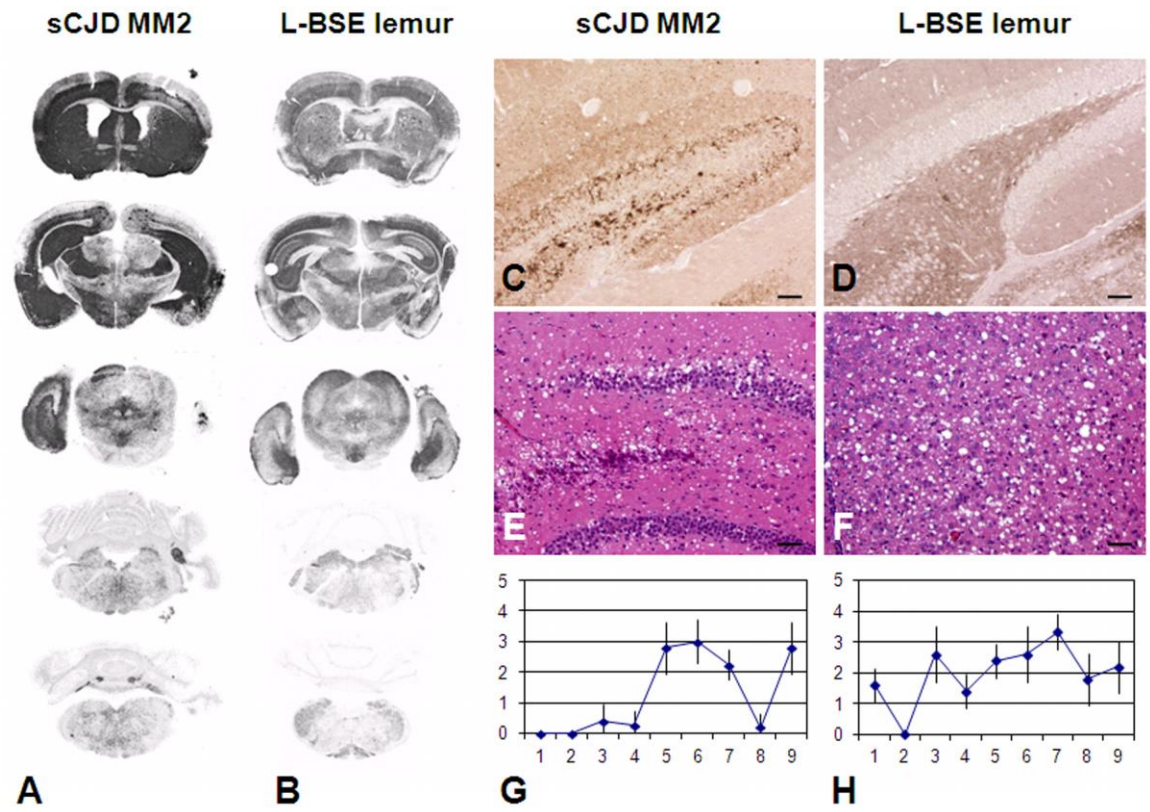

Technical Appendix Figure 3. Histopathological features of MM2-cortical sporadic Creutzfeldt-Jakob disease (sCJD) and L-type bovine spongiform encephalopathy (L-BSE) from lemur transmitted to ovine prion protein–transgenic mice at second passage. A, B) Paraffin-embedded tissue blot analysis (monoclonal antibody SAF84) of coronal brain sections. C, D) Immunohistochemical detection (monoclonal antibody SAF84) of disease-associated prion protein (PrP^d) in the hippocampus (dentate gyrus). Scale bars = 200 µm. E, F) Vacuolar lesions after hematoxylin-eosin staining in the hippocampus and thalamus, respectively. Scale bars = 200 µm.G, H) Lesion profiles in mice infected with sCJD MM2 (n = 5) and L-BSE from lemur (n = 6) respectively. 1. dorsal medulla nuclei, 2. cerebellar cortex, 3. superior colliculus, 4. hypothalamus, 5. central thalamus, 6. hippocampus, 7. septal nuclei, 8. cerebral cortex at the level of the thalamus (parietal cortex), 9. cerebral cortex at the level of the septal nuclei (frontal cortex).