References

1. Amarasinghe A, Kuritsk JN, Letson GW, Margolis HS. Dengue virus infection in Africa. Emerg Infect Dis. 2011;17:1349–54. https://dx.doi.org/10.3201/eid1708.101515
2. Lanciotti RS, Calisher CH, Gubler DJ, Chang GJ, Vorndam AV. Rapid detection and typing of dengue viruses from clinical samples by using reverse transcriptase-polymerase chain reaction. J Clin Microbiol. 1992;30:545–51.
3. Johnson BK, Ocheng D, Gichogo A, Okiro M, Libondo D, Kinyanjui P, et al. Epidemic dengue fever caused by dengue type 2 virus in Kenya: preliminary results of human virological and serological studies. East Afr Med J. 1982;59:781–4.
4. Mease LE, Coldren RL, Musila LA, Prosser T, Ogolla F, Ofula VO, et al. Seroprevalence and distribution of arboviral infections among rural Kenyan adults: a cross-sectional study. Virol J. 2011;8:371. http://dx.doi.org/10.1186/1743-422X-8-371
5. Sutherland LJ, Cash AA, Huang YJ, Sang RC, Malhotra I, Moormann AM, et al. Serologic evidence of arboviral infections among humans in Kenya. Am J Trop Med Hyg. 2011;85:158–61. http://dx.doi.org/10.4269/ajtmh.2011.10-0203
6. Vu DM, Banda T, Teng CY, Heimbaugh C, Muchiri EM, Mungai PL, et al. Dengue and West Nile virus transmission in children and adults in coastal Kenya. Am J Trop Med Hyg. 2017;96:141–3. http://dx.doi.org/10.4269/ajtmh.16-0562
7. Ellis EM, Neatherlin JC, Delorey M, Ochieng M, Mohamed AH, Mogeni DO, et al. A household serosurvey to estimate the magnitude of a dengue outbreak in Mombasa, Kenya, 2013. PLoS Negl Trop Dis. 2015;9:e0003733. http://dx.doi.org/10.1371/journal.pntd.0003733
8. Ngoi CN, Price MA, Fields B, Bonventure J, Ochieng C, Mwashigadi G, et al. Dengue and chikungunya virus infections among young febrile adults evaluated for acute HIV-1 infection in coastal Kenya. PLoS One. 2016;11:e0167508. http://dx.doi.org/10.1371/journal.pone.0167508
9. Murgue B, Roche C, Chungue E, Deparis X. Prospective study of the duration and magnitude of viraemia in children hospitalised during the 1996–1997 dengue-2 outbreak in French Polynesia. J Med Virol. 2000;60:432–8. http://dx.doi.org/10.1002/(SICI)1096-9071(200004)60:4<432::AID-JMV11>3.0.CO;2-7
10. de Oliveira Poersch C, Pavoni DP, Queiroz MH, de Borba L, Goldenberg S, dos Santos CN, et al. Dengue virus infections: comparison of methods for diagnosing the acute disease. J Clin Virol. 2005;32:272–7. http://dx.doi.org/10.1016/j.jcv.2004.08.008

Address for correspondence: David M. Vu, Stanford University School of Medicine, Pediatric Infectious Diseases, 300 Pasteur Dr, Rm G312, Stanford, CA 94305, USA; email: davidvu@stanford.edu

Paracoccidioidomycosis after Highway Construction, Rio de Janeiro, Brazil

Antonio C. Francesconi do Valle, Priscila Marques de Macedo, Rodrigo Almeida-Paes, Anselmo R. Romão, Marcia dos Santos Lazéra, Bodo Wanke[1]

Author affiliations: Evandro Chagas National Institute of Infectious Diseases, Rio de Janeiro, Brazil (A.C. Francesconi do Valle, P. Marques de Macedo, R. Almeida-Paes, M. dos Santos Lazéra, B. Wanke); Institute of Scientific and Technological Communication and Information in Health, Rio de Janeiro (A.R. Romão)

DOI: https://doi.org/10.3201/eid2311.170934

Transmission of *Paracoccidioides* spp. fungi to humans is usually related to manipulation of soil. Rural workers are the most affected group. We report an outbreak of paracoccidioidomycosis after deforestation and massive earth removal during construction of a highway in Rio de Janeiro, Brazil. Extensive environmental disturbances might be involved in fungal transmission.

Paracoccidioidomycosis is the major systemic mycosis in Latin America and the leading fungal cause of death in immunocompetent persons in Brazil (*1,2*). Paracoccidioidomycosis is a neglected disease whose prevalence and incidence rates are underestimated because of lack of mandatory reporting. Infection follows inhalation of *Paracoccidioides* spp. conidia in the soil (*3,4*) and can progress to disease, typically manifested in 1 of 2 clinical forms. The first form is chronic (adult type), which accounts for ≈80% of paracoccidioidomycosis cases, mostly in rural workers who show fungal endogenous reactivation in the lungs and other organs later in life. The second form is acute/subacute (juvenile type), which occurs primarily in young patients and is more severe because of progressive reticuloendothelial involvement, which results in high rates of complications, including death (*5*).

There have been reports of *Paracoccidioides* spp. infections after disturbances of soil that resulted in aerial dispersion of fungal propagules. Native indigenous populations in Latin America changed their ancient livelihood practices to cultivate coffee after deforestation of the Amazon rainforest, which resulted in paracoccidioidomycosis infections (*6,7*). In addition, climate changes related to the El Niño events, such as a high rainfall index followed by increased storage of water by soil and higher humidity, have been shown to occur before an increase of acute/subacute paracoccidioidomycosis cases (*8*).

We report an outbreak of paracoccidioidomycosis after deforestation and massive earth removal during construction of a highway in Rio de Janeiro, Brazil. The study protocol was approved by the Evandro Chagas National Institute of Infectious Diseases Research Ethics Committee (register CAAE 42590515.0.0000.5262).

The Evandro Chagas National Institute of Infectious Diseases in Rio de Janeiro is a reference center for paracoccidioidomycosis. This disease is endemic to the state of

[1]All authors contributed equally to this article.

Rio de Janeiro (*5*). During 1988–2015, the annual average number of acute/subacute cases of paracoccidioidomycosis at this institution was 2.3 cases/year for this state and 1.4 cases/year for Baixada Fluminense, a region composed of 12 municipalities in the metropolitan area of Rio de Janeiro (Figure). However, during December 2015–December 2016, a total of 8 cases were diagnosed at this center, all from Baixada Fluminense, a rate ≈5.7 times higher than that expected for this period. The most recent (2016) census in Brazil estimated that there were 968,680 persons <30 years of age living in the affected municipalities (*9*).

Case definition was based on clinical and laboratory criteria: reticuloendothelial involvement in young patients; laboratory test results confirming the presence of multibudding yeast-like *Paracoccidioides* cells by direct microscopy or histopathologic analysis; fungal isolation in culture; or a positive serologic result for paracoccidioidomycosis (*3*). Data for the 8 case-patients (4 males and 4 females) are provided (online Technical Appendix Table 1, https://wwwnc.cdc.gov/EID/article/23/11/17-0934-Techapp1.pdf). Mean age was 22 (range 10–28) years. Median time for diagnosis was 7 (range 4–16) months. Predominant clinical manifestations were cervical lymph node enlargement (100%), hepatomegaly (25%), and splenomegaly (25%). Serious complications occurred in 5 patients: adrenal insufficiency (3 patients), cholestasis (1 patient), esophageal fistula (1 patient), and acute upper airway obstruction (1 patient). A 19-year-old patient died because of complications of paracoccidioidomycosis.

The Raphael de Almeida Magalhães Highway, also known as Arco Metropolitano, is a new highway in the study region (Figure). During its construction (2008–2014), large areas were deforested and massive amounts of earth were removed, which resulted in discovery of 62 archeological sites through 2012 (*10*). Two thirds of this highway (97 km) was constructed during 2012–2014. The highway was complete for 1 year before the number of new cases of paracoccidioidomycosis increased. Residences of patients were 0.1 km–16.6 km from construction areas. The increase in the number of acute/subacute cases of paracoccidioidomycosis, with temporal and geographic relationships to this construction, suggests a possible new risk for outbreaks of paracoccidioidomycosis.

Other hypotheses for this cluster are clearing of forests, soil humidity, and the El Niño phenomenon (*3,8*). It is noteworthy that the highway crosses a native Atlantic forest area. Moreover, over several months in 2013, this region had high rainfall indexes (online Technical Appendix Table 2), which presumably contributed to retention of moisture in the soil. A previous study showed that soil humidity favors sporulation and dispersal of *Paracoccidioides* spp. (*3*). Also, a high-intensity El Niño phenomenon occurred during May 2015–March 2016.

The incidence of acute paracoccidioidomycosis in the affected area after highway construction (8.25 cases/1 million persons/y, 95% CI 4.18–16.3 cases/1 million persons/y) was higher than that before highway construction (1.29 cases/1 million persons/y, 95% CI 0.74–4.03 cases/1 million persons/y). More persons were probably exposed to *Paracoccidioides* conidia, but these persons did not show progression/development of disease, did not seek medical attention, and did not have

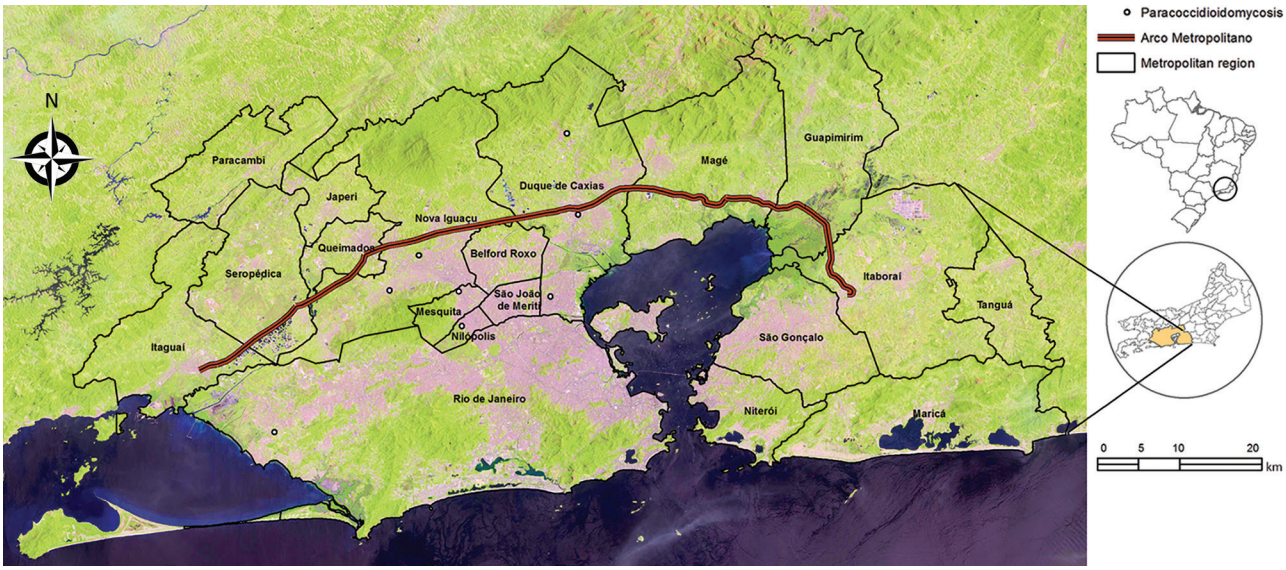

Figure. Metropolitan area of Rio de Janeiro, Brazil, showing the Raphael de Almeida Magalhães Highway, also known as the Arco Metropolitano, and georeferenced cases of paracoccidioidomycosis (open circles) during highway construction. Inset shows location of metropolitan area in Rio de Janeiro State and of Rio de Janeiro State (circle) in Brazil. Source: Landsat 8 Images (https://earthexplorer.usgs.gov/).

cases reported to health authorities. The chronic form of paracoccidioidomycosis will probably develop in some of these patients.

This study underscores the need for paracoccidioidomycosis surveillance, especially in the context of environmental alterations enhanced by climate change and affected by construction, deforestation, and other human interventions. Enhanced surveillance will more fully identify relative risks of different human enterprises and facilitate interventions for at-risk populations to reduce and prevent future outbreaks of paracoccidioidomycosis.

Acknowledgments

We thank Rosely Magalhães de Oliveira for providing epidemiologic assistance and Joshua Nosanchuk for providing editorial assistance.

A.C.F.dV was supported by Fundação de Amparo à Pesquisa do Estado do Rio de Janeiro (grant E-26/010.002203/2015).

Dr. Francesconi do Valle is a dermatologist in the Laboratory of Clinical Research in Infectious Dermatology, Evandro Chagas National Institute of Infectious Diseases, Rio de Janeiro, Brazil. His research interests are paracoccidioidomycosis and infectious diseases related to dermatology.

References

1. Coutinho ZF, Silva D, Lazera M, Petri V, Oliveira RM, Sabroza PC, et al. Paracoccidioidomycosis mortality in Brazil (1980–1995). Cad Saude Publica. 2002;18:1441–54. http://dx.doi.org/10.1590/S0102-311X2002000500037
2. Prado M, Silva MB, Laurenti R, Travassos LR, Taborda CP. Mortality due to systemic mycoses as a primary cause of death or in association with AIDS in Brazil: a review from 1996 to 2006. Mem Inst Oswaldo Cruz. 2009;104:513–21. http://dx.doi.org/10.1590/S0074-02762009000300019
3. Shikanai-Yasuda MA, Mendes RP, Colombo AL, Moretti ML, Queiroz-Telles F, Kono AS, et al. Brazilian guidelines for the clinical management of paracoccidioidomycosis. Rev Soc Bras Med Trop. 2017;July 20: [Epub ahead of print]. http://dx.doi.org/10.1590/0037-8682-0230-2017
4. Franco M, Bagagli E, Scapolio S, da Silva Lacaz C. A critical analysis of isolation of *Paracoccidioides brasiliensis* from soil. Med Mycol. 2000;38:185–91. http://dx.doi.org/10.1080/mmy.38.3.185.191
5. de Macedo PM, Almeida-Paes R, Freitas DF, Varon AG, Paixão AG, Romão AR, et al. Acute juvenile Paracoccidioidomycosis: a 9-year cohort study in the endemic area of Rio de Janeiro, Brazil. PLoS Negl Trop Dis. 2017;11:e0005500. http://dx.doi.org/10.1371/journal.pntd.0005500
6. do Valle AC, Coimbra Júnior CE, Llinares FI, Monteiro PC, Guimarães MR. Paracoccidioidomycosis among the Indian group Suruí of Rondonia, Amazonia, Brazil. A case report [in Portuguese]. Rev Inst Med Trop Sao Paulo. 1991;33:407–11. |http://dx.doi.org/10.1590/S0036-46651991000500012
7. Coimbra Júnior CE, Wanke B, Santos RV, do Valle AC, Costa RL, Zancopé-Oliveira RM. Paracoccidioidin and histoplasmin sensitivity in Tupí-Mondé Amerindian populations from Brazilian Amazonia. Ann Trop Med Parasitol. 1994;88:197–207. http://dx.doi.org/10.1080/00034983.1994.11812858
8. Barrozo LV, Benard G, Silva ME, Bagagli E, Marques SA, Mendes RP. First description of a cluster of acute/subacute paracoccidioidomycosis cases and its association with a climatic anomaly. PLoS Negl Trop Dis. 2010;4:e643. http://dx.doi.org/10.1371/journal.pntd.0000643
9. Brazilian Institute of Geography and Statistics. Cities, September 12, 2016 [in Portuguese] [cited 2017 June 29]. http://cidades.ibge.gov.br/xtras/perfil.php?codmun=330170
10. Press Rio de Janeiro News. Arco Metropolitan discovers new archaeological sites, Rio de Janeiro, Brazil, April 21, 2012 [in Portuguese] [cited 2017 May 29]. http://www.rj.gov.br/web/imprensa/exibeconteudo?article-id=869952

Address for correspondence: Priscila Marques de Macedo, Laboratório de Pesquisa Clínica em Dermatologia Infecciosa, Instituto Nacional de Infectologia Evandro Chagas, Fundação Oswaldo Cruz, Ave Brasil, 4365, Manguinhos, 21045-900, Rio de Janeiro RJ, Brazil; email: priscila.marques@ini.fiocruz.br

Mycobacterium shimoidei, a Rare Pulmonary Pathogen, Queensland, Australia

Timothy M. Baird, Robyn Carter, Geoffrey Eather, Rachel Thomson

Author affiliations: Princess Alexandra Hospital, Brisbane, Queensland, Australia (T.M. Baird, G. Eather); Metro South Clinical Tuberculosis Service, Brisbane (T.M. Baird, G. Eather, R. Thomson); Greenslopes Private Hospital, Brisbane (R. Thomson); University of Queensland, Brisbane (R. Thomson); Royal Brisbane and Womens Hospital, Brisbane (R. Carter)

DOI: https://doi.org/10.3201/eid2311.170999

Nontuberculous mycobacteria are human pathogens with increasing incidence and prevalence worldwide. *Mycobacterium shimoidei* is a rare cause of pulmonary disease, with only 15 cases previously reported. This series documents an additional 23 cases of *M. shimoidei* from Queensland, Australia, and highlights the pathogenicity and clinical role of this species.

Nontuberculous mycobacteria (NTM) are prominent human pathogens, with >150 species reported worldwide (*1*). *Mycobacterium shimoidei* is a slow-growing NTM that was first isolated in Japan in 1968, successfully gaining species status in 1975 (*2*). Since then, only 15 cases have been reported worldwide (*3–10*).

Article DOI: https://doi.org/10.3201/eid2311.170934

Paracoccidioidomycosis during Highway Construction, Rio de Janeiro, Brazil

Technical Appendix.

Technical Appendix Table 1. Characteristics for 8 patients with paracoccidioidomycosis during highway construction, Rio de Janeiro, Brazil*

Patient no.	Age, y/sex	Residence distance from highway, km	Municipality/year of highway construction	Symptom onset/exposure time, mo	Date of diagnosis	Diagnostic technique/sample	Complication /outcome
1	31/F	9.8	DC/2013	2015 Apr/≤27	2015 Dec	Culture/lymph node aspirate	None/clinical cure, still being treated
2	21/F	9.5	NI/2013	2014 Aug/≤19	2016 Jan	Histologic analysis/lymph node for biopsy	Adrenal insufficiency/ clinical cure, still being treated
3	28/F	9.3	MES/2013	2015 Jul/≤30	2016 Feb	Histologic analysis/lymph node and spleen sample for biopsy	Adrenal and respiratory insufficiency, tracheostomy/ clinical improvement, treatment suspended (pregnancy)
4	27/M	4.7	NI/2013	2015 Dec/≤35	2016 Mar	Culture/lymph node aspirate	None/clinical cure, still being treated
5	23/F	0.1	DC/2013	2015 Apr/≤27	2016 Apr	Direct examination/skin sample for biopsy	Adrenal insufficiency/ clinical cure, still being treated
6	23/M	12.3	DC/2013	2015 Dec/≤35	2016 Jun	Culture/lymph node aspirate	Cholestasis/ clinical cure, still being treated
7	19/M	14.2	NI/2013	2016 Jan/≤36	2016 Jun	Culture/lymph node aspirate and blood	Vasculitis, esophageal fistulae/died
8	10/M	16.6	SEP†/2013	2016 Jul/≤42	2016 Oct	Serologic analysis/blood	NA (lost to followup)

*Exposure to *Paracoccidioides* conidia might may have occurred during highway construction or subsequently as a consequence of massive earth removal from areas with native forests where the fungus was present. This anthropic activity might result in a recurrent or continuous aerial dispersion of fungal propagules during and after construction. The incubation time for acute/subacute paracoccidioidomycosis is unknown, but it might be long because there are no reports of this disease in children <2.5 years of age, in contrast with other pulmonary systemic mycoses, such as histoplasmosis, coccidioidomycosis, and blastomycosis. DC, Duque de Caxias; MES, Mesquita; NA, not available; NI, Nova Iguaçu; NIL, Nilópolis; SEP, Sepetiba.
†Although the residence of patient 8 was in Sepetiba, he had also lived in Duque de Caxias.

Technical Appendix Table 2. Observed and expected monthly rainfall indexes for Duque de Caxias, Rio de Janeiro, Brazil, 2012–2016*

	Month, mm												Total,
Year	Jan	Feb	Mar	Apr	May	Jun	Jul	Aug	Sep	Oct	Nov	Dec	mm
2012	NA	NA	NA	NA	141.2	143.6	45.8	33.6	140.4	95.8	241.2	129.2	>970.8
2013	590.2	91.2	471.2	127.0	158.2	66.2	188.6	39.8	87.8	102.6	260.0	318.2	2,501.0
2014	67.4	50.8	160.2	215.0	75.4	99.8	50.2	58.8	51.0	110.6	196.2	105.2	1,240.6
2015	141.8	0	229.4	70.2	**43.0**	**157.0**	**34.2**	**21.0**	**138.1**	**52.8**	**251.8**	**111.4**	1,250.7
2016	**528.6**	**344.8**	**199.0**	12.6	65.6	161.8	8.0	68.8	123.8	116.2	650.0	244.0	2,523.2
Expected	366.3	176.2	270.9	183.7	111.0	80.6	85.4	64.2	110.2	101.4	341.5	330.5	2,221.9

*Measurements in 2012 started in May. Bold indicates months when the El Niño phenomenon occurred. NA, not available.