Study participants were advised to wait to conceive in accordance with WHO specifications: 6 months for men, 2 months for women. Participants with pregnant partners were advised to use condoms during the entire pregnancy.

A lack of Zika cases in this cohort supports the risk calculations made before the Games and the WHO statement that there were no Zika cases associated with the Olympic Games (*8*). Although 48% of participants in our study recalled at least 1 mosquito bite during the stay, the overall absence of cases in the Rio de Janeiro population during July and August 2016 (*9*,*10*) is believed to be due to the vector-control efforts by Brazilian authorities before the Games and to the winter weather, leading to a low presence of adult mosquitoes and mosquito bites (*5*,*6*).

This work was supported by La Caixa Foundation and the Spanish Olympic Committee. The laboratory work was supported by RICET (Network Biomedical Research on Tropical Diseases), RD16CIII/003/003.

Dr. Rodriguez-Valero is an internal medicine specialist working in travel medicine since 2015. Her research interests include new technologies in travel medicine, outbreaks, and emerging infectious diseases.

References

1. World Health Organization. Zika virus and the Olympic and Paralympic Games Rio 2016 [cited 2016 Dec 26]. http://www.who.int/mediacentre/news/statements/2016/zika-olympics/en/
2. Attaran A, Caplan A, Gaffney C, Igel L. Open letter to Dr. Margaret Chan, Director-General, WHO (copied to the International Olympic Committee) [cited 2017 June 9]. http://www.gannett-cdn.com/usatoday/editorial/sports/olympics/zika-olympics-open-letter.pdf
3. Massad E, Tan S-H, Khan K, Wilder-Smith A. Estimated Zika virus importations to Europe by travellers from Brazil. Glob Health Action. 2016;9:31669. http://dx.doi.org/10.3402/gha.v9.31669
4. Zumla A, McCloskey B, Bin Saeed AA, Dar O, Al Otabi B, Perlmann S, et al. What is the experience from previous mass gathering events? Lessons for Zika virus and the Olympics 2016. Int J Infect Dis. 2016;47:1–4. http://dx.doi.org/10.1016/j.ijid.2016.06.010
5. Codeço C, Villela D, Gomes MF, Bastos L, Cruz O, Struchiner C, et al. Zika is not a reason for missing the Olympic Games in Rio de Janeiro: response to the open letter of Dr Attaran and colleagues to Dr Margaret Chan, Director-General, WHO, on the Zika threat to the Olympic and Paralympic Games. Mem Inst Oswaldo Cruz. 2016;111:414–5. http://dx.doi.org/10.1590/0074-02760160003
6. Grills A, Morrison S, Nelson B, Miniota J, Watts A, Cetron MS. Projected Zika virus importation and subsequent ongoing transmission after travel to the 2016 Olympic and Paralympic Games—country-specific assessment, July 2016. MMWR Morb Mortal Wkly Rep. 2016;65:711–5. http://dx.doi.org/10.15585/mmwr.mm6528e1
7. World Health Organization. Public health advice regarding the Olympics and Zika virus [cited 2016 Dec 26]. http://www.who.int/mediacentre/news/releases/2016/zika-health-advice-olympics/en/
8. World Health Organization. Fourth meeting of the Emergency Committee under the International Health Regulations (2005) regarding microcephaly, other neurological disorders and Zika virus [cited 2016 Dec 26]. http://www.who.int/mediacentre/news/statements/2016/zika-fourth-ec/en/
9. Ministerio da Saude. Secretaria de Vigilância em Saúde. Boletim Epidemiológico. Vol 47-nº33.; Brasilia 2016 [cited 2017 June 11]. http://portalarquivos.saude.gov.br/images/pdf/2016/setembro/16/2016-028---Dengue-SE32.pdf
10. Ministerio da Saude. Secretaria de Vigilância em Saúde. Boletim Epidemiológico. Vol 47-nº34.; Brasilia 2016 [cited 2017 June 11]. http://portalsaude.saude.gov.br/images/pdf/2016/outubro/18/2016-029-Dengue-publicacao-n-34.pdf

Address for correspondence: Natalia Rodriguez-Valero and Jose Muñoz, Department of Tropical Medicine and International Health, Hospital Clinic Barcelona. ISGlobal, Barcelona Centre for International Health Research (CRESIB), Hospital Clínic-Universitat de Barcelona C/Rosselló 132 2°2ª, 08036, Barcelona, Spain; email: natalia.rodriguez@isglobal.org and jose.munoz@isglobal.org

Candidatus Dirofilaria hongkongensis as Causative Agent of Human Ocular Filariosis after Travel to India

Stefan Winkler, Andreas Pollreisz, Michael Georgopoulos, Zsuzsanna Bagò-Horvath, Herbert Auer, Kelvin Kai-Wang To, Jürgen Krücken, Sven Poppert, Julia Walochnik

Author affiliations: Medical University of Vienna, Vienna, Austria (S. Winkler, A. Pollreisz, M. Georgopoulos, Z. Bagò-Horvath, H. Auer, J. Walochnik); University of Hong Kong, Pokfulam, Hong Kong, China (K.K-.W. To); Freie Universität Berlin, Germany (J. Krücken); Bernhard Nocht Institute for Tropical Medicine, Hamburg, Germany (S. Poppert); Regio Klinikum, Wedel, Germany (S. Poppert)

DOI: https://doi.org/10.3201/eid2308.170423

We report a human case of ocular *Dirofilaria* infection in a traveler returning to Austria from India. Analysis of mitochondrial sequences identified the worm as *Candidatus* Dirofilaria hongkongensis, a close relative of *Dirofilaria repens,* which was only recently described in Hong Kong and proposed as a new species.

Dirofilariosis, caused by *Dirofilaria repens* or *D. immitis* nematodes, is a zoonotic filarial infection transmitted through the bite of various mosquitoes. The most frequent

manifestations in humans are subcutaneously migrating worms and formation of nodules in various body parts (*1*). Increasing numbers of human *D. repens* infections have been reported from Europe, Africa, and Asia (*2*,*3*). Austria was considered nonendemic, until the first autochthonous case in a human was reported in 2006 (*4*) from the most eastern province, the Burgenland, where *D. repens* nematodes were recently also found for the first time in 2 *Anopheles* mosquito species (*5*). We describe a case of imported ocular dirofilariosis caused by the recently newly proposed species *Candidatus* Dirofilaria hongkongensis (*6*).

The patient, a 38-year-old woman, had recurrent eyelid swelling in both eyes and conjunctival inflammation with watery discharge beginning in June 2011 (online Technical

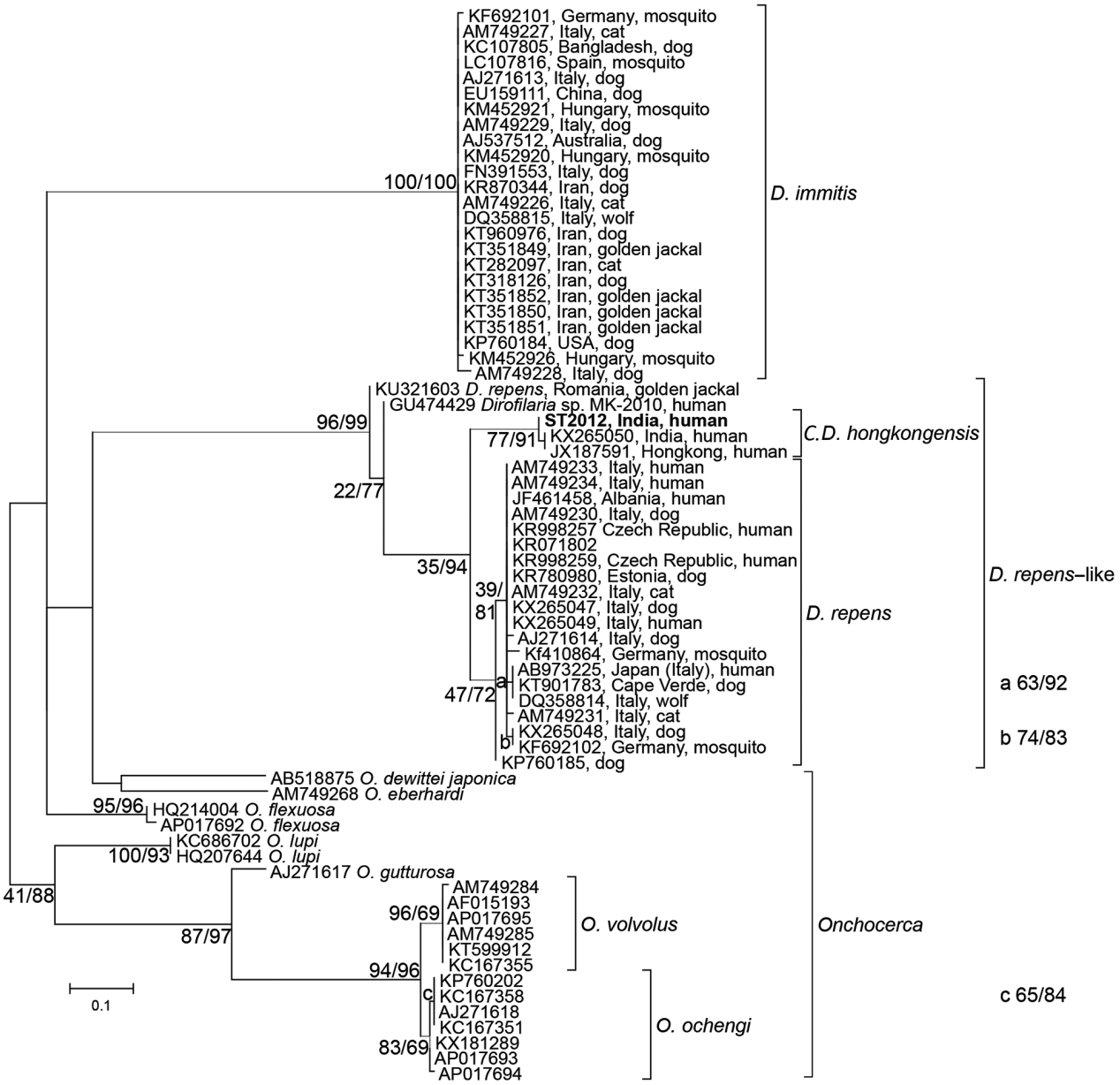

Figure. Phylogenetic analysis of the genus *Dirofilaria* based on cytochrome C oxidase subunit I gene sequences from a worm surgically extracted from the eye of a patient who had returned to Austria after travel to India. Bootstrap values and results of the Shimodaira-Hasegawa test are shown before and after the slash. The sequence from the current patient is shown in bold, and clusters within *Candidatus* Dirofilaria hongkongensis, with *Dirofilaria repens* as the sister taxon. Two samples, classified as *Dirofilaria* sp. MK-2010 (GenBank accession no. GU474429) and *D. repens* from Romania (accession no. KU321603), show very high divergence and probably represent different species. The scale bar represents 0.1 substitutions per site. The samples are identified by GenBank accession numbers, country, and host origin, when available. The genera *Dirofilaria* (*D.*) and *Onchocerca* (*O.*) as well as the *Candidatus* status (*C.*) are abbreviated in species names.

Appendix Figure, panel A, https://wwwnc.cdc.gov/EID/article/23/8/17-0423-Techapp1.pdf). She visited numerous physicians and, upon various putative diagnoses (ranging from sicca syndrome to burnout syndrome), she received corresponding therapies, including antibiotics, steroids, and acupuncture. From January 2012 on, the eyelid swellings were accompanied by a creeping sensation and occurred more often. In early August 2012, she sought care at the emergency department of a university eye clinic in Vienna, Austria. She had a moving object in her left eye. Slit lamp examination revealed a white slender worm moving subconjunctivally in the temporal part of the left eye (online Technical Appendix Figure, panel B). The conjunctiva was opened under topical anesthesia, and a 13-cm worm (online Technical Appendix Figure, panel C) was removed (Video, https://wwwnc.cdc.gov/EID/article/23/8/17-0423-V1.htm) and morphologically identified as a nongravid female of *D. repens* (online Technical Appendix Figure, panel D). Results of serologic testing for filariae were negative before and after extraction of the worm, as were results for testing of EDTA blood for microfilariae. Blood test results, including differential blood counts, were within reference ranges throughout the case history. The patient had returned from a 7-week stay in India, including the areas of Goa, Maharashtra, Delhi, and Uttar Pradesh, 3 months before initial onset of symptoms. Her travel history of the preceding 3 years included 4 more trips to India of several weeks each; a 2-week stay in Israel (October 2010); and a 2-week stay in Dubai, United Arab Emirates (July 2009).

For confirmation of the morphologic identification, we isolated DNA from a 1-cm piece of the worm after homogenization by using the QIAamp DNA Mini Kit (QIAGEN, Hilden, Germany). We amplified fragments of the cytochrome C oxidase subunit I (COI) with panfilarial primers COXfw 5′-GCKTTTCCTCGTGTTATGC-3′/COXrev 5′-CCAGCCAAAACAGGAACAG-3′ and 12S rRNA with panfilarial primers Panfil-12S-F 5′-GTTCCAGAATAATCGGCTA-3′/Panfil-12S-R 5′-ATTGACGGATGRTTTGTACC-3′ (*7*). We sequenced amplicons and subjected them to phylogenetic analyses (online Technical Appendix). All sequence data were submitted to GenBank (accession nos. KY750548–KY750550).

The 329 bp COI fragment (accession no. KY750548) showed 99%–100% identity to 2 sequences from *Candidatus* Dirofilaria hongkongensis (accession nos. KX265050 and JX187591). Identity to *D. repens* sequences was 95%–96%, to *D. immitis* 89%, and to *Onchocerca* spp. up to 92%. The 466 bp mitochondrial 12S rDNA fragment (accession no. KY750549) showed 99% identity to *Candidatus* Dirofilaria hongkongensis sequences from case-patients in India (accession no. KX265050) and Hong Kong (accession no. KY750550), the latter derived from original material of the first description of *Candidatus* Dirofilaria hongkongensis (*6*). Identity to a *Dirofilaria* sp. from a patient returning from India and Sri Lanka and to *Dirofilaria* sp. Thailand II, recently reported among dogs in Thailand (accession nos. KX265092 and KX265093) (*8*), was also 99%. Phylogenetic analysis using the COI sequence clearly placed the sequence into the *Candidatus* Dirofilaria hongkongensis cluster, the sister taxon to *D. repens* (Figure). Although *D. immitis* shows virtually identical COI sequences from 4 continents, genetic variability in *D. repens*–like parasites is obviously much higher, possibly associated with varying zoonotic potentials, reservoirs, and vectors; however, molecular data on *Dirofilaria* are still scarce.

In this case, *Candidatus* Dirofilaria hongkongensis was most likely acquired in India. An infection in Austria seems unlikely because, until now, only 1 singular autochthonous *Dirofilaria* infection has been reported, and that case was classic *D. repens* infection (*4*). Dubai is considered nonendemic for *Dirofilaria* spp. parasites, whereas Israel is known to be endemic for *D. repens* nematodes (*1*,*3*), but the patient's trips to these countries were much longer ago than her latest trip to India. Moreover, all cases from India or Sri Lanka analyzed by us so far represented *Candidatus* Dirofilaria hongkongensis (*8,9*; S. Poppert, unpub. data), suggesting that this species is widely distributed on the Indian subcontinent. In fact, whether classical *D. repens* infection occurs in India at all is unclear. Infections with *Candidatus* Dirofilaria hongkongensis nematodes might take a similar course as infections with classical *D. repens*; however, a case of meningoencephalitis caused by nematodes of this candidate species also has been described (*9*). *Dirofilaria* spp. parasites isolated from human case-patients should be investigated by molecular methods to establish an exact species diagnosis, especially if infections were acquired outside Europe.

Acknowledgments

We thank Iveta Häfeli for excellent technical assistance and the Medical University of Vienna for financial support.

Informed written consent was obtained from the patient for publication of this study and any accompanying images and videos. We are very grateful to the patient for kindly providing all the material.

Dr. Winkler is a specialist for infectious diseases and tropical medicine at the General Hospital in Vienna, Austria. He is also professor of internal medicine at the Medical University of Vienna.

References

1. Pampiglione S, Rivasi F. Human dirofilariasis due to *Dirofilaria (Nochtiella) repens*: an update of world literature from 1995 to 2000. Parassitologia. 2000;42:231–54.
2. Pampiglione S, Rivasi F, Angeli G, Boldorini R, Incensati RM, Pastormerlo M, et al. Dirofilariasis due to *Dirofilaria repens* in

Italy, an emergent zoonosis: report of 60 new cases. Histopathology. 2001;38:344–54. http://dx.doi.org/10.1046/j.1365-2559.2001.01099.x
3. Genchi C, Kramer LH, Rivasi F. Dirofilarial infections in Europe. Vector Borne Zoonotic Dis. 2011;11:1307–17. http://dx.doi.org/10.1089/vbz.2010.0247
4. Auer H, Susani M. The first autochthonous case of subcutaneous dirofilariosis in Austria [in German]. Wien Klin Wochenschr. 2008;120(19–20 Suppl 4):104–6. https://doi.org/10.1007/s00508-008-1031-4
5. Silbermayr K, Eigner B, Joachim A, Duscher GG, Seidel B, Allerberger F, et al. Autochthonous *Dirofilaria repens* in Austria. Parasit Vectors. 2014;7:226. http://dx.doi.org/10.1186/1756-3305-7-226
6. To KK, Wong SS, Poon RW, Trendell-Smith NJ, Ngan AH, Lam JW, et al. A novel *Dirofilaria* species causing human and canine infections in Hong Kong. J Clin Microbiol. 2012;50:3534–41. http://dx.doi.org/10.1128/JCM.01590-12
7. Casiraghi M, Bain O, Guerrero R, Martin C, Pocacqua V, Gardner SL, et al. Mapping the presence of *Wolbachia pipientis* on the phylogeny of filarial nematodes: evidence for symbiont loss during evolution. Int J Parasitol. 2004;34:191–203. http://dx.doi.org/10.1016/j.ijpara.2003.10.004
8. Yilmaz E, Fritzenwanker M, Pantchev N, Lendner M, Wongkamchai S, Otranto D, et al. The mitochondrial genomes of the zoonotic canine filarial parasites *Dirofilaria (Nochtiella) repens* and *Candidatus* Dirofilaria (Nochtiella) hongkongensis provide evidence for presence of cryptic species. PLoS Negl Trop Dis. 2016;10:e0005028. http://dx.doi.org/10.1371/journal.pntd.0005028
9. Poppert S, Hodapp M, Krueger A, Hegasy G, Niesen WD, Kern WV, et al. *Dirofilaria repens* infection and concomitant meningoencephalitis. Emerg Infect Dis. 2009;15:1844–6. http://dx.doi.org/10.3201/eid1511.090936

Address for correspondence: Julia Walochnik, Medical University of Vienna – Parasitology, Kinderspitalgasse 15, Vienna 1095, Austria; email: julia.walochnik@meduniwien.ac.at

Mucus-Activatable Shiga Toxin Genotype *stx2d* in *Escherichia coli* O157:H7

Sergio Sánchez,[1] María Teresa Llorente, Laura Herrera-León, Raquel Ramiro, Sandra Nebreda, María Antonia Remacha, Silvia Herrera-León[1]

Author affiliations: Institute of Health Carlos III, Majadahonda, Spain (S. Sánchez, M.T. Llorente, L. Herrera-León, R. Ramiro, S. Nebreda, S. Herrera-León); León University Hospital, León, Spain (M.A. Remacha)

DOI: https://doi.org/10.3201/eid2308.170570

[1]These authors contributed equally to this article.

We identified the mucus-activatable Shiga toxin genotype *stx2d* in the most common hemolytic uremic syndrome–associated *Escherichia coli* serotype, O157:H7. *stx2d* was detected in a strain isolated from a 2-year-old boy with bloody diarrhea in Spain, and whole-genome sequencing was used to confirm and fully characterize the strain.

The foodborne zoonotic pathogen Shiga toxin (Stx)–producing *Escherichia coli* (STEC) is responsible for human diseases ranging from uncomplicated diarrhea to the life-threatening hemolytic-uremic syndrome (HUS) (*1*). Stx production is the most determining virulence factor implicated in HUS, and the intimin, encoded by *eae*, is the most common adherence factor in HUS-associated STEC (*1*). Stx2d is a Stx2 variant in which cytotoxicity is increased (from 35- to 350-fold) by the action of elastase in intestinal mucus (*2*). This mucus-enhanced toxicity is termed "activation," and activatable Stx2d proteins are designated Stx2dact. Stx2dact production and Stx2dact genotype (*stx2d*) have been associated primarily with *eae*-negative STEC and considered a predictor for severe clinical outcome in such infections (*3*).

All STEC strains received or isolated in the Reference and Research Laboratory of Food and Waterborne Bacterial Infections (Majadahonda, Spain) are routinely tested for *stx1* and *stx2* subtypes by a PCR subtyping method (*4*). For serotyping, O antigen is identified with both commercial antiserum and PCR (*5*), and H antigen is identified by PCR amplification of the *fliC* gene (*6*) and further sequencing of the PCR product. During 2012–2016, *stx2d* was identified in 7 (3%) of 236 STEC strains isolated from patients with HUS and/or diarrhea in Spain (193 *eae*-positive and 43 *eae*-negative strains). Six were *eae*-negative non-O157 STEC belonging to serotypes O73:H18 (2 strains), O91:H21, O148:H8, O181:H49, and ONT:H21. Strikingly, the other *stx2d*-positive strain identified (CNM-2140/12) belonged to serotype O157:H7 and contained *stx2d* in combination with *stx2c*, apart from *eae*. The strain had been isolated from a 2-year-old boy with bloody diarrhea July 2012, and it fermented sorbitol after overnight incubation on sorbitol MacConkey agar (Becton Dickinson, Sparks, MD, USA). We confirmed Stx2 production using the enzyme immunoassay kit SHIGA TOXIN QUIK CHEK (TechLab, Blacksburg, VA, USA). The activatable property of the toxin was confirmed by partial sequencing of the *stx2* gene (*4*), analysis of the resulting nucleotide sequence by comparison with the published *stx2* reference sequences, and comparison of the resulting amino acid sequences. The nucleotide sequence of *stx2d* (GenBank accession no. MF094370) was 100% identical to that of strain 06–5231 (O55:H7, GenBank accession no. EF584538). The sequence was translated to amino acids (online Technical Appendix Figure, https://wwwnc.cdc.gov/EID/article/23/8/17-0570-Techapp1.pdf),

Article DOI: https://doi.org/10.3201/eid2308.170423

Candidatus Dirofilaria hongkongensis as Causative Agent of Human Ocular Filariosis after Travel to India

Technical Appendix

Phylogenetic Analysis

The phylogram includes all cytochrome oxidase sequences for *Dirofilaria*, *Onchocerca volvulus*, and *Onchocerca ochengi* as well as selected sequences for other *Onchocerca* species from GenBank. Sequences were aligned on codon level by using MUSCLE (*1*) as implemented in MEGA6 (*2*). The test for substitution saturation according to Xi et al. (*3*) was negative for both codon positions 1 and 2 and position 3. A phylogenetic model was fitted separately for codon positions 1 and 2 and position 3 by using RAxML (*4*) with the GTR model and 25 Γ distributed rate variation categories among sites and the rapid bootstrap option with 1,000 replicates. The resulting phylogram was also used as input into RAxML to calculate node support with the Shimodaira-Hasegawa modification of the likelihood ratio test.

References

1. Edgar RC. MUSCLE: multiple sequence alignment with high accuracy and high throughput. Nucleic Acids Res. 2004;32:1792–7. PubMed http://dx.doi.org/10.1093/nar/gkh340

2. Tamura K, Stecher G, Peterson D, Filipski A, Kumar S. MEGA6: Molecular Evolutionary Genetics Analysis version 6.0. Mol Biol Evol. 2013;30:2725–9. PubMed http://dx.doi.org/10.1093/molbev/mst197

3. Xia X, Lemey P. Assessing substitution saturation with DAMBE. In: Lemey P, Salemi M, Vandamme A-M, editors. The phylogenetic handbook. Cambridge (UK): Cambridge University Press; 2009. p. 615–30.

4. Stamatakis A. RAxML version 8: a tool for phylogenetic analysis and post-analysis of large phylogenies. Bioinformatics. 2014;30:1312–3. PubMed http://dx.doi.org/10.1093/bioinformatics/btu033

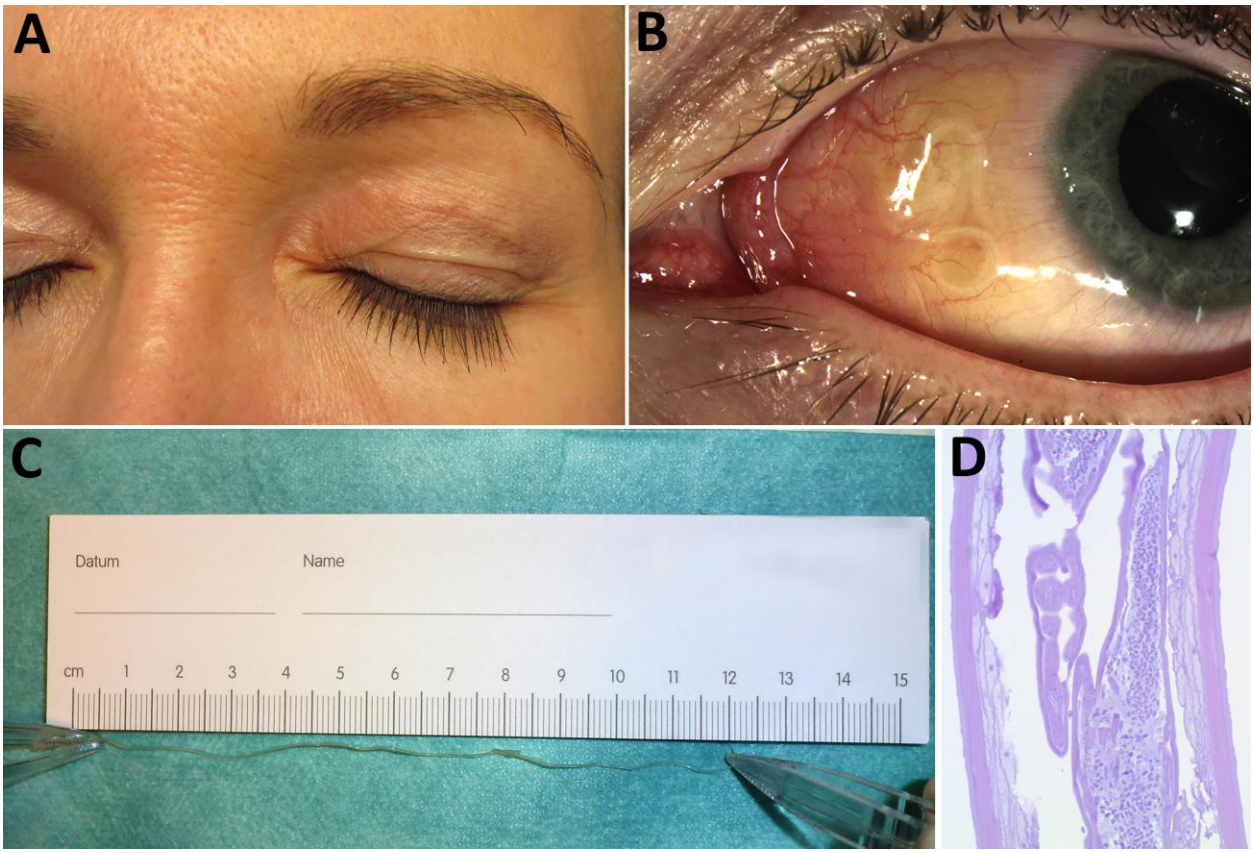

Technical Appendix Figure. Images showing the patient's ocular signs of *Dirofilaria repens* infection and the surgically extracted worm. A) Eyelid swelling (January 2012). B) Worm-like object in the left eye, with anterior chamber and fundus examination revealing no abnormalities (August 2012). C) Size of the extracted worm. D) Longitudinal section of the extracted worm.