Novel Poxvirus in Proliferative Lesions of Wild Rodents in East Central Texas, USA

Carolyn L. Hodo, Matthew R. Mauldin, Jessica E. Light, Kimberly Wilkins, Shiyuyun Tang, Yoshinori Nakazawa, Ginny L. Emerson, Jana M. Ritter, Joanne L. Mansell, Sarah A. Hamer

Northern pygmy mice from 2 localities in east central Texas, USA, had proliferative epidermal lesions on the tail and feet. Electron microscopy of lesion tissue revealed poxvirus. Phylogenetic analyses indicated the virus differed 35% from its closest relatives, the *Chordopoxvirinae*. Future research is needed to determine whether this virus could affect human health.

Chordopoxvirinae is a diverse subfamily of viruses within *Poxviridae*. These geographically widespread viruses infect birds, reptiles, and mammals, and many are zoonotic (*1*). The increasing use of molecular methods has resulted in the identification of several novel poxviruses from humans and animals, many of which probably represent new genera (*2–9*); often, the reported host range of these viruses is limited to the species of the index case. Novel human poxvirus infections identified in the 21st century have often been presumed to have animal origins; for example, an investigation of a novel poxvirus isolated from 2 men in the country of Georgia revealed serologic evidence of orthopoxvirus exposure in cows in their herd and in captured rodents (*5*). We report a novel poxvirus infection characterized by proliferative epidermal lesions in wild northern pygmy mice (*Baiomys taylori*) found at 2 localities in east central Texas, USA, and further characterize the virus through genetic analysis.

The Study

In August 2014, we captured a severely affected adult male *B. taylori* mouse (mouse 1) at the Attwater Prairie Chicken National Wildlife Refuge in Colorado County, Texas. The mouse had large (4–8-mm diameter) proliferative lesions on the hind feet and tail (Figure 1, panel A) but otherwise appeared healthy. In April 2017, at the Biodiversity Research and Teaching Collections at Texas A&M University in College Station, Texas (160 km north of the first locality), we captured an additional adult male *B. taylori* mouse (mouse 2) with mild 1–2-mm proliferative lesions on the left hind foot and tail. Both animals were euthanized in accordance with Texas Parks and Wildlife Department scientific collections permit (SPR-0512-917) and Texas A&M University Institutional Animal Care and Use Committee's animal use protocol (2015-0088). These 2 *B. taylori* specimens are housed at Biodiversity Research and Teaching Collections (mammal voucher nos. TCWC 65223 and TCWC 65224; http://portal.vertnet.org/search).

We subjected mouse 1 to a full necropsy and found the mouse to be in good body condition. Extending from the skin of the dorsal aspect of the left hind foot, plantar aspect of the right hind foot, and the dorsal tail were several firm, pedunculated, irregular masses 0.4–0.8 cm in diameter (Figure 1, panel A). When the masses were sectioned, the cut surface was light tan with a papillated appearance, and the masses did not appear to invade the underlying tissues. The tail was partially amputated but was healed and apparently unrelated to the lesions. We did not observe any other lesions. We froze a section of a mass at −80°C for molecular work and fixed the remaining tissues in 10% neutral-buffered formalin; the fixed tissues were processed for histology and stained with hematoxylin and eosin.

On microscopic examination, necrotizing and proliferative dermatitis was observed. The epidermis of the affected area had multiple large, exophytic, pedunculated masses composed of markedly hyperplastic epithelial cells forming papillary projections with abundant orthokeratotic and parakeratotic hyperkeratosis (Figure 1, panel B). The epithelial surface was multifocally eroded to ulcerated, and the stratum corneum contained aggregates of coccoid bacteria. The stratum spinosum and stratum granulosum were markedly thickened with swollen keratinocytes (ballooning degeneration) frequently containing intracytoplasmic eosinophilic viral inclusions (Figure 1, panels B, C). These inclusions frequently extended extracellularly, forming large lakes ≤50 μm in diameter. The dermis and stratum basale were infiltrated by lymphocytes, plasma cells, and macrophages and a large number of viable and degenerate neutrophils. We examined sections of the spleen, liver, lungs,

Author affiliations: Texas A&M University, College Station, Texas, USA (C.L. Hodo, J.E. Light, J.L. Mansell, S.A. Hamer); Centers for Disease Control and Prevention, Atlanta, Georgia, USA (M.R. Mauldin, K. Wilkins, S. Tang, Y. Nakazawa, G.L. Emerson, J.M. Ritter)

DOI: https://doi.org/10.3201/eid2406.172057

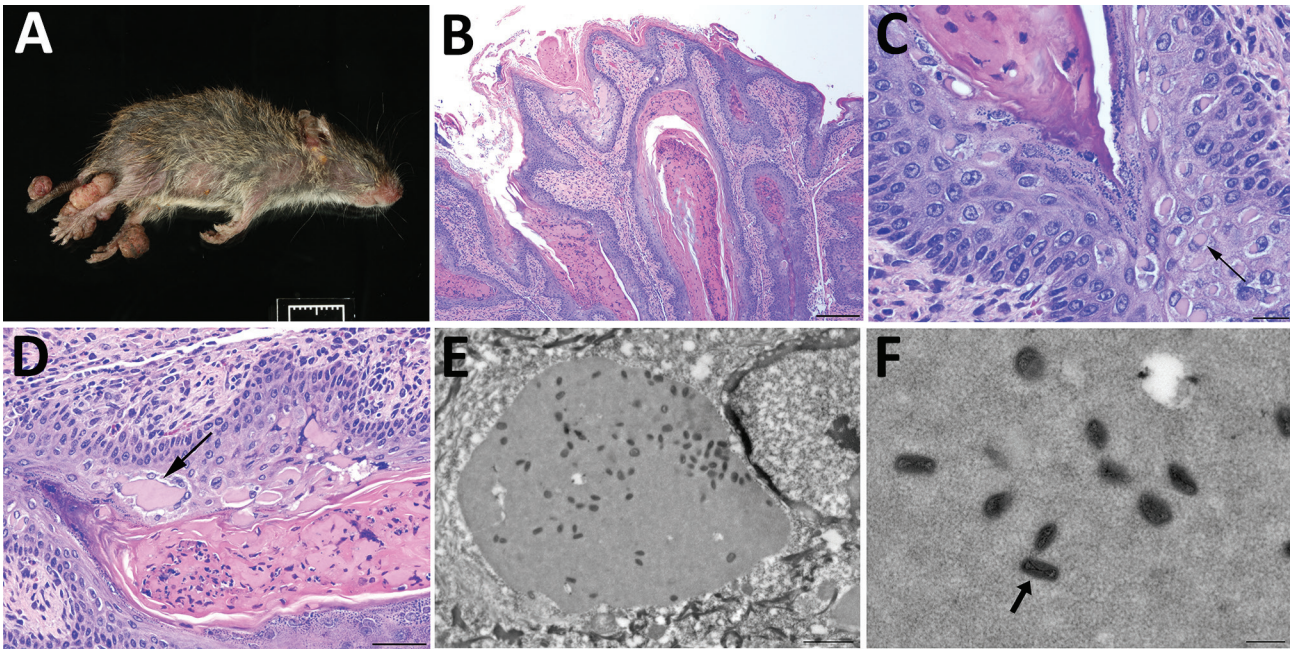

Figure 1. Histologic analysis and electron microscopy of lesions from *Baiomys taylori* mouse 1 infected with novel poxvirus, east central Texas, USA, 2014. A) Large epidermal masses arose from skin of both hind limbs and tail. B–D) Skin mass. Hematoxylin and eosin stain. B) The proliferative epidermis forms papillary projections with abundant hyperkeratosis and thickening of the stratum spinosum and stratum granulosum. Scale bar indicates 200 µm. C, D) Keratinocytes contain intracytoplasmic eosinophilic viral inclusions (C, arrow) that occasionally form extracellular lakes (D, arrow). Panel C scale bar indicates 20 µm; panel D scale bar indicates 50 µm. E, F) Electron microscopy. E) Cytoplasmic inclusions containing granular, electron-dense material and numerous brick-shaped virions. Scale bar indicates 1.5 µm. F) Virions have dense cores and shells of inner and outer membranes consistent with poxvirus (arrow). Scale bar indicates 300 nm.

heart, kidneys, and intestines and identified no substantial lesions. A viral etiology was suspected, so formalin-fixed paraffin-embedded sections of the mass were processed for transmission electron microscopy. Ultra-thin sections were examined with a Morgagni 268 transmission electron microscope (FEI, Hillsboro, OR, USA) at an accelerating voltage of 80 kV. Cytoplasmic inclusions contained granular, electron-dense material and numerous brick-shaped virions with dense cores and inner and outer membrane shell consistent with poxvirus (Figure 1, panel D).

We extracted DNA from skin masses of both mouse 1 and mouse 2 and subjected the DNA to PCR with low–GC content poxvirus primers targeting a region of the putative metalloproteinase gene (*10*) and Sanger sequencing. The virus sequences (220 bp) from mouse 1 (BtTX2014) and mouse 2 (BtTX2017) were identical to each other (GenBank accession no. MG367479), and the top 10 matches to this sequence in GenBank were all poxviruses with only 76%–78% shared identity. In addition, we extracted DNA from formalin-fixed paraffin-embedded sections of liver, lung, kidney, and spleen from mouse 1, and all were PCR negative for poxvirus DNA. A DNA aliquot of the mass from mouse 1 was sent to Otogenetics (Atlanta, GA, USA) for whole-genome sequencing with an Illumina HiSeq platform (Illumina Inc., San Diego, CA, USA). From these data, we extracted 9 core genes of BtTX2014 located within the conserved coding portion of the poxvirus genome used in previous studies (*5*) (GenBank accession nos. MG367480–8). In Geneious version 8.1.4 (https://www.geneious.com/), we converted the gene sequences into amino acid sequences for the purpose of alignment to those of 49 other chordopoxviruses (*Chordopoxvirinae*) and 2 entomopoxviruses (*Entomopxvirinae*), which were used as outgroup taxa. We then concatenated the gene sequences (total alignment 27,674 bp) and conducted partitioned phylogenetic analyses using Bayesian approaches in MrBayes version 3.2.2 (http://mrbayes.sourceforge.net/download.php). The phylogenetic position of this virus revealed it to be a divergent member of the *Chordopoxvirinae* (Figure 2), divergent from other *Chordopoxvirinae* poxviruses by an average of 35% (uncorrected p distances for the 27,674 bp of the concatenated alignment; online Technical Appendix Table, https://wwwnc.cdc.gov/EID/article/24/6/17-2057-Techapp1.pdf).

Conclusions

The poxvirus sequenced from *B. taylori* in east central Texas is distinct from previously identified viruses, with

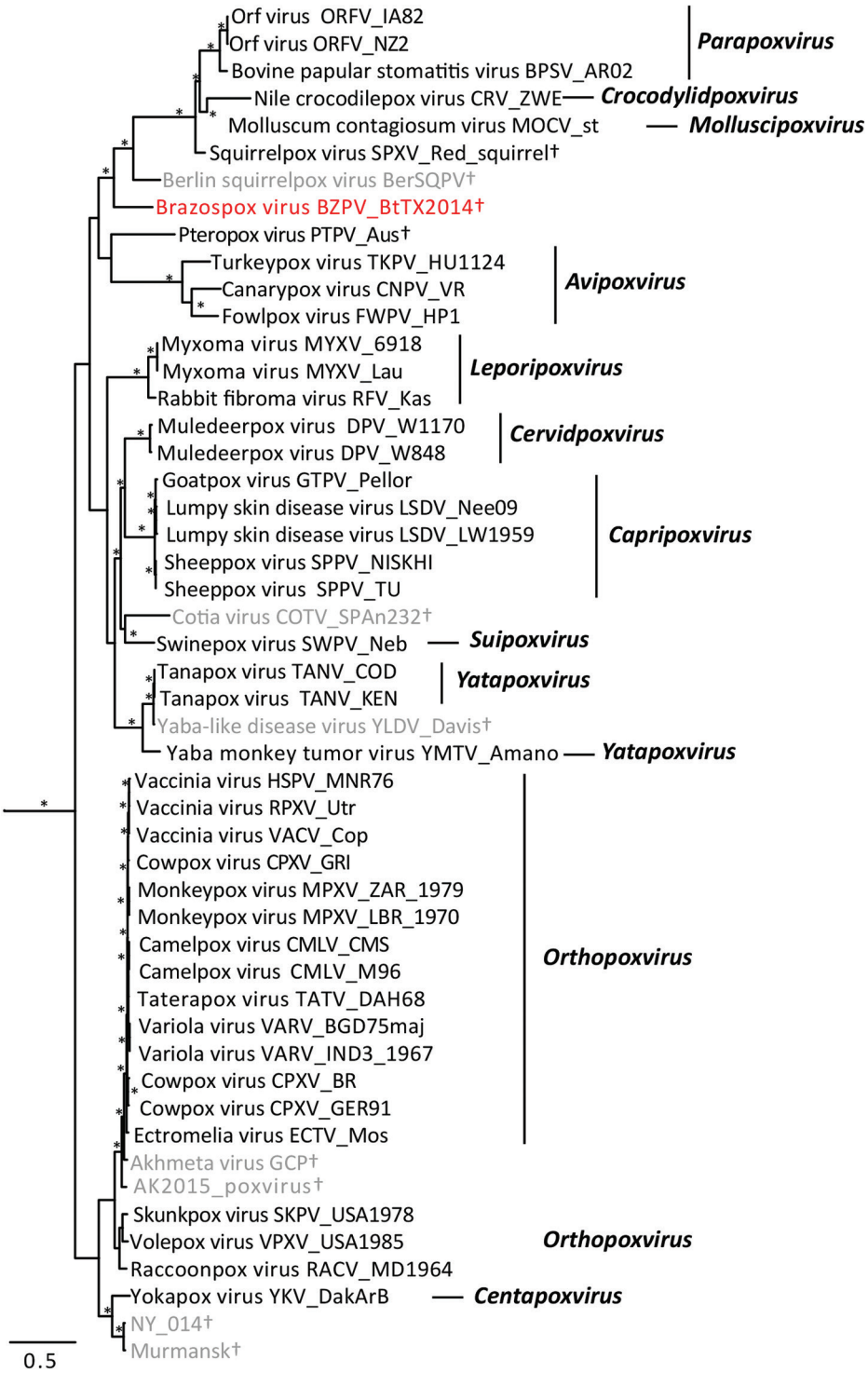

Figure 2. Bayesian phylogram of poxvirus isolates constructed by using a concatenated 27,674-bp alignment of 9 conserved open reading frames (Copenhagen homologs A7L, A10L, A24R, D1R, D5R, E6R, E9L, H4L, and J6R). Genera (if assigned) are listed. Brazospox virus (red; GenBank accession nos. MG367480–8) and sequences from other species not recognized by the International Committee on Taxonomy of Viruses (gray) are indicated. *Nodes with posterior probabilities >0.95; †species not assigned to a genus. Scale bar corresponds to the number of nucleotide substitutions per site.

genetic distances similar to those observed between genera (online Technical Appendix Table). Although support for several phylogenetic relationships is low (possibly due to high genetic variation within *Chordopoxvirinae*), the genetic data strongly suggest this poxvirus does not belong to any recognized genus as of March 2018. We propose the tentative species name Brazospox virus in reference to the proximity of both field sites to the Brazos River.

The epidermal lesions produced by the virus are unique among previously described poxviruses of wild rodents, being proliferative rather than ulcerative in nature, and lacking systemic involvement (*7*,*11*). The

population-level implications of this poxvirus on hosts are unclear. The 2 mice in this study represent the spectrum of observed pathology, from severe (mouse 1) to mild (mouse 2). The virus was confirmed at 2 different localities, and field notes indicate similar lesions were observed in other rodent species. During 2013–2017 (*12*,*13*), among ≈1,800 rodents captured during field research in east central Texas, we documented proliferative lesions on the tail or feet of ≥17 individual rodents of 3 species (*B. taylori*, n = 12; *Chaetodipus hispidus*, n = 2; *Sigmodon hispidus*, n = 3). The combined distributional range of these 3 host species includes ≥20 US states and a large portion of Mexico (*14*).

Novel poxviruses identified in wildlife populations might be useful for the identification of threats to human and animal health. The description of these new viruses contributes to the study of viral diversity and pathogenesis. Propagation of the Brazospox virus in cell culture for use in infection studies, coupled with expanded field surveillance, examination of museum specimens, and full genome analysis could yield additional clues to the origin, pathogenesis, and potential host range of this novel poxvirus.

Acknowledgments

The authors thank H. Ross Payne for his technical expertise with electron microscopy and imaging. We thank Adrian Castellanos, Jaime Rodriguez, and Katelyn Wagner for fieldwork assistance. We thank Rebecca Chester, Mike Morrow, and Terry Rossignol for allowing property access to Attwater Prairie Chicken National Wildlife Refuge and Whitni Davidson for processing samples.

This work was supported in part by the Texas A&M AgriLife Invasive Fire Ant Research and Management Project. Fellowship support was provided by a National Institutes of Health fellowship (no. 2T32OD011083-06 to C.L.H.).

About the Author

Dr. Hodo is a veterinary pathologist and postdoctoral associate at the College of Veterinary Medicine at Texas A&M University (College Station, Texas), with interests in wildlife pathology, disease ecology, and epidemiology.

References

1. Emerson GL, Li Y, Frace MA, Olsen-Rasmussen MA, Khristova ML, Govil D, et al. The phylogenetics and ecology of the orthopoxviruses endemic to North America. PLoS One. 2009;4:e7666–7. http://dx.doi.org/10.1371/journal.pone.0007666
2. Goldsmith CS, Metcalfe MG, Li Y, Davidson WB, Wilkins K, Roess AA, et al. Emergence of previously unknown poxviruses. Microsc Microanal. 2016;22(S3):1184–5. http://dx.doi.org/10.1017/S1431927616006760
3. Smithson C, Meyer H, Gigante CM, Gao J, Zhao H, Batra D, et al. Two novel poxviruses with unusual genome rearrangements: NY_014 and Murmansk. Virus Genes. 2017;53:883–97.
4. Shchelkunov SN. An increasing danger of zoonotic orthopoxvirus infections. PLoS Pathog. 2013;9:e1003756–4. http://dx.doi.org/10.1371/journal.ppat.1003756
5. Vora NM, Li Y, Geleishvili M, Emerson GL, Khmaladze E, Maghlakelidze G, et al. Human infection with a zoonotic orthopoxvirus in the country of Georgia. N Engl J Med. 2015;372:1223–30. http://dx.doi.org/10.1056/NEJMoa1407647
6. Emerson GL, Nordhausen R, Garner MM, Huckabee JR, Johnson S, Wohrle RD, et al. Novel poxvirus in big brown bats, northwestern United States. Emerg Infect Dis. 2013;19:1002–4. http://dx.doi.org/10.3201/eid1906.121713
7. Wibbelt G, Tausch SH, Dabrowski PW, Kershaw O, Nitsche A, Schrick L. Berlin squirrelpox virus, a new poxvirus in red squirrels, Berlin, Germany. Emerg Infect Dis. 2017;23:1726–9. http://dx.doi.org/10.3201/eid2310.171008
8. Goldberg TL, Chapman CA, Cameron K, Saj T, Karesh WB, Wolfe ND, et al. Serologic evidence for novel poxvirus in endangered red colobus monkeys, western Uganda. Emerg Infect Dis. 2008;14:801–3. http://dx.doi.org/10.3201/eid1405.071686
9. Cardeti G, Gruber CEM, Eleni C, Carletti F, Castilletti C, Manna G, et al. Fatal outbreak in Tonkean macaques caused by possibly novel orthopoxvirus, Italy, January 2015. Emerg Infect Dis. 2017;23:1941–9. http://dx.doi.org/10.3201/eid2312.162098
10. Li Y, Meyer H, Zhao H, Damon IK. GC content-based pan-pox universal PCR assays for poxvirus detection. J Clin Microbiol. 2010;48:268–76. http://dx.doi.org/10.1128/JCM.01697-09
11. Bangari DS, Miller MA, Stevenson GW, Thacker HL, Sharma A, Mittal SK. Cutaneous and systemic poxviral disease in red (*Tamiasciurus hudsonicus*) and gray (*Sciurus carolinensis*) squirrels. Vet Pathol. 2009;46:667–72. http://dx.doi.org/10.1354/vp.08-VP-0305-B-BC
12. Rodriguez JE, Hamer SA, Castellanos AA, Light JE. Survey of a rodent and tick community in east-central Texas. Southeast Nat. 2015;14:415–24. http://dx.doi.org/10.1656/058.014.0301
13. Castellanos AA, Medeiros MCI, Hamer GL, Morrow ME, Eubanks MD, Teel PD, et al. Decreased small mammal and on-host tick abundance in association with invasive red imported fire ants (*Solenopsis invicta*). Biol Lett. 2016;12:20160463–5. http://dx.doi.org/10.1098/rsbl.2016.0463
14. International Union for Conservation of Nature. The IUCN red list of threatened species. 2017 [cited 2017 Nov 16]. http://www.iucnredlist.org/

Address for correspondence: Sarah A. Hamer, Department of Veterinary Integrative Biosciences, 4458 TAMU, College Station, TX, 77843-4458, USA; email: shamer@cvm.tamu.edu

Article DOI: https://doi.org/10.3201/eid2406.172057

Novel Poxvirus in Proliferative Lesions of Wild Rodents in East-Central Texas, USA

Technical Appendix

Technical Appendix Table. Taxon information and genetic distances of poxvirus isolates included in phylogenetic analysis of Brazospox virus BtTX2014 sequence, East-Central Texas, 2014

Species*	Genus	Isolate†	GenBank accession no.	Genetic distance from Brazospox virus, %‡
Brazospox virus§	Unassigned	BtTX2014	MG367480–8	
Canarypox virus	*Avipoxvirus*	CNPV_VR	NC_005309	38.2
Fowlpox virus	*Avipoxvirus*	FWPV_HP1	AJ581527	38.9
Turkeypox virus	*Avipoxvirus*	TKPV_HU1124	NC_028238	39.1
Goatpox virus	*Capripoxvirus*	GTPV_Pellor	NC_004003	33.6
Lumpy skin disease virus	*Capripoxvirus*	LSDV_LW1959	AF409138	33.5
Lumpy skin disease virus	*Capripoxvirus*	LSDV_Nee09	NC_003027	33.5
Sheeppox virus	*Capripoxvirus*	SPPV_NISKHI	AY077834	33.5
Sheeppox virus	*Capripoxvirus*	SPPV_TU	NC_004002	33.5
Yokapox virus	*Centapoxvirus*	YKV_DakArB	HQ849551	33.4
Muledeerpox virus	*Cervidpoxvirus*	DPV_W1170	AY689437	32.9
Muledeerpox virus	*Cervidpoxvirus*	DPV_W848	NC_006966	32.8
Nile crocodilepox virus	*Crocodylidpoxvirus*	CRV_ZWE	NC_008030	48.3
Myxoma virus	*Leporipoxvirus*	MYXV_6918	EU552530	34.8
Myxoma virus	*Leporipoxvirus*	MYXV_Lau	NC_001132	34.8
Rabbit fibroma virus	*Leporipoxvirus*	RFV_Kas	NC_001266	34.6
Molluscum contagiosum virus	*Molluscipoxvirus*	MOCV_st	NC_001731	43.4
Camelpox virus	*Orthopoxvirus*	CMLV_CMS	AY009089	33.0
Camelpox virus	*Orthopoxvirus*	CMLV_M96	NC003391	33.0
Cowpox virus	*Orthopoxvirus*	CPXV_BR	NC_003663	33.0
Cowpox virus	*Orthopoxvirus*	CPXV_GER91	DQ437593	33.0
Cowpox virus	*Orthopoxvirus*	CPXV_GRI	X94355	32.8
Ectromelia virus	*Orthopoxvirus*	ECTV_Mos	NC004105	33.1
Monkeypox virus	*Orthopoxvirus*	MPXV_LBR_1970	DQ011156	33.0
Monkeypox virus	*Orthopoxvirus*	MPXV_ZAR_1979	DQ011155	33.0
Raccoonpox virus	*Orthopoxvirus*	RACV_MD1964	FJ807746–54	33.1
Skunkpox virus	*Orthopoxvirus*	SKPV_USA1978	FJ807755–63	32.8
Taterapox virus	*Orthopoxvirus*	TATV_DAH68	NC008291	33.0
Vaccinia virus (horsepox)	*Orthopoxvirus*	HSPV_MNR76	DQ792504	32.9
Vaccinia virus (rabbitpox)	*Orthopoxvirus*	RPXV_Utr	AY484669	32.9
Vaccinia virus	*Orthopoxvirus*	VACV_Cop	M35027	32.9
Variola virus	*Orthopoxvirus*	VARV_BGD75maj	L22579	33.0
Variola virus	*Orthopoxvirus*	VARV_IND3_1967	NC_001611	33.1
Volepox virus	*Orthopoxvirus*	VPXV_USA1985	FJ807737–45	33.0
Bovine papular stomatitis virus	*Parapoxvirus*	BPSV_AR02	NC_005337	45.2
Orf virus	*Parapoxvirus*	ORFV_IA82	AY386263	45.4
Orf virus	*Parapoxvirus*	ORFV_NZ2	DQ184476	45.4
Swinepox virus	*Suipoxvirus*	SWPV_Neb	NC_003389	33.2
Akhemta virus§	Unassigned	GCP	KM046934–42	33.1
Cotia virus§	Unassigned	COTV-SPAn232	HQ647181	34.8
Pteropox virus	Unassigned	PTPV_Aus	KU980965	36.9
Squirrelpox virus	Unassigned	SPXV_Red_squirrel	HE601899	41.0
Yaba-like disease virus§	Unassigned	YLDV_Davis	NC_002642	33.2
AK2015_poxvirus§	Unassigned	AK2015_poxvirus	KX914668–76	33.0
NY_014§	Unassigned	NY_014	MF001305	32.8
Murmansk§	Unassigned	LEIV-11411 Mur-Lovozero	MF001304	32.8
Berlin squirrelpox virus (BerSQPV)§	Unassigned	BerSQPV	MF503315	31.4
Tanapox virus	*Yatapoxvirus*	TANV_COD	EF420157	33.3
Tanapox virus	*Yatapoxvirus*	TANV_KEN	NC_098882	33.3

Species*	Genus	Isolate†	GenBank accession no.	Genetic distance from Brazospox virus, %‡
Yaba monkey tumor virus	*Yatapoxvirus*	YMTV_Amano	NC_005179	33.4
Amscata moorei entomopoxvirus L	*Betaentomopoxvirus*	AMEV_Moyer	NC_002520	60.0
Melanoplus sanguinipes entomopoxvirus O	Unassigned	MSEV_Tucson	NC_001993	60.3

*Species names follow the International Committee on Taxonomy of Viruses, although not all isolates have been officially recognized as species and some are unassigned to a genus. All isolates belong to the subfamily *Chordopoxvirinae*, except for the outgroup taxa (AMEV_Moyer and MSEV_Tuscon), which belong to the *Entomopoxvirna.*
†Isolates match taxon labels in Figure 2 of main text.
‡Genetic distances are uncorrected p distances.
§Not officially recognized species.