on day 4 postonset, which preceded cerebral complications on day 14 postonset. Brain complications, including subarachnoid (*6*), pituitary hemorrhage (*7*), and encephalitis (*8*), with orthohantavirus infections have been reported. The direct effect of the virus into the brain has been demonstrated in an animal model (*9*), which raises the question whether intracranial bleeding for this case-patient was associated with endothelial damage directly from the virus infection.

In conclusion, we report an orthohantavirus infection in New York that caused intracranial bleeding and hydrocephalus that required an emergent surgical intervention. Because orthohantaviruses are endemic to North America and several strains/species have not been fully characterized, it is essential that clinicians recognize and be aware of other clinical manifestations of these infections (e.g., kidney injury), which are often indicators of subsequent complications.

About the Author

Dr. Fernando is an infectious diseases specialist at Stony Brook Southampton Hospital, Southampton, NY. His primary research interest is tropical medicine.

References

1. Nuovo GJ, Simsir A, Steigbigel RT, Kuschner M. Analysis of fatal pulmonary hantaviral infection in New York by reverse transcriptase in situ polymerase chain reaction. Am J Pathol. 1996;148:685–92.
2. Woods C, Palekar R, Kim P, Blythe D, de Senarclens O, Feldman K, et al. Domestically acquired Seoul virus causing hemorrhagic fever with renal syndrome, Maryland, 2008. Clin Infect Dis. 2009;49:e109–12. http://dx.doi.org/10.1086/644742
3. McMullan LK, Albariño CG, Ksiazek TG, Nichol ST, Spiropoulou CF. Complete genome sequences of a hantavirus isolate from New York. Genome Announc. 2018;6:e00188–18. http://dx.doi.org/10.1128/genomeA.00188-18
4. Nichol ST, Spiropoulou CF, Morzunov S, Rollin PE, Ksiazek TG, Feldmann H, et al. Genetic identification of a hantavirus associated with an outbreak of acute respiratory illness. Science. 1993;262:914–7. http://dx.doi.org/10.1126/science.8235615
5. Centers for Disease Control and Prevention. Annual US hantavirus disease and HPS case fatality, 1993–2016 [cited 2018 Nov 30]. https://www.cdc.gov/hantavirus/surveillance/annual-cases.html
6. Xu Z, Xu P, Lei X, Xu Z, Wu Q, Zhang J. Subarachnoid hemorrhage associated with epidemic hemorrhagic fever: a rare case report. Int J Med Sci. 2011;8:640–2. http://dx.doi.org/10.7150/ijms.8.640
7. Hautala T, Hautala N, Mähönen SM, Sironen T, Pääkkö E, Karttunen A, et al. Young male patients are at elevated risk of developing serious central nervous system complications during acute Puumala hantavirus infection. BMC Infect Dis. 2011;11:217. http://dx.doi.org/10.1186/1471-2334-11-217
8. Talamonti L, Padula PJ, Canteli MS, Posner F, Marczeski FP, Weller C. Hantavirus pulmonary syndrome: encephalitis caused by virus Andes. J Neurovirol. 2011;17:189–92. http://dx.doi.org/10.1007/s13365-010-0011-4
9. Shin OS, Song GS, Kumar M, Yanagihara R, Lee HW, Song JW. Hantaviruses induce antiviral and pro-inflammatory innate immune responses in astrocytic cells and the brain. Viral Immunol. 2014;27:256–66. http://dx.doi.org/10.1089/vim.2014.0019

Address for correspondence: Luis A. Marcos, Stony Brook University Health Sciences Center School of Medicine, Internal Medicine, Division of Infectious Disease, 101 Nicolls Rd, Health Science Center T16, Rm 027J, Stony Brook, NY 11794, USA; email: luis.marcos@stonybrookmedicine.edu

Rickettsia japonica Infection after Land Leech Bite, Japan

Eiichiro Sando, Motoi Suzuki, Mitsuya Katayama, Masakatsu Taira, Hiromi Fujita, Koya Ariyoshi

Author affiliations: Kameda Medical Center, Kamogawa, Japan (E. Sando, M. Katayama); Nagasaki University, Nagasaki, Japan (E. Sando, M. Suzuki, K. Ariyoshi); Chiba Prefectural Institute of Public Health, Chiba, Japan (M. Taira); Mahara Institute of Medical Acarology, Anan, Japan (H. Fujita)

DOI: https://doi.org/10.3201/eid2506.181985

We report a case of *Rickettsia japonica* infection in an 81-year-old man in central Japan. The patient had fever, rash, and an eschar but no evidence of a tick bite. His symptoms began 8 days after a land leech bite. The land leech is a potential vector of *R. japonica*.

Japanese spotted fever, a tickborne disease caused by *Rickettsia japonica*, has been reported in Japan, Korea, and China (*1*–*3*). We describe a case of Japanese spotted fever after a land leech (*Haemadipsa zeylanica japonica*) bite.

On August 3, 2016, an 81-year-old man was transported to an emergency department with a 2-day history of fever (temperature of 38°C), staggering, appetite loss, and general malaise. He was undergoing hormonal therapy for prostate cancer and had an indwelling urinary catheter. However, he was fully independent and walked 2 km every day as a tour guide to a mountain road in the southern Boso area of Japan. At admission, he was alert and oriented, with no apparent fever (temperature of 36.8°C). Clinicians observed a nonpruritic, painless rash on his torso and extremities (Figure, panels A, B), including his palms and the soles of his feet. The attending physician thoroughly searched for an eschar and noted only a single nonpruritic, painless lesion on the man's lower abdomen (Figure, panel C). The patient and his family reported that the eschar appeared at the site where a land leech had been attached on July 24, 10

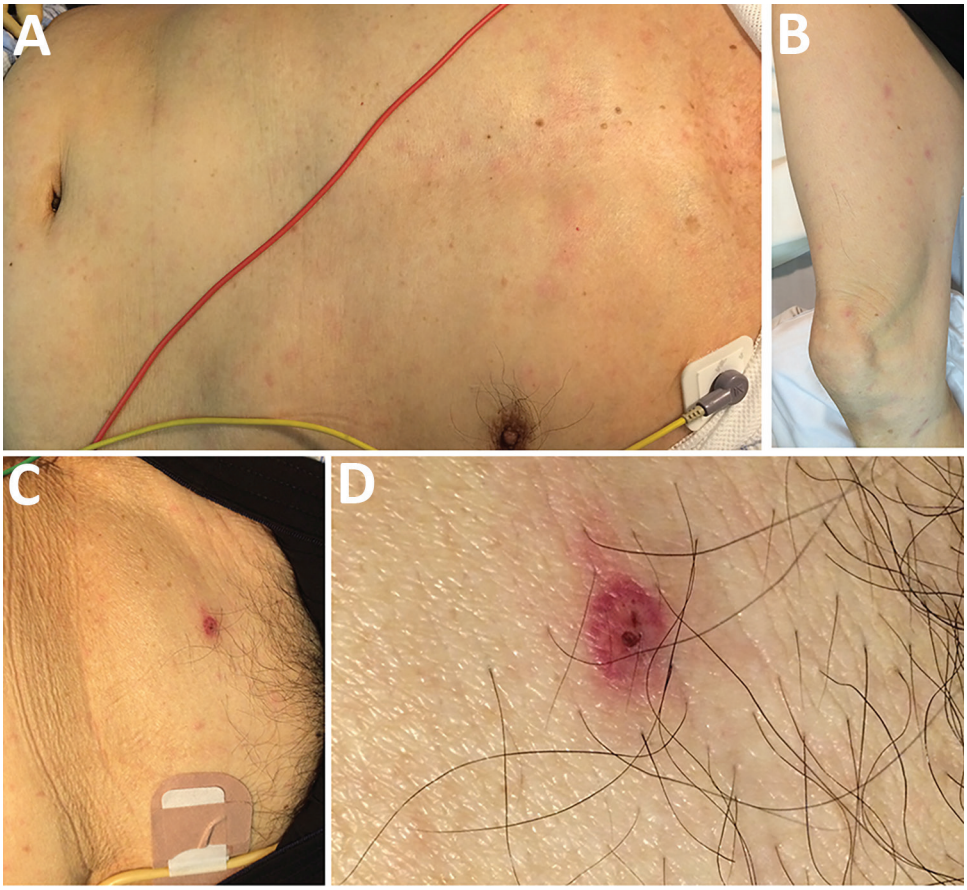

Figure. Patient with *Rickettsia japonica* infection after being bitten by a land leech, Japan. A, B) Erythematous macular rash on the patient's torso (A) and extremities (B); C, D) eschar on the lower abdomen showing an atypical appearance with a relatively well-demarcated boundary of erythema with a tiny scab.

days before admission, and that the site bled when the leech was removed. They denied any tick bite.

Notable laboratory data included low platelet count (102,000/μL), slightly elevated aspartate aminotransferase (52 IU/L), elevated lactate dehydrogenase (468 IU/L), and elevated C-reactive protein (5.37 mg/dL). Urinalysis was positive for protein and occult blood. Chest radiograph and electrocardiogram findings were unremarkable.

We suspected rickettsial disease because the patient had typical symptoms, including fever, rash, and eschar, and a history of walking in the mountains. We sent his blood samples and the crust of the eschar to the Chiba Prefectural Institute of Public Health (Chiba, Japan) for indirect immunofluorescence and PCR assays (Appendix, https://wwwnc.cdc.gov/EID/article/25/6/18-1985-App1.pdf). In addition, the blood samples were tested at the Mahara Institute of Medical Acarology (Anan, Japan) with indirect immunoperoxidase assay to identify 6 *Orientia tsutsugamushi* serotypes: Kato, Karp, Gilliam, Irie/Kawasaki, Hirano/Kuroki, and Shimokoshi.

The patient received 100 mg of minocycline intravenously every 12 hours for 7 days and received the same dose orally for 1 day after he was discharged. His symptoms promptly resolved without any complications.

Paired serum antibody titers against *R. japonica* in the acute phase (day 1 of treatment) were IgM <1:20 and IgG <1:20 but increased to IgM 1:1,280 and IgG 1:10,240 in the convalescent phase (day 21 of treatment). The samples tested for *O. tsutsugamushi* were negative for all serology except IgG titer against serotypes Karp (1:160) and Hirano/Kuroki (1:80) in both acute and convalescent phases, indicating past infection with *O. tsutsugamushi*. Target genes obtained from the eschar were identical with *R. japonica*; the 17-kDa protein had 100% sequence homology and *gltA* 99.5% (Appendix Figures 1, 2).

We detected *R. japonica* from the eschar formed after a land leech bite in a patient without evidence of a tick bite. Most patients with rickettsial diseases, such as Japanese spotted fever and scrub typhus, do not notice a tick or mite bite (*4*), but a leech bite is easy to detect because the site bleeds for an extended time due to hirudin in leech saliva. We conducted a thorough physical examination to check for tick bites but found no additional eschar on this patient. In our experience (*4*), a typical eschar caused by a tick or mite bite appears as a circular crater with a scab, red flare with an indistinct border, and desquamation. However, the eschar in this case was atypical because of a relatively well-

demarcated boundary of erythema with a tiny scab (Figure, panel D).

A new species of *Rickettsia* was detected from leeches in Japan (*5*,*6*). Furthermore, certain leech species, parasitizing frogs or fish, can complete the vertical transmission of *Rickettsia* spp. with possible horizontal transmission (*6*). The leech is reported to be a potential vector for human rickettsial infections (*7*,*8*). Slesak et al. described the case of a 39-year-old woman with *R. felis* infection confirmed by eschar PCR after a leech bite in northern Laos (*7*). Balcells et al. reported the case of a 54-year-old man with scrub typhus–like illness after a leech bite in southern Chile (*8*). In our previous study (*4*), 13% (4/31) of patients with Japanese spotted fever and 2% (4/188) of patients with scrub typhus diagnosed by serologic tests had a history of land leech bite before the symptom onset.

Our report is limited because we did not have the land leech for testing by PCR. The patient might have had rickettsia on his skin and then been inoculated by the leech bite or by scratching after the bite (*7*). Further investigations, including an experimental model, are needed to support the potential role of leeches in the transmission of *R. japonica* and other *Rickettsia* spp.

Acknowledgments

We thank the patient, who provided written consent for publishing this case report and the accompanying images; Satoshi Kobayashi for the patient's care and his assistance in collecting samples; and Shuji Ando for critical comments.

This study was supported by the Japan Agency for Medical Research and Development under grant no. JP18fk0108068.

About the Author

Dr. Sando is a general physician at the Kameda Medical Center, Kamogawa, Japan, and an assistant professor at the Institute of Tropical Medicine, Nagasaki University, Nagasaki, Japan. His primary research interest is rickettsial diseases.

References

1. National Institute of Infectious Disease–Japan. Scrub typhus and Japanese spotted fever in Japan 2007–2016. Infectious Agent Surveillance Report. Tokyo: The Institute; 2017.
2. Chung M-H, Lee S-H, Kim M-J, Lee J-H, Kim E-S, Lee J-S, et al. Japanese spotted fever, South Korea. Emerg Infect Dis. 2006;12:1122–4. http://dx.doi.org/10.3201/eid1207.051372
3. Lu Q, Yu J, Yu L, Zhang Y, Chen Y, Lin M, et al. *Rickettsia japonica* infections in humans, Zhejiang Province, China, 2015. Emerg Infect Dis. 2018;24:2077–9. http://dx.doi.org/10.3201/eid2411.170044
4. Sando E, Suzuki M, Katoh S, Fujita H, Taira M, Yaegashi M, et al. Distinguishing Japanese spotted fever and scrub typhus, Central Japan, 2004–2015. Emerg Infect Dis. 2018;24:1633–41. http://dx.doi.org/10.3201/eid2409.171436
5. Kikuchi Y, Sameshima S, Kitade O, Kojima J, Fukatsu T. Novel clade of *Rickettsia* spp. from leeches. Appl Environ Microbiol. 2002;68:999–1004. http://dx.doi.org/10.1128/AEM.68.2.999-1004.2002
6. Kikuchi Y, Fukatsu T. *Rickettsia* infection in natural leech populations. Microb Ecol. 2005;49:265–71. http://dx.doi.org/10.1007/s00248-004-0140-5
7. Slesak G, Inthalath S, Dittrich S, Paris DH, Newton PN. Leeches as further potential vectors for rickettsial infections. Proc Natl Acad Sci U S A. 2015;112:E6593–4. http://dx.doi.org/10.1073/pnas.1515229112
8. Balcells ME, Rabagliati R, García P, Poggi H, Oddó D, Concha M, et al. Endemic scrub typhus-like illness, Chile. Emerg Infect Dis. 2011;17:1659–63. http://dx.doi.org/10.3201/eid1709.100960

Address for correspondence: Eiichiro Sando, Department of Clinical Medicine, Institute of Tropical Medicine, Nagasaki University, Nagasaki, Japan; email: eiichiro-ymn@umin.ac.jp

Schistosome Interactions within the *Schistosoma haematobium* Group, Malawi

Bonnie L. Webster, Mohammad H. Alharbi, Sekeleghe Kayuni, Peter Makaula, Fenella Halstead, Rosie Christiansen, Lazarus Juziwelo, Michelle C. Stanton, E. James LaCourse, David Rollinson, Khumbo Kalua, J. Russell Stothard

Author affiliations: Natural History Museum, London, UK (B.L. Webster, D. Rollinson); Ministry of Health, Qassim, Saudi Arabia (M.H. Alharbi); Liverpool School of Tropical Medicine, Liverpool, UK (M.H. Alharbi, S. Kayuni, F. Halstead, R. Christiansen, E.J. LaCourse, J.R. Stothard); Medical Aid Society of Malawi, Blantyre, Malawi (S. Kayuni); Research for Health Environment and Development, Mangochi, Malawi (P. Makaula); Ministry of Health, Lilongwe, Malawi (L. Juziwelo); Lancaster University Medical School, Lancaster, UK (M.C. Stanton); Lions Sight First Eye Hospital, Blantyre (K. Kalua)

DOI: https://doi.org/10.3201/eid2506.190020

Molecular analysis of atypical schistosome eggs retrieved from children in Malawi revealed genetic interactions occurring between human (*Schistosoma haematobium*) and livestock (*S. mattheei* and *S. bovis*) schistosome species. Detection of hybrid schistosomes adds a notable new perspective to the epidemiology and control of urogenital schistosomiasis in central Africa.

Article DOI: https://doi.org/10.3201/eid2506.181985

Rickettsia japonica Infection after Land Leech Bite

Appendix

Polymerase chain reaction (PCR) assay and DNA sequencing

We sent an eschar sample collected from the patient to the Chiba Prefectural Institute of Public Health (Chiba, Japan). DNA was extracted from the sample by using the High Pure PCR Preparation kit (Roche Diagnostics, https://www.roche.com) according to the manufacturer's instructions. A duplex real-time PCR assay targeting a fragment of the 16S rDNA was performed for the simultaneous detection of *O. tsutsugamushi* and spotted fever group *Rickettsia* spp. (*1*).

Following the detection of spotted fever group *Rickettsia* spp. DNA, the 17 kDa protein and *glt*A genes were amplified (*2*,*3*). Distilled water was used as a negative control and *R. japonica* YH strain as a positive control. The PCR amplicons were further sequenced by using BigDye Terminator v1.1 Cycle Sequencing Kit and Applied Biosystems 3130 Genetic Analyzer (ThermoFisher Scientific, https://www.thermofisher.com). Phylogenetic trees were constructed in MEGA 6.0 software (https://www.megasoftware.net) using the neighbor-joining method. Bootstrap values were calculated based on 1,000 replications of the alignment (*4*).

The target genes from the patient's eschar were submitted to GenBank, accession number LC460478 for 17 kDa protein, and accession number LC460479 for *gltA* gene.

References

1. Kawamori F, Shimazu Y, Sato H, Monma N, Ikegaya A, Yamamoto S, et al. Evaluation of diagnostic assay for rickettsioses using duplex real-time PCR in multiple laboratories in Japan. Jpn J Infect Dis. 2018;71:267–73. PubMed http://dx.doi.org/10.7883/yoken.JJID.2017.447

2. Mediannikov OY, Sidelnikov Y, Ivanov L, Mokretsova E, Fournier PE, Tarasevich I, et al. Acute tick-borne rickettsiosis caused by *Rickettsia heilongjiangensis* in Russian Far East. Emerg Infect Dis. 2004;10:810–7. PubMed http://dx.doi.org/10.3201/eid1005.030437

3. Furuya Y, Katayama T, Yoshida Y, Kaiho I. Specific amplification of *Rickettsia japonica* DNA from clinical specimens by PCR. J Clin Microbiol. 1995;33:487–9. PubMed

4. Tamura K, Stecher G, Peterson D, Filipski A, Kumar S. MEGA6: Molecular Evolutionary Genetics Analysis version 6.0. Mol Biol Evol. 2013;30:2725–9. PubMed http://dx.doi.org/10.1093/molbev/mst197

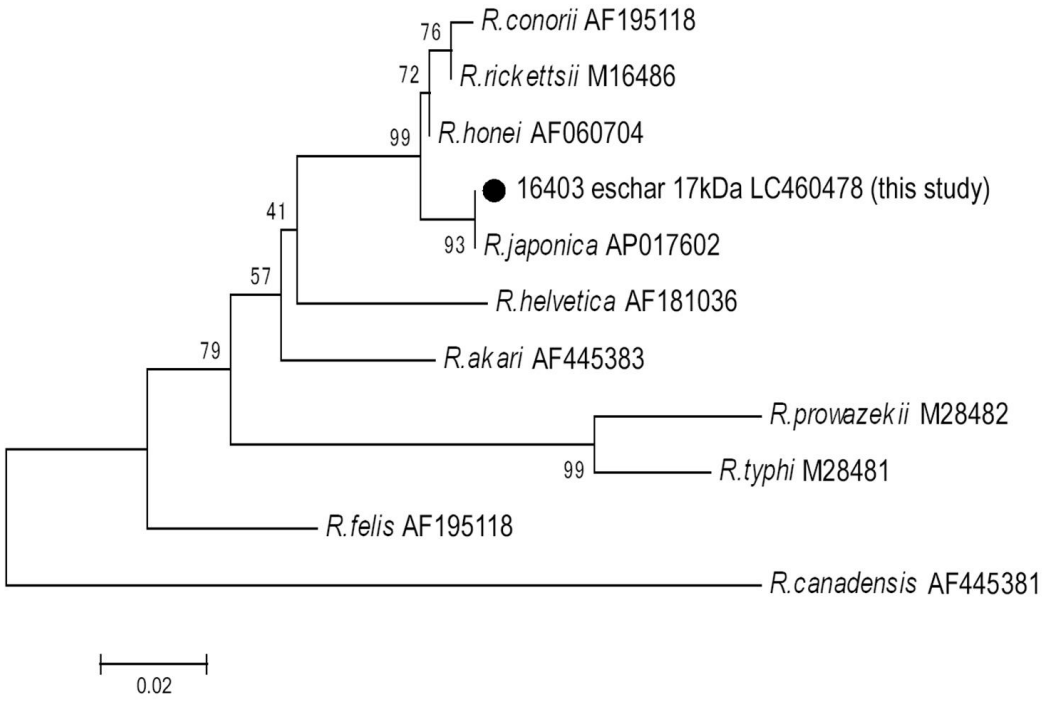

Appendix Figure 1. Phylogenetic tree of *Rickettsia* spp. genes comparing 17 kDa protein from eschar of a land leech bite, Japan. Phylogenetic relationships based on the sequence of the 357-bp fragment of the omp gene for 17 kDa protein. Circle represents sequence from this study. Scale bar indicates nucleotide substitutes per site.

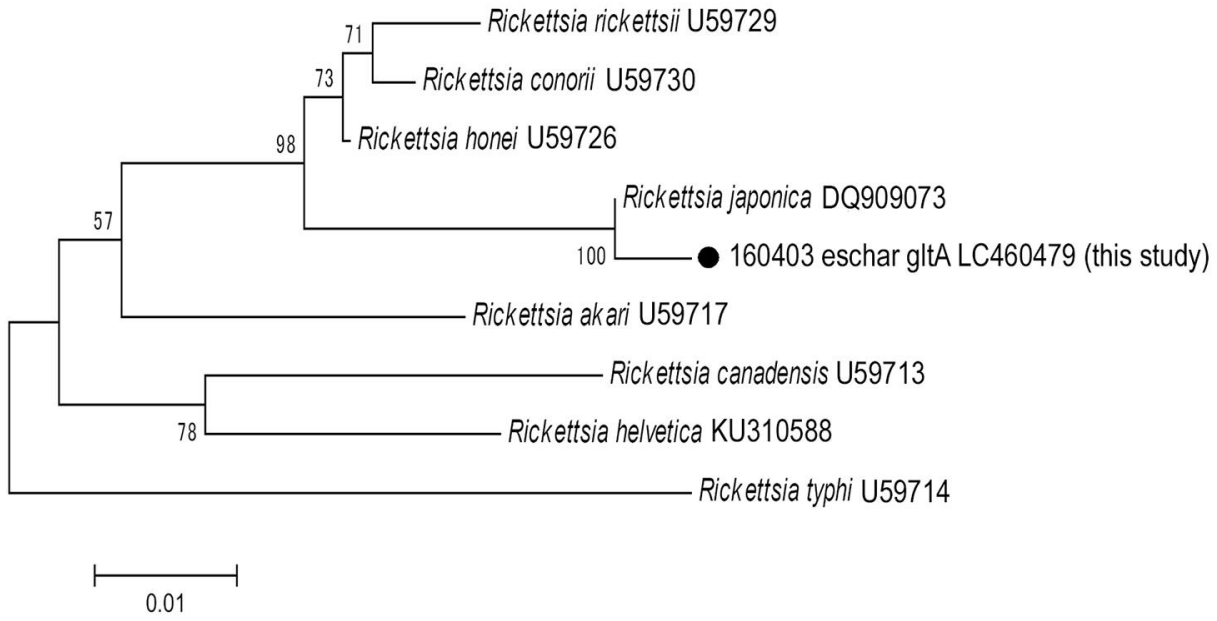

Appendix Figure 2. Phylogenetic tree of *Rickettsia* spp. genes comparing *gltA* from eschar of a land leech bite, Japan. Phylogenetic relationships based on the sequence of the 388-bp fragment of the *gltA* gene for citrate synthase. Scale bar indicates nucleotide substitutes per site.