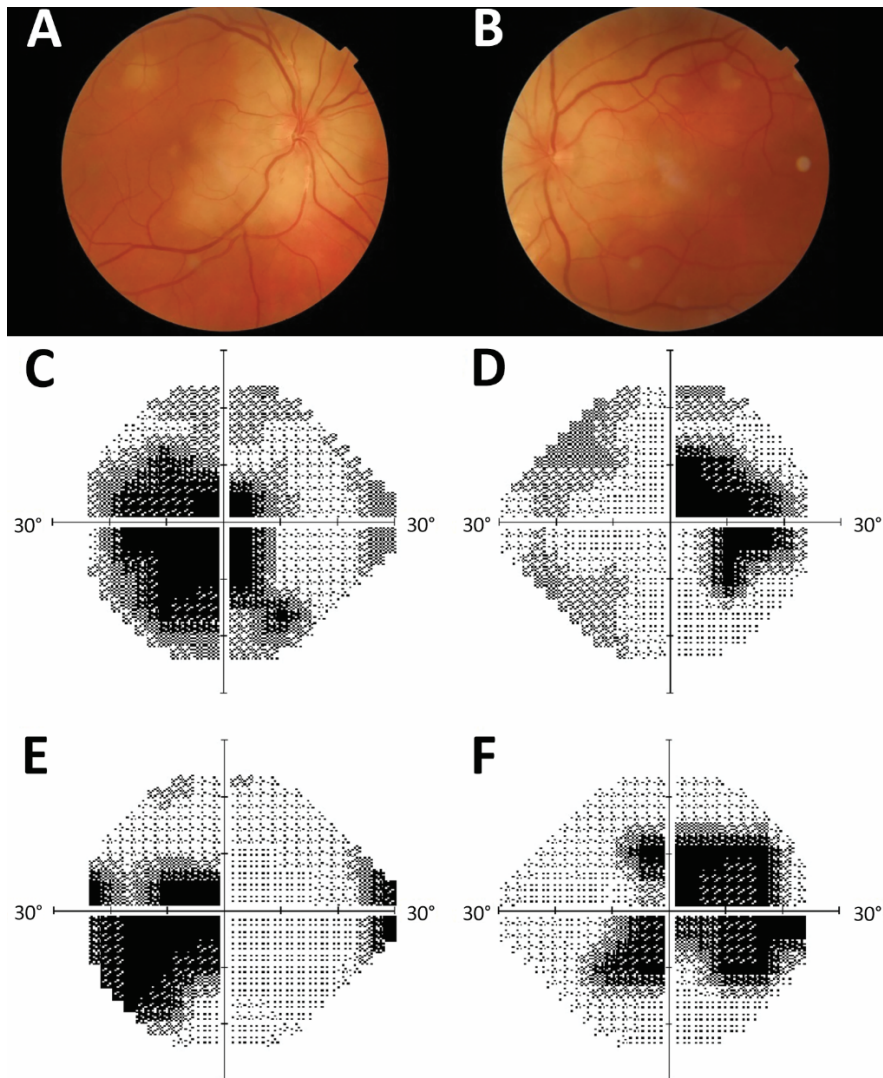


Diagnosis of Syphilitic Bilateral Papillitis Mimicking Papilloedema

Appendix



Appendix Figure. Patient images from investigation of diagnosis of syphilitic bilateral papillitis mimicking papilloedema. (A-B) funduscopy showing bilateral optic disk swelling and peripapillary retinitis; (C-D) visual fields showing bilateral central scotoma and enlarged blind spot at the time of diagnosis; (E-F) visual fields after 3 months.