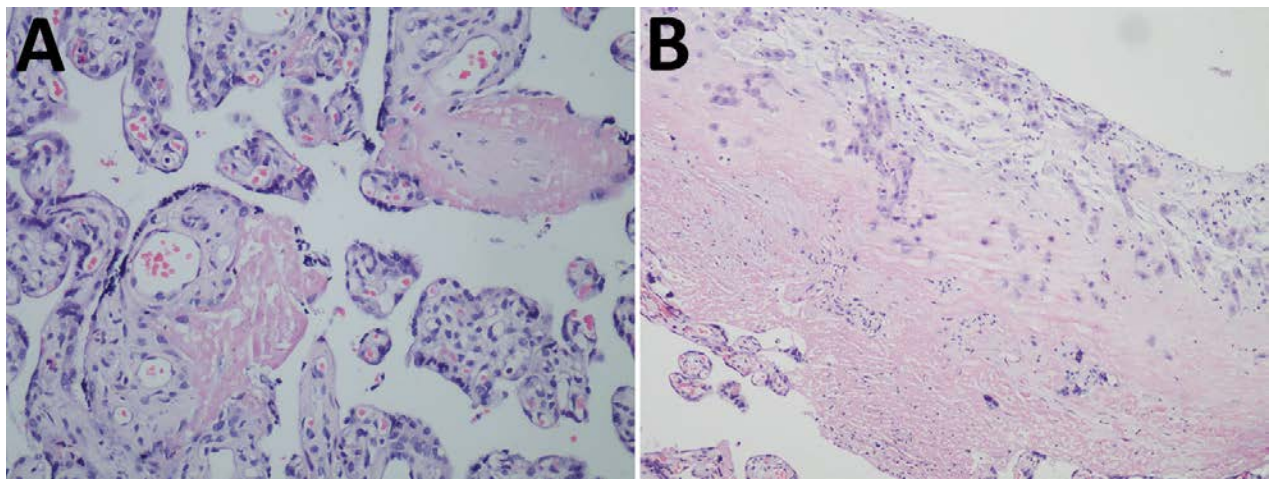


Disappearance of SARS-CoV-2 Antibodies in Infants Born to Women with COVID-19, Wuhan, China

Appendix



Appendix Figure. Pathologic examination of the placenta. A) Normal placenta villi. B) Slight fibrin deposition and lymphocytes infiltrate.