Ocular *Spiroplasma ixodetis* in Newborns, France

Alexandre Matet, Anne Le Flèche-Matéos, François Doz, Pascal Dureau, Nathalie Cassoux

Cataract and uveitis are rare in newborns but potentially blinding. Three newborns with cataract and severe anterior uveitis underwent cataract surgery. *Spiroplasma ixodetis* was detected in lens aspirates using bacterial 16S-rRNA PCR and transmission electron microscopy. These findings, which suggest maternal–fetal infection, are consistent with previous experimental *Spiroplasma*-induced cataract and uveitis.

Spiroplasma is a genus of Mollicutes, a class of bacteria without cell wall. *Spiroplasma* are intracellular organisms with helical morphology and a small genome (0.78–2.2 Mb) comprising 38 species isolated from insects, crustaceans, and plants (*1*,*2*). Ticks, from which *Spiroplasma ixodetis* has been isolated, are abundant sources of *Spiroplasma* (*3*).

Spiroplasma develop a commensal, pathogenic, or mutualist pathogen–host relationship. The first isolated species (*S. citri*) was described in 1973 (*4*,*5*). Two *Spiroplasma* infections have been reported in humans: an intraocular infection in a newborn with Group VI *Spiroplasma*, now known as *S. ixodetis* (*6*), and a systemic infection in an immunocompromised adult with *S. turonicum* (*7*). These reports suggest that tetracyclines and macrolides are effective against *Spiroplasma* (*6*,*7*). We describe 3 newborns in France who had cataract and intraocular inflammation and in whom *S. ixodetis* was detected in ocular samples (Table).

The Case-Patients

In January 2014, case-patient 1, a 26-day-old girl with unremarkable medical history, was referred for bilateral leukocoria observed by her parents at 20 days of age, suggestive of retinoblastoma. She was born after normal full-term pregnancy without delivery complications (birthweight 2,820 g; Apgar score 10). She had bilateral anterior uveitis, large keratic precipitates, iris nodules, posterior synechiae, cyclitic membrane, and cataract (Figure 1, panels A, B). Fundus visualization and ocular ultrasonography ruled out retinoblastoma. Physical examination results were unremarkable. Blood cell count showed elevated monocytes (1.5×10^9/L [reference range $0.2–1.0 \times 10^9$/L]); serologic results for *Toxoplasma gondii*, rubella virus, cytomegalovirus, herpes simplex viruses 1 and 2, HIV-1 and -2, and *Mycoplasma* were negative. Aqueous humor cytologic examination did not reveal malignant cells but identified macrophages, suggesting intraocular infection, as observed in *Tropheryma whipplei*–related uveitis (*8*). Treatment with topical dexamethasone (8 drops/d with progressive tapering), topical atropine (0.3%, 2 drops/d), and oral josamycin (125 mg 2×/d) was initiated. Anterior chamber inflammation decreased dramatically, and cataract surgery with intraocular lens implantation was performed sequentially in both eyes 4 weeks later. We conducted microbiological investigations of lens and anterior vitreous aspirates from the right eye, including bacteriologic and mycologic cultures, and 16S-rRNA-based PCR for bacterial identification (Appendix, https://wwwnc.cdc.gov/EID/article/26/2/19-1097-App1.pdf). Cultures remained negative, but bacterial PCR identified a complete sequence of the *rrs* gene, showing 98.7% similarity to the type strains of *S. ixodetis* (Figure 2). Uveitis did not recur over the next 4 years.

In January 2018, bilateral leukocoria caused by bilateral congenital cataract was detected in an otherwise healthy boy, case-patient 2, on day 3 after full-term birth (birthweight 2,900 g; Apgar score 10). Pregnancy was unremarkable, without maternal seroconversion for toxoplasmosis, rubella, herpes simplex viruses 1 and 2, or cytomegalovirus. Six weeks after birth, ophthalmologic examination under anesthesia revealed a total cataract in each eye with large keratic precipitates, posterior synechiae, and immature dilated iris vessels (Figure 1, panels C, D). Fundus was inaccessible in both eyes. The right eye was slightly microphthalmic. Because of the rarity of uveitis with

Author affiliations: Institut Curie and Université Paris Descartes, Paris, France (A. Matet, F. Doz, N. Cassoux); Institut Pasteur, Paris (A. Le Flèche-Matéos); Fondation Ophtalmologique Adolphe de Rothschild, Paris (P. Dureau)

DOI: https://doi.org/10.3201/eid2602.191097

Table. Characteristics of 3 newborns with cataract and anterior uveitis* and 5 controls with congenital cataracts without signs of intraocular infection, France†

ID no.	Sex	Date of diagnosis	Age at diagnosis/lens extraction, mo	Affected eye	Clinical ocular findings	Region of residence (environment)	Travel during pregnancy	Crystalline lens sample volume, µL	Bacterial 16S-rRNA PCR, % homology to *S. ixodetis*
Case-patients									
1	F	2014 Jan	1/2	Both	Cataract + anterior uveitis	Hauts-de-France, France (rural area, adjacent to Saint-Gobain Forest)	No	200	98.7
2	M	2018 Jan	0/3	Both	Cataract + anterior uveitis	Centre-Val de Loire, France (rural area, adjacent to Loire-Anjou-Touraine Regional Forest)	No	150	98.6
3	M	2019 Jan	1/2	Left	Cataract + anterior uveitis	Ile-de-France, France (Paris suburban area)	No	100	98.7
Controls									
1	F	2018 Feb	4/5	Right	Cataract	NA	NA	50	Negative
2	M	2018 Apr	4/5	Right	Cataract + nystagmus	NA	NA	10	Negative
3	M	2018 Apr	4/5	Left	Cataract + nystagmus	NA	NA	200	Negative
4	F	2018 Feb	1/2	Left	Cataract	NA	NA	100	Negative
5	F	2018 Mar	0/3	Left	Cataract	NA	NA	50	Negative

*Positive for *Spiroplasma ixodetis* in crystalline lens material by bacterial 16S-rRNA PCR.
†For all case-patients and controls, pregnancy was normal and delivery was uneventful. NA, not applicable.

keratic precipitates and cataract in newborns and the similarity to case-patient 1, the child underwent bilateral cataract extraction without lens implantation, and lens material was sent for bacteriologic investigations. The 16S-rRNA–based PCR of the *rrs* gene identified in both eyes was 98.6% similar to *S. ixodetis*. Mild, self-resolving bilateral intravitreal hemorrhage developed after cataract surgery. Anterior segment

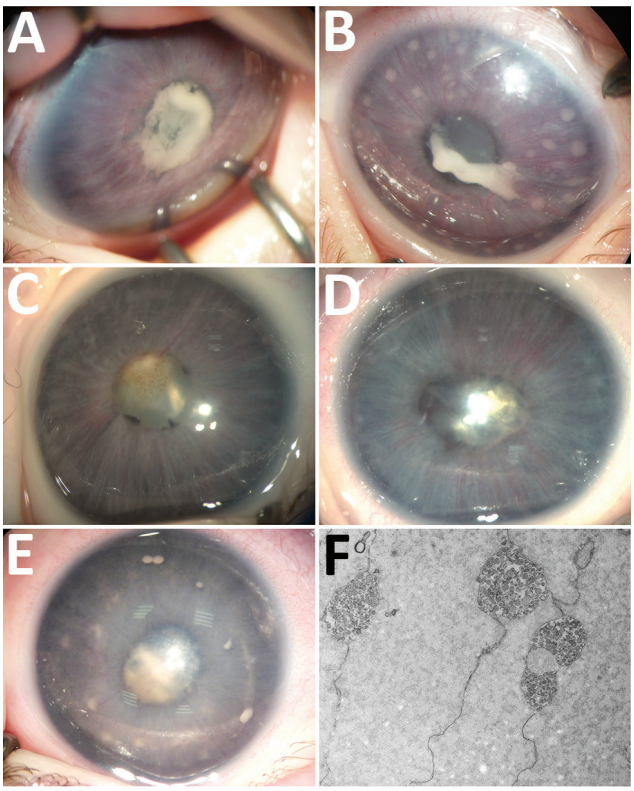

Figure 1. Ocular anterior segment in 3 newborn infants with bilateral total cataract and anterior uveitis related to endogenous *Spiroplasma ixodetis* infection. A, B) Case-patient 1. Right (A) and left (B) eyes of a 4-week-old girl showing total cataract, posterior synechiae due to a cyclitic fibrinic membrane, and large keratic precipitates more visible in the left eye. The immature iris vasculature is dilated in the context of anterior segment inflammation. C, D) Case-patient 2. Right (C) and left (D) eyes of a 6-week-old boy showing total cataract, posterior synechiae, dilated immature iris vessels, and few keratic precipitates more visible in the left eye. E) Case-patient 3. Left eye of a 1-month-old boy with multiple retrocorneal white deposits, total cataract, posterior synechiae, and immature dilated iris vessels. F) Case-patient 3. Electron transmission microscopy of crystalline lens material from a 2-month-old boy with total cataract and anterior uveitis, revealing the presence of microorganisms with spiral-like projections highly suggestive of bacteria from the *Spiroplasma* genus.

inflammation resolved under topical dexamethasone (4 drops/d with progressive tapering over 3 months) and atropine (0.3%, 1 drop/d for 1 month) and did not recur over the next 18 months.

In January 2019, case-patient 3, a 1-month-old boy, was referred for left eye leukocoria, first observed 1 week after birth. Pregnancy was uneventful, and delivery was normal at 36 weeks' gestation

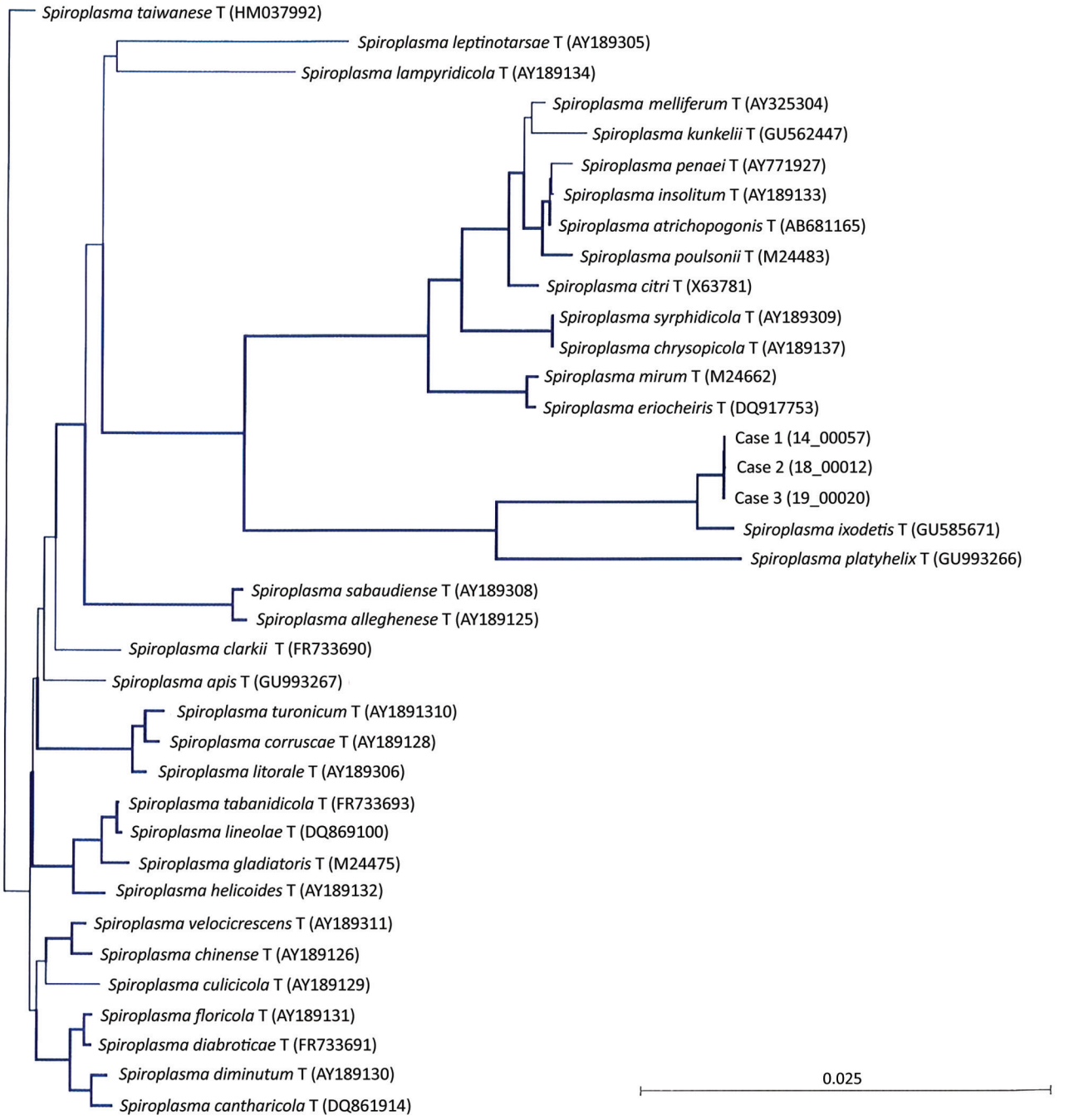

Figure 2. Neighbor-joining unrooted tree based on bacterial *rrs* gene sequences from the crystalline lens samples from 3 newborns with cataract and uveitis (case-patient 1, sample 14_00057; case-patient 2, sample 18_00012; case-patient 3, sample 19_00020). The 14_00057 (case-patient 1) and 19_00020 (case-patient 3) sequences differed by 1 nt along the 1,284-bp bacterial *rrs* gene, and the 18_00012 sequence (case-patient 2) harbored 2 additional nucleotides and differed from 14_00057 by 3 nt and from 19_00020 by 2 nt. At the variation site, the corresponding sequences were _ _ G (14_00057, case-patient 1), T G A (18_00012, case-patient 2), and _ _ A (19_00020, case-patient 3). Thick lines indicate bootstrap values >75% (based on 1,000 replicates). Scale bar indicates the proportion of substitutions per nucleotide position.

(birthweight 2,800 g; Apgar score 10). Left eye examination revealed multiple large keratic white deposits, total cataract, posterior synechiae, and immature dilated iris vessels (Figure 1, panel E). Results of a right eye examination were unremarkable. He underwent cataract extraction with synechialysis, without intraocular lens implantation. 16S rRNA–based PCR of the bacterial *rrs* gene performed on crystalline lens aspirates identified *S. ixodetis* with 98.7% similarity. Fresh crystalline lens samples analyzed by electron transmission microscopy revealed microorganisms with spiral-like projections matching the morphology of bacteria from the *Spiroplasma* genus (Figure 1, panel F). Postoperative mild intravitreal hemorrhage developed but self-resolved over 4 weeks. He was treated postoperatively with oral josamycin (125 mg 2×/d for 10 days), topical atropine (0.3% 2×/d for 1 month), and topical drops combining neomycin, polymixin B, and dexamethasone (4×/d with progressive tapering over 1 month). Intraocular inflammation did not recur over the next 6 months.

We conducted all PCRs in *Spiroplasma* DNA–free facilities. Internal negative controls were introduced during DNA manipulation/amplification (Appendix). No control was positive after 16S rRNA PCR amplification, confirming that the detection of *Spiroplasma* sequences did not result from contamination.

To confirm that *S. ixodetis* is absent in intraocular media of newborns with noninflammatory cataracts, we collected crystalline lens samples from 5 newborns with congenital cataracts who underwent surgery before 6 months of age (Table). 16S rRNA–based PCR did not identify any bacterial signature in these samples. The Internal Review Board of the French Society of Ophthalmology approved this study.

Conclusions

Until recently, *Spiroplasma* spp. were considered nonpathogenic in humans. Our observations confirm the reports by Lorenz et al. of an intraocular *Spiroplasma* spp. infection (*6*), and by Aquilino et al. of a systemic infection (*7*). Moreover, the congenital presentation of case-patients 1–3 suggests maternal–fetal transmission during pregnancy or delivery, despite the absence of maternal symptoms. Our findings are consistent with those of Lorenz et al., who described a premature baby born at 27 weeks' gestation who, at 4 months of age, had unilateral uveitis with corneal precipitates, posterior synechiae, and cataract. After cataract surgery, bacterial 16S-rRNA PCR of vitreous and lens aspirates identified *Spiroplasma* spp. Group VI (*6*), now referred to as *S. ixodetis* (*9*). Electron microscopy visualized filamentous and helical microorganisms compatible with *Spiroplasma*.

Another clade of *Spiroplasma*, *S. mirum*, phylogenetically close to *S. ixodetis* (Figure 2), initially named suckling mouse cataract agent (*9*,*10*), induces rapid cataract formation after intracerebral injection in newborn mice (*11*), rats (*12*), and rabbits (*13*), with variable intraocular inflammation. In these models, adult animals do not develop ocular pathology, suggesting a vulnerability of the immature eye to *Spiroplasma* infection. Moreover, a high rate of microphthalmia developed in these animals, as in case-patient 2, suggesting that *Spiroplasma* infection might interfere with ocular development.

Our observations suggest that intrauterine or early postnatal contamination with *Spiroplasma* spp. might lead to unilateral or bilateral cataract and anterior uveitis in newborns. A similar causative *S. ixodetis* subtype was identified in all 3 infants, without technical contamination. Two of 3 case-patients lived in a rural area adjacent to a forest.

The frequency of this intraocular infection in newborns may be underestimated. *Spiroplasma* are fastidious organisms detectable using PCR techniques not routinely performed on intraocular samples. Because affected infants are at high risk for visual impairment or blindness, pediatricians, ophthalmologists, and microbiologists should be aware of possible *S. ixodetis* ocular infections and collect clinical, bacteriologic, and epidemiologic data on this emerging pathogen. The mechanisms and timing of probable maternal–fetal transmission require further investigations. On the basis of these observations, we recommend systematic bacterial 16S-rRNA PCR analysis on intraocular fluids and lens material from neonates with cataract and uveitis.

About the Author

Dr. Matet is an ophthalmologist and ocular oncology specialist at Institut Curie and Paris Descartes University. His primary research interests include pediatric and adult ocular tumors, radiation therapy, ocular inflammation and infection, and retinal imaging.

References

1. Gasparich GE. Spiroplasmas: evolution, adaptation and diversity. Front Biosci. 2002;7:d619–40.
2. Regassa LB, Gasparich GE. Spiroplasmas: evolutionary relationships and biodiversity. Front Biosci. 2006;11:2983–3002. https://dx.doi.org/10.2741/2027
3. Cisak E, Wójcik-Fatla A, Zając V, Sawczyn A, Sroka J, Dutkiewicz J. *Spiroplasma*—an emerging arthropod-borne pathogen? Ann Agric Environ Med. 2015;22:589–93. https://dx.doi.org/10.5604/12321966.1185758
4. Tully JG, Whitcomb RF, Bove JM, Saglio P. Plant mycoplasmas: serological relation between agents associated

with citrus stubborn and corn stunt diseases. Science. 1973;182:827–9. https://dx.doi.org/10.1126/science.182.4114.827
5. Whitcomb RF, Tully JG, Bové JM, Saglio P. Spiroplasmas and acholeplasmas: multiplication in insects. Science. 1973;182:1251–3. https://dx.doi.org/10.1126/science.182.4118.1251
6. Lorenz B, Schroeder J, Reischl U. First evidence of an endogenous *Spiroplasma* sp. infection in humans manifesting as unilateral cataract associated with anterior uveitis in a premature baby. Graefes Arch Clin Exp Ophthalmol. 2002; 240:348–53. https://dx.doi.org/10.1007/s00417-002-0453-3
7. Aquilino A, Masiá M, López P, Galiana AJ, Tovar J, Andrés M, et al. First human systemic infection caused by *Spiroplasma*. J Clin Microbiol. 2015;53:719–21. https://dx.doi.org/10.1128/JCM.02841-14
8. Touitou V, Fenollar F, Cassoux N, Merle-Beral H, LeHoang P, Amoura Z, et al. Ocular Whipple's disease: therapeutic strategy and long-term follow-up. Ophthalmology. 2012;119:1465–9. https://dx.doi.org/10.1016/j.ophtha.2012.01.024
9. Gasparich GE, Whitcomb RF, Dodge D, French FE, Glass J, Williamson DL. The genus *Spiroplasma* and its non-helical descendants: phylogenetic classification, correlation with phenotype and roots of the *Mycoplasma mycoides* clade. Int J Syst Evol Microbiol. 2004;54:893–918. https://dx.doi.org/10.1099/ijs.0.02688-0
10. Tully JG, Whitcomb RF, Williamson DL, Clark HF. Suckling mouse cataract agent is a helical wall-free prokaryote (*Spiroplasma*) pathogenic for vertebrates. Nature. 1976;259:117–20. https://dx.doi.org/10.1038/259117a0
11. Olmsted E, Prasad S, Sheffer J, Clark HF, Karzon DT. Ocular lesions induced in C57 mice by the suckling mouse cataract agent (SMCA). Invest Ophthalmol. 1966;5:413–20.
12. Friedlaender RP, Barile MF, Kuwabara T, Clark HF. Ocular pathology induced by the suckling mouse cataract agent. Invest Ophthalmol. 1976;15:640–7.
13. Kirchhoff H, Heitmann J, Trautwein G. Pathogenicity of *Spiroplasma* sp. strain SMCA in rabbits: clinical, microbiological, and histological aspects. Infect Immun. 1981;33:292–6.

Address for correspondence: Alexandre Matet, Institut Curie, Service d'Ophtalmologie, 26 Rue d'Ulm, F-75248 Paris CEDEX 5, France; email: alexandre.matet@curie.fr

The Public Health Image Library (PHIL)

The Public Health Image Library (PHIL), Centers for Disease Control and Prevention, contains thousands of public health–related images, including high-resolution (print quality) photographs, illustrations, and videos.

PHIL collections illustrate current events and articles, supply visual content for health promotion brochures, document the effects of disease, and enhance instructional media.

PHIL images, accessible to PC and Macintosh users, are in the public domain and available without charge.

Visit PHIL at:
https://phil.cdc.gov/phil

Article DOI: https://doi.org/10.3201/eid2602.191097

Ocular *Spiroplasma ixodetis* in Newborns, France

Appendix

Methods for 16S rRNA PCR Bacterial Identification on Crystalline Lens Aspirates Retrieved during Cataract Extraction Surgery (Cases 1, 2, and 3 and Controls)

After surgery, biologic samples were stored at –80°C until analysis. PCR mixes were prepared in a special laboratory equipped with an airlock and with PCR chambers. DNA extraction was performed in a second laboratory with an airlock and Microbiological Safety Cabinet. Positive amplifications were performed in a third laboratory facility, where *Spiroplasma* spp. samples had never been previously manipulated.

Three negative controls were introduced at key steps of the DNA manipulation and PCR processes: one negative control introduced at the beginning, and one at the end of DNA extraction, respectively, and one negative control introduced in the PCR. None of the three controls was positive for bacterial DNA after 16S-rRNA PCR amplification.

For *rrs* gene (encoding 16S rRNA) sequencing, universal primers were used and 1.5 kb of the *rrs* gene was amplified by PCR (*1*). The amplified product was sequenced with four primers. On one hand, the primer A corresponding to position 8 to 28 of *Escherichia coli* 16S rRNA and the primer rE (5′-GGACTACCAGGGTATCTAAT-3′) corresponds to the complement of positions 806 to 787. On the other hand, the primer D (5′-CAGCAGCCGCGGTAATAC-3′) corresponds to positions 519–536 and the primer rJ (5′-GGTTACCTTGTTACGACTT-3′) corresponds to the complement of positions. Nucleotides were numbered according to Brosius et al., 1978 (*2*). A total of 1446 bp for the *rrs* gene were determined. The complete sequence was compared to all bacterial sequences available from GenBank database using the BLAST program (https://blast.ncbi.nlm.nih.gov/Blast.cgi). A phylogenetic tree was generated with CLC Bio software, using the neighbor-joining algorithm (*3*).

The GenBank accession numbers for *rrs* gene sequences of strains 14–00057 (Case 1), 18–00012 (Case 2) and 19–00020 (Case 3) are MN207005, MN166760, and MN166762, respectively.

Methods for Electron Microscopy Imaging of Crystalline Lens Aspirates Retrieved during Cataract Extraction Surgery (Case-Patient 3)

A fraction of the crystalline lens material retrieved from case-patient 3 was cultured on A7 medium. After 2 weeks, small colonies became visible using a conventional ×4 microscope. The colonies were sampled and resin-included. Seventy-micrometer sections were imaged using transmission electron microscopy to investigate the morphology of the colony-forming microorganisms.

References

1. Janvier M, Grimont PA. The genus *Methylophaga*, a new line of descent within phylogenetic branch gamma of Proteobacteria. Res Microbiol. 1995;146:543–50. PubMed http://dx.doi.org/10.1016/0923-2508(96)80560-2

2. Brosius J, Palmer ML, Kennedy PJ, Noller HF. Complete nucleotide sequence of a 16S ribosomal RNA gene from Escherichia coli. Proc Natl Acad Sci U S A. 1978;75:4801–5. PubMed http://dx.doi.org/10.1073/pnas.75.10.4801

3. Saitou N, Nei M. The neighbor-joining method: a new method for reconstructing phylogenetic trees. Mol Biol Evol. 1987;4:406–25. PubMed