Ehrlichiosis and Anaplasmosis among Transfusion and Transplant Recipients in the United States

Sanjida J. Mowla, Naomi A. Drexler, Cara C. Cherry, Pallavi D. Annambholta, Ian T. Kracalik, Sridhar V. Basavaraju

Medscape EDUCATION ACTIVITY

In support of improving patient care, this activity has been planned and implemented by Medscape, LLC and Emerging Infectious Diseases. Medscape, LLC is jointly accredited by the Accreditation Council for Continuing Medical Education (ACCME), the Accreditation Council for Pharmacy Education (ACPE), and the American Nurses Credentialing Center (ANCC), to provide continuing education for the healthcare team.

Medscape, LLC designates this Journal-based CME activity for a maximum of 1.00 ***AMA PRA Category 1 Credit(s)™***. Physicians should claim only the credit commensurate with the extent of their participation in the activity.

Successful completion of this CME activity, which includes participation in the evaluation component, enables the participant to earn up to 1.0 MOC points in the American Board of Internal Medicine's (ABIM) Maintenance of Certification (MOC) program. Participants will earn MOC points equivalent to the amount of CME credits claimed for the activity. It is the CME activity provider's responsibility to submit participant completion information to ACCME for the purpose of granting ABIM MOC credit.

All other clinicians completing this activity will be issued a certificate of participation. To participate in this journal CME activity: (1) review the learning objectives and author disclosures; (2) study the education content; (3) take the post-test with a 75% minimum passing score and complete the evaluation at https://www.medscape.org/journal/eid; and (4) view/print certificate.

Release date: October 13, 2021; Expiration date: October 13, 2022

Learning Objectives

Upon completion of this activity, participants will be able to:

- Assess donor-derived ehrlichiosis and anaplasmosis cases in the United States among solid organ transplant recipients, based on a case series, review of Centers for Disease Control and Prevention (CDC) investigations, and literature review
- Evaluate donor-derived ehrlichiosis and anaplasmosis cases in the United States among transfusion recipients, based on a case series, review of CDC investigations, and literature review
- Determine the clinical implications of donor-derived ehrlichiosis and anaplasmosis cases in the United States among solid organ transplant and transfusion recipients, based on a case series, review of CDC investigations, and literature review

CME Editor

Tony Pearson-Clarke, MS, Technical Writer/Editor, Emerging Infectious Diseases. *Disclosure: Tony Pearson-Clarke, MS, has disclosed no relevant financial relationships.*

CME Author

Laurie Barclay, MD, freelance writer and reviewer, Medscape, LLC. *Disclosure: Laurie Barclay, MD, has disclosed no relevant financial relationships.*

Authors

Disclosures: ***Sanjida J. Mowla, MPH; Naomi A. Drexler, MPH, DrPH; Cara C. Cherry, DVM; Pallavi Annambholta, DrPH; Ian T. Kracalik, PhD;*** *and* ***Sridhar V. Basavaraju, MD,*** *have disclosed no relevant financial relationships.*

Author affiliations: Oak Ridge Institute for Science and Education, Oak Ridge, Tennessee, USA (S.J. Mowla); Centers for Disease Control and Prevention, Atlanta, Georgia, USA (S.J. Mowla, N.A. Drexler, C.C. Cherry, P.D. Annambholta, I.T. Kracalik, S.V. Basavaraju)

DOI: https://doi.org/10.3201/eid2711.211127

Ehrlichiosis and anaplasmosis are emerging tickborne diseases that can also be transmitted through blood transfusions or organ transplants. Since 2000, ehrlichiosis and anaplasmosis cases in the United States have increased substantially, resulting in potential risk to transplant and transfusion recipients. We reviewed ehrlichiosis and anaplasmosis cases among blood transfusion and solid organ transplant recipients in the United States from peer-reviewed literature and Centers for Disease Control and Prevention investigations. We identified 132 cases during 1997–2020, 12 transfusion-associated cases and 120 cases in transplant recipients; 8 cases were donor-derived, and in 13 cases illness occurred <1 year after transplant. Disease in the remaining 99 cases occurred ≥1 year after transplant, suggesting donor-derived disease was unlikely. Severe illness or death were reported among 15 transfusion and transplant recipients. Clinicians should be alert for these possible infections among transfusion and transplant recipients to prevent severe complications or death by quickly treating them.

Ehrlichiosis and anaplasmosis are emerging tickborne diseases caused by *Ehrlichia* and *Anaplasma* spp. obligate intracellular bacteria (*1*,*2*). Tick bites are the primary route of infection, but transmission can also occur through blood transfusion or solid organ transplantation, because these pathogens infect leukocytes and circulate throughout the blood stream (*2*). In the United States, human ehrlichiosis is caused primarily by *Ehrlichia chaffeensis* but can also result from *E. ewingii* or *E. muris eauclairensis* infections (*1*,*3*). Anaplasmosis is caused by *Anaplasma phagocytophilum* (*1*). Although distinct diseases, ehrlichiosis and anaplasmosis share clinical and laboratory features. Early symptoms often include fever, chills, headache, malaise, myalgia, or nausea, and many infections go unrecognized and undiagnosed (*3*–*5*). Laboratory features often include leukopenia, thrombocytopenia, anemia, and elevated hepatic transaminases (*3*–*5*).

Both diseases have incubation periods of 5–14 days from the time of tick transmission, and during early illness infected asymptomatic persons or those with mild illness might be unknowingly accepted as blood donors (*3*,*5*). In general, higher rates of ehrlichiosis and anaplasmosis are reported among adults >40 years of age, and most patients are men (*5*–*7*). Illness onset is most commonly reported during June and July, corresponding to peak tick activity (*3*,*5*). Approximately half of ehrlichiosis and anaplasmosis patients require hospitalization, and 7% require critical care (*3*,*8*). Case-fatality rates are ≈1% for *E. chaffeensis* ehrlichiosis and 0.3% for anaplasmosis patients based on national surveillance reports (*3*,*5*). In part because of immunosuppressive therapies to prevent organ rejection, transplant and transfusion recipients may be more susceptible to ehrlichiosis and anaplasmosis. Relative risk (RR) for severe outcomes among immunosuppressed compared with immunocompetent case-patients was higher for hospitalization (RR 1.4), life-threatening complications (RR 2.4), and death (RR 2.3), highlighting the potential severity of disease in immunocompromised populations (*3*,*9*–*15*).

In the United States, ehrlichiosis was first reported in 1987 and anaplasmosis in 1994, and both became nationally notifiable diseases in 1999 (*3*,*5*,*16*,*17*). Since 2000, reported cases of ehrlichiosis and anaplasmosis in the United States have increased substantially. Reported *E. chaffeensis* ehrlichiosis cases have increased >10-fold, from 200 in 2000 to 2,093 in 2019 (*18*,*19*). Reported anaplasmosis cases increased >16-fold, from 348 cases in 2000 to 5,655 in 2019 (*19*,*20*).

Increasing rates of reported ehrlichiosis and anaplasmosis might be related to several factors, including improved diagnostics, changes in reporting practices, and expanded human contact with animal reservoirs and tick vectors (*2*,*3*,*21*,*22*). *E. chaffeensis* and *E. ewingii* are primarily transmitted by the lone star tick (*Amblyomma americanum*); *A. phagocytophilum* is transmitted by either the blacklegged tick (*Ixodes scapularis*) or the western blacklegged tick (*I. pacificus*) (*3*,*5*). *E. muris eauclaurensis* is transmitted by *I. scapularis* ticks. *E. chaffeensis* ehrlichiosis is most frequently reported in the southeastern and south-central regions of the United States, and anaplasmosis is most often reported in the upper midwestern and northeastern regions.

PCR and serologic testing using an indirect immunofluorescence antibody assay are the primary laboratory methods for diagnosing ehrlichiosis and anaplasmosis (*3*,*5*). Because infection transmitted through blood or organs is rare, it might not be diagnosed in solid organ transplant and transfusion recipients. In addition, nonspecific signs and symptoms and a higher index of suspicion for other opportunistic infections might complicate diagnosis (*14*), which is unfortunate because early detection and treatment can prevent severe illness and death (*23*). Here, we summarize and discuss the risks of ehrlichiosis and anaplasmosis cases in the United States among solid organ transplant and transfusion recipients, with a focus on donor-derived infections.

Methods

We conducted a literature search to identify articles published during January–August 2020 describing ehrlichiosis and anaplasmosis in solid organ

transplant or blood transfusion recipients in the United States. We used PubMed search terms "ehrlichiosis AND transfusion," "ehrlichiosis AND transplant," "anaplasmosis AND transfusion," and "anaplasmosis AND transplant." We included articles describing case reports, case series, or other clinical descriptions related to *Ehrlichia* and *Anaplasma* spp. infections in the setting of solid organ transplantation or transfusion of blood products in the United States. We excluded infections in hematopoietic stem cell recipients because these are not reported to a national notifiable disease system. For articles meeting inclusion criteria, we further reviewed references to identify any case reports or case descriptions not found in the initial PubMed search. Duplicate cases were only counted once for this review. We summarized transplant- and transfusion-associated cases as presented in the literature; we made no additional exclusions based on diagnostic criteria, and we only determined cases to be donor-derived if the authors presented them as such in the literature or investigations.

In the United States, all suspected or confirmed cases of donor-derived diseases are reported to the Organ Procurement and Transplantation Network and are investigated by the Disease Transmission Advisory Committee (DTAC). Nationally notifiable diseases such as ehrlichiosis and anaplasmosis are referred to the Centers for Disease Control and Prevention (CDC) for investigation and determination of whether the infection was transmitted from a donor to a recipient. We also included cases of transplant-associated ehrlichiosis and anaplasmosis identified as part of these DTAC investigations by CDC if not already accounted for in the peer-reviewed literature (Figure 1). From each reviewed article or CDC-led case investigation, we collected available information on geographic region, recipient characteristics, *Ehrlichia* or *Anaplasma* species, transmission route, age of blood component transfused or type of organ transplanted, time between transplantation and infection, symptoms and clinical details, diagnostic methods, donor and recipient histories of tick exposure, donor characteristics, likely source of infection, and whether the recipient survived or died.

Results

Ehrlichiosis and Anaplasmosis Cases Reported among Transfusion Recipients

During the 1997–2020 investigation period, 12 cases of transfusion-transmitted ehrlichiosis or anaplasmosis were reported in the United States (Appendix Table 1,

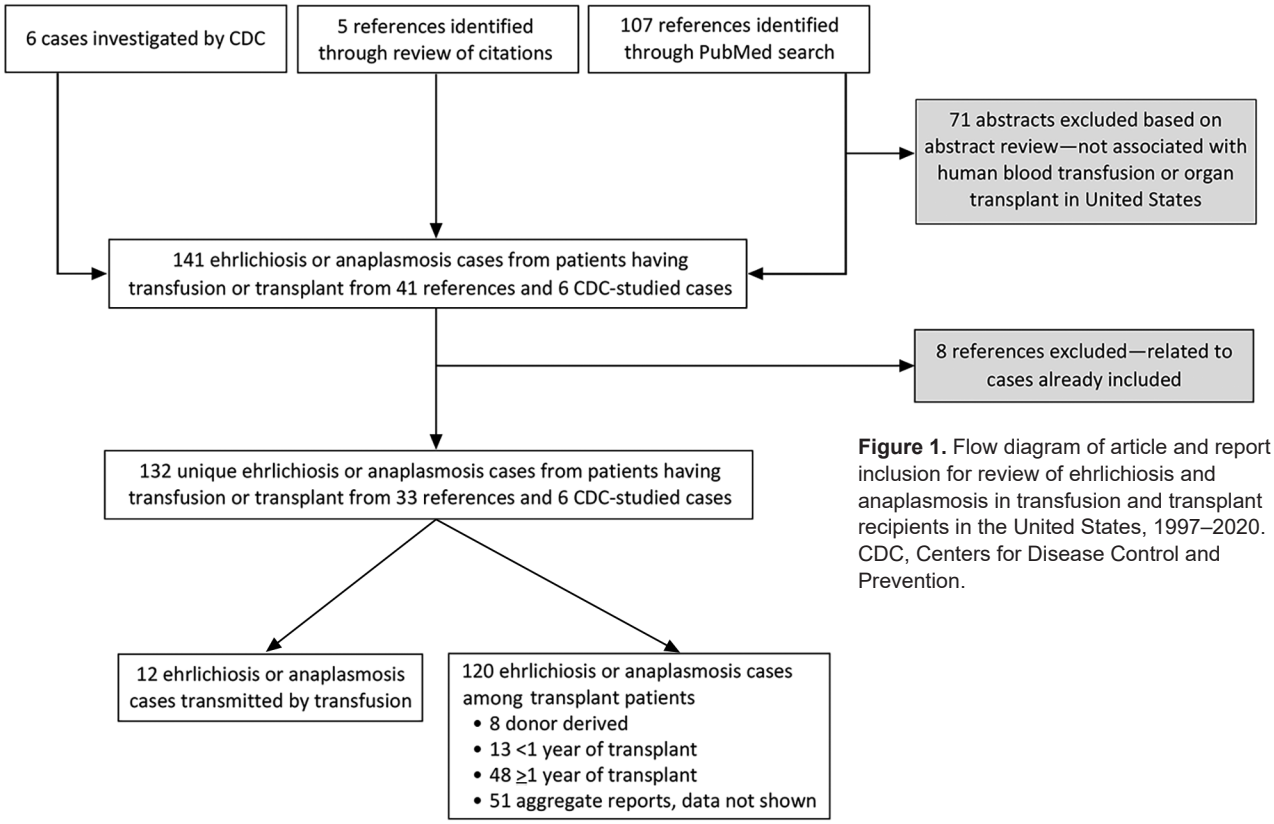

Figure 1. Flow diagram of article and report inclusion for review of ehrlichiosis and anaplasmosis in transfusion and transplant recipients in the United States, 1997–2020. CDC, Centers for Disease Control and Prevention.

https://wwwnc.cdc.gov/EID/article/27/11/21-1127-App1.pdf). Of the 12 transfusion-transmitted cases, 8 resulted from transfused red blood cell components and 3 from transfused platelet components (2 apheresis and 1 whole blood–derived); the component for 1 case was not identified. Ten (83.3%) of 12 transfusion-associated cases were *A. phagocytophilum* infections; 1 case was associated with *E. ewingii* and 1 with *E. chaffeensis* (Figure 2, panels C, D). Median age of transfusion recipients was 66 years (range 9–85 years); sex was equally distributed. Of the transfusion-associated cases of ehrlichiosis and anaplasmosis, 3 occurred in Minnesota; 2 in Wisconsin; and 1 each in Georgia, Rhode Island, Connecticut, Massachusetts, New York, and Oklahoma (Figure 2, panels A, B). Disease in all cases was diagnosed using PCR, and additional serologic testing was used for 2 cases. Most (83.3%) transfusion case-patients survived infection; one third of cases were associated with mild symptoms. Intensive care unit (ICU) treatment was noted for 2 anaplasmosis patients, prompted by respiratory failure, hypotension, and hypoxia. In addition, 3 anaplasmosis patients had multisystem organ failure, but ICU treatment was not mentioned for these cases. Two patients died, one from anaplasmosis and the other from other medical complications.

Ehrlichiosis and Anaplasmosis Cases Reported among Solid Organ Transplant Recipients

During the investigation period, 107 cases of ehrlichiosis and 7 cases of anaplasmosis were described in the literature among solid organ transplant recipients. Of these, 63 included patient-specific information. We described the remaining 51 cases in aggregate and reported on them separately. An additional 6 cases of ehrlichiosis among solid organ transplant recipients were investigated by CDC, resulting in a total of 120 cases of ehrlichiosis or anaplasmosis described among transplant recipients during the investigation period.

E. chaffeensis ehrlichiosis was the most common organ donor-derived infection, reported among 8 solid organ transplant recipients: 2 cases we identified from the literature and the 6 investigated by CDC (Appendix Table 2). Of these, 7 (87.5%) case-patients were kidney transplant recipients and 1 was a liver transplant recipient. Fever was reported among all solid organ transplant recipients. Diagnostic methods were PCR (87.5%) and serologic testing (12.5%). Most (87.5%) patients were male, median age was 57 years (range 5–69 years), and median time between transplantation and infection was 13.5 days (range 10–25 days). Of the donor-derived ehrlichiosis cases, 2 occurred in Maryland; 3 in Missouri; and 1 each in New York, New Jersey, and Illinois (Figure 2, panel E). Among the 8 donor-derived ehrlichiosis cases, 2 deaths were reported among the kidney transplant recipients, both occurring <1 month after transplantation (Appendix Table 3). None of the confirmed transplant-derived case reports described ICU admission among the patients.

Thirteen cases of ehrlichiosis and anaplasmosis occurred <1 year after transplantation but could not be confirmed as donor-derived. The median time between transplantation and symptom onset in these 13 cases was 5 months (range 2 weeks–9 months) (Table 4). Of those cases, 4 were identified in Tennessee (Figure 2, panel F). *E. chaffeensis* infection was associated with 11 (84.6%) cases, and *A. phagocytophilum* infection was associated with 2 (15.4%) cases. Of the 13 cases, 5 (38.5%) occurred in kidney recipients, 4 (30.8%) in heart recipients, 2 (15.4%) in kidney and pancreas recipients, and 1 (7.7%) in a liver and lung recipient. Most (76.9%) patients were male, median age was 50 years (range 35–63 years), and PCR was the most common (76.9%) diagnostic method. Most (92.3%) patients infected <1 year after transplantation survived; however, 1 kidney and pancreas recipient with *A. phagocytophilum* infection died.

Forty-eight records of individual cases of ehrlichiosis or anaplasmosis that occurred ≥1 year after transplant were most likely attributable to posttransplant infections acquired through tick bites (Table 5). Median time from transplant to symptom onset was 6 years (range 1–21 years), most patients (75.0%) were male, and median age was 51 years (range 11–73 years). Among these patients, records described *Ehrlichia* infection for 43 (89.6%) and *Anaplasma* infection for 5 (10.4%). *E. chaffeensis* was implicated in 30 (69.8%) of 43 cases of ehrlichiosis, *E. ewingii* in 12 (27.9%), and an unspecified *Ehrlichia* sp. in 1 (2.3%). Twenty-three patients (53.5%) received kidneys, 8 (18.6%) livers, 7 (16.3%) lungs, 4 (9.3%) hearts, and 1 (2.3%) a pancreas. Of the 5 reported cases of anaplasmosis occurring ≥1 year after transplant, 4 (80.0%) occurred in kidney recipients and 1 (20.0%) in a liver recipient. Among the 43 cases of ehrlichiosis in solid organ transplant recipients who had illness onset ≥1 year after transplant, 26 (60.6%) occurred in Missouri and 12 (27.9%) in Tennessee; exact location was not specified in 1 report, but the case occurred in Alabama, Tennessee, or Mississippi. Among the 5 cases of anaplasmosis, 2 occurred in Minnesota, 1 in Maine, 1 in Wisconsin, and 1 in Connecticut. One patient had possible reactivation of a previous *Anaplasma* infection secondary to potent immunosuppression 9 months after the

original infection. There were 2 reports of *Ehrlichia* reinfection that described distinct strains of *E. chaffeensis* and *E. ewingii* found in a secondary infection. Secondary hemophagocytic lymphohistiocytosis, which is characterized by severe and potentially fatal inflammation, developed in 1 kidney transplant recipient. Of the solid organ transplant recipients with ehrlichiosis or anaplasmosis occurring ≥1 year after transplant, 47 (97.9%) of 48 survived. One pancreas recipient with an *E. chaffeensis* infection died. Seven cases occurring ≥1 year of solid organ transplantation did report ICU admission, possibly relating to long-term immunosuppression among transplant recipients.

Of the 51 cases of ehrlichiosis from Missouri for which we report data in aggregate, 18 (35.3%) occurred in kidney recipients, 12 (23.5%) in heart recipients, 12

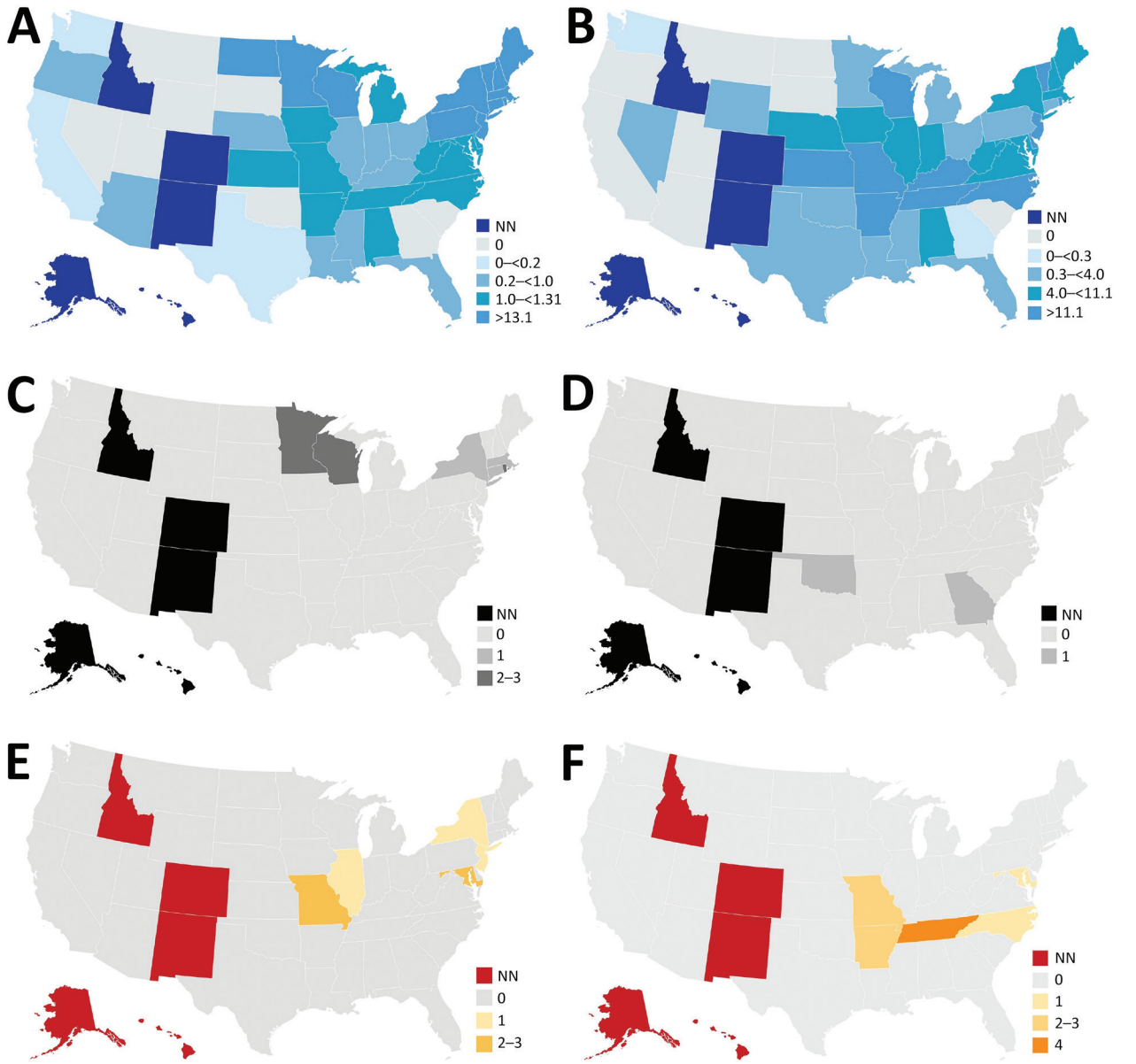

Figure 2. Incidence of ehrlichiosis and anaplasmosis in the United States, 2019, and of cases among transfusion and transplant recipients, 1997–2020. A) Incidence of anaplasmosis per 1 million US residents in 2019. B) Incidence of ehrlichiosis per 1 million US residents in 2019. C) Transfusion-transmitted anaplasmosis cases by recipient state of residence. D) Transfusion-transmitted ehrlichiosis cases by recipient state of residence. E) Organ donor–derived ehrlichiosis cases by recipient state of residence. We identified no organ donor–derived anaplasmosis cases. F) Organ donor–derived ehrlichiosis cases with onset <1 year after transplant by recipient state of residence. We identified 2 additional donor-derived ehrlichiosis cases with onset <1 year after transplant; however, recipient state of residence was unknown. NN, not notifiable.

(23.5%) in lung recipients, 7 (13.7%) in liver recipients, and 2 (4.0%) in kidney-pancreas recipients. Additional information on disease, pathogen species, and demographics was not available for these 51 cases.

Discussion

This study reviewed ehrlichiosis and anaplasmosis cases among transfusion and solid organ transplant recipients described in published literature and reports from 6 CDC investigations. During the study period, 12 cases of transfusion-transmitted ehrlichiosis or anaplasmosis were reported, 2 of which resulted in death. In addition, 8 cases of organ donor–derived ehrlichiosis were reported (7 kidney transplant recipients and 1 liver recipient), 2 of which resulted in death. *A. phagocytophilum* was the most common causative agent among transfusion-derived infections. In contrast, among transplant recipients, *E. chaffeensis* was the most common causative agent. Donor-derived infections were observed among patients of a broad range of ages (5–85 years). Although children are not considered a high-risk group for anaplasmosis in particular, pediatric infection should not be discounted among transfusion and transplant recipients. Time from transplant or transfusion to the development of signs and symptoms varied widely and in most cases was longer than the typical incubation period for a tick-transmitted infection. Delays in symptom onset might be affected by the colony size and the site of the inoculated bacteria. Transfusion- or transplant-transmitted ehrlichiosis and anaplasmosis are rare but can result in severe outcomes including the death of the recipient.

Although known cases of transfusion- and transplant-transmitted ehrlichiosis or anaplasmosis are uncommon, studies of asymptomatic infection among blood donors and the survivability of infection in blood suggest the risk of transmission is greater than previously recognized. In endemic areas, seroprevalence studies found 11.3% of blood donors in New York, 0.5% in Wisconsin, and 3.5% in Connecticut had detectable antibodies against *A. phagocytophilum* (*24*,*25*). In Iowa, ≈1% of blood donors studied were seropositive for and displayed symptoms of ehrlichiosis after blood donation, although recipient lookback reported by physicians indicated that these transfusions did not result in transfusion-transmitted illnesses (*26*). However, serosurveys do not report active or incident infections, only the proportion of participants previously exposed to an *Ehrlichia* or *Anaplasma* agent. Some studies also examined the survivability of *Ehrlichia* and *Anaplasma* species in donor blood. Blood from anaplasmosis patients in 2 studies found viable *A. phagocytophilum* survived under refrigerated storage conditions for up to 18 days in whole blood (*27*,*28*). One in vitro study reported *E. chaffeensis* remained viable for up to 11 days within refrigerated packed red blood cells (*29*).

Donor-derived ehrlichiosis and anaplasmosis highlight the importance of donor risk mitigation strategies in the setting of blood transfusion and solid organ transplantation and the potential role of laboratory-based screening. Recognizing and diagnosing tickborne diseases is complicated by long incubation periods and potential asymptomatic or mildly symptomatic infections. Although several laboratory tests are used to diagnose ehrlichiosis and anaplasmosis, no tests have been approved by the US Food and Drug Administration (FDA) to screen blood or organ donors for these diseases. Furthermore, serologic screening of donors might not identify active *Ehrlichia* or *Anaplasma* infections or could exclude healthy donors (*28*). PCR testing would more accurately screen contaminated blood and organ products, but no FDA-licensed test is available. Donor deferral on the basis of travel or residence would be impractically broad because of the widespread endemicity of ehrlichiosis and anaplasmosis across regions of the United States. To minimize blood supply disruptions based on travel deferrals for Zika virus and babesia, FDA previously recommended universal antibody testing and regional nucleic acid testing in states with the highest rates of risk for infection (*30*,*31*). Similar screening may eventually be necessary for ehrlichiosis and anaplasmosis as the prevalence and incidence of these infections increases in the United States. CDC will continue to monitor the occurrence of transfusion- or transplant-transmitted ehrlichiosis and anaplasmosis.

Among this study's limitations, for sources identified through the literature we were limited to the information provided in the case reports, which might not always have represented a full account of the patient experience. Data on donor demographics were extremely limited. Donor state of residence might have provided a more accurate insight on likelihood of donor infection by state which might have broader implications for blood and organ screening criteria. Next, for the purposes of this evaluation, we relied on the characterizations by the original authors or investigators to categorize cases as donor- or transplant-derived ehrlichiosis or anaplasmosis. Finally, we included only cases published in peer-reviewed literature or reported to CDC, possibly underreporting transfusion- and transplant-associated infections. In 2019, the Rickettsial Zoonoses Branch,

Division of Vector-Borne Diseases, National Center for Emerging and Zoonotic Infectious Diseases, CDC, added questions relating to recent transfusion and organ transplant to their tickborne rickettsial disease surveillance system (https://www.cdc.gov/ticks/forms/Tick_TBRD_FILL_508.pdf) to better track donor-derived infections.

Because *Ehrlichia* and *Anaplasma* species primarily infect leukocytes, leukoreduction has been presumed to reduce risk for ehrlichiosis and anaplasmosis through passive removal (*23*,*32*,*33*). However, 83% (10/12) of components implicated in transfusion-transmitted cases in this study were leukoreduced. In cell culture models, because of their presence in plasma also, *E. chaffeensis* survived in red blood cells stored in additive solution, suggesting leukoreduction alone will not prevent transmission of *Ehrlichia* and *Anaplasma* species (*29*). Adopting pathogen reduction technology, such as psoralen and ultraviolet light to inactivate infectious agents, for platelet and plasma products would provide additional safety measures to reduce risk for transfusion-transmitted *Ehrlichia* and *Anaplasma* infections. Pathogen-reduced plasma has demonstrated a ≥3.6-log reduction in viable *A. phagocytophilum* (*34*). However, this method has not been approved for red blood cell products, which were implicated in 8 of 12 cases of transfusion-transmitted ehrlichiosis and anaplasmosis in this study.

Identifying risk factors for *Ehrlichia* and *Anaplasma* infections among deceased organ donors is challenging because clinical, demographic, and social information about deceased donors is often obtained from family members, who might not have access to or recall all historical details (*35*). Also, routine laboratory screening of organ donors, required for multiple infectious diseases, including HIV/AIDS, does not yet include testing for infection with *Ehrlichia* and *Anaplasma* species. In addition, the number of posttransplant infections reported in this review highlights the risk among blood product or organ recipients. Therefore, clinicians must closely monitor recipients of blood transfusions or solid organs during long-term management and consider these pathogens when recipients develop signs or symptoms of infection. Because the prevalence of tickborne disease infections is rising, additional risk mitigation interventions will likely be necessary to enhance blood and organ safety.

Acknowledgments

We thank Paige Armstrong for her contributions to preparing this manuscript.

Organ Procurement and Transplantation Network data provided for this report was supported in part by the US Health Resources and Services Administration (https://www.hrsa.gov).

About the Author

Ms. Mowla is an ORISE fellow in the Office of Blood, Organ, and Other Tissue Safety, Division of Healthcare Quality Promotion, National Center for Emerging and Zoonotic Infectious Diseases, CDC, in Atlanta. Her primary research interests are transfusion- and transplant-transmitted infections.

References

1 Vannorsdall MD, Thomas S, Smith RP, Zimmerman R, Christman R, Vella JP, et al. Human granulocytic ehrlichiosis in a renal allograft recipient: review of the clinical spectrum of disease in solid organ transplant patients. Transpl Infect Dis. 2002;4:97–101. https://doi.org/10.1034/j.1399-3062.2002.01015.x

2. Ismail N, Bloch KC, McBride JW. Human ehrlichiosis and anaplasmosis. Clin Lab Med. 2010;30:261–92. https://doi.org/10.1016/j.cll.2009.10.004

3. Nichols Heitman K, Dahlgren FS, Drexler NA, Massung RF, Behravesh CB. Increasing incidence of ehrlichiosis in the United States: a summary of national surveillance of *Ehrlichia chaffeensis* and *Ehrlichia ewingii* infections in the United States, 2008–2012. Am J Trop Med Hyg. 2016;94:52–60. https://doi.org/10.4269/ajtmh.15-0540

4. Bakken JS, Dumler JS. Human granulocytic anaplasmosis. Infect Dis Clin North Am. 2015;29:341–55. https://doi.org/10.1016/j.idc.2015.02.007

5. Dahlgren FS, Heitman KN, Drexler NA, Massung RF, Behravesh CB. Human granulocytic anaplasmosis in the United States from 2008 to 2012: a summary of national surveillance data. Am J Trop Med Hyg. 2015;93:66–72. https://doi.org/10.4269/ajtmh.15-0122

6. Fishbein DB, Dawson JE, Robinson LE. Human ehrlichiosis in the United States, 1985 to 1990. Ann Intern Med. 1994;120:736–43. https://doi.org/10.7326/0003-4819-120-9-199405010-00003

7. Paddock CD, Childs JE. *Ehrlichia chaffeensis*: a prototypical emerging pathogen. Clin Microbiol Rev. 2003;16:37–64. https://doi.org/10.1128/CMR.16.1.37-64.2003

8. Dumler JS. *Anaplasma* and *Ehrlichia* infection. Ann N Y Acad Sci. 2005;1063:361–73. https://doi.org/10.1196/annals.1355.069

9. Alhumaidan H, Westley B, Esteva C, Berardi V, Young C, Sweeney J. Transfusion-transmitted anaplasmosis from leukoreduced red blood cells. Transfusion. 2013;53:181–6. https://doi.org/10.1111/j.1537-2995.2012.03685.x

10. Cotant C, Okulicz JF, Brezina B, Riley DJ, Conger NG. Human monocytic ehrlichiosis in a renal transplant patient. Scand J Infect Dis. 2006;38:699–702. https://doi.org/10.1080/00365540500444694

11. Fine AB, Sweeney JD, Nixon CP, Knoll BM. Transfusion-transmitted anaplasmosis from a leukoreduced platelet pool. Transfusion. 2016;56:699–704. https://doi.org/10.1111/trf.13392
12. Goel R, Westblade LF, Kessler DA, Sfeir M, Slavinski S, Backenson B, et al. Death from transfusion-transmitted anaplasmosis, New York, USA, 2017. [Erratum in Emerg Infect Dis. 2018;24:1773.]. Emerg Infect Dis. 2018;24:1548–50. https://doi.org/10.3201/eid2408.172048
13. Sachdev SH, Joshi V, Cox ER, Amoroso A, Palekar S. Severe life-threatening *Ehrlichia chaffeensis* infections transmitted through solid organ transplantation. Transpl Infect Dis. 2014;16:119–24. https://doi.org/10.1111/tid.12172
14. Safdar N, Love RB, Maki DG. Severe *Ehrlichia chaffeensis* infection in a lung transplant recipient: a review of ehrlichiosis in the immunocompromised patient. Emerg Infect Dis. 2002;8:320–3. https://doi.org/10.3201/eid0803.010249
15. Trofe J, Reddy KS, Stratta RJ, Flax SD, Somerville KT, Alloway RR, et al. Human granulocytic ehrlichiosis in pancreas transplant recipients. Transpl Infect Dis. 2001; 3:34–9. https://doi.org/10.1034/j.1399-3062.2001.003001034.x
16. Chen SM, Dumler JS, Bakken JS, Walker DH. Identification of a granulocytotropic *Ehrlichia* species as the etiologic agent of human disease. J Clin Microbiol. 1994;32:589–95. https://doi.org/10.1128/jcm.32.3.589-595.1994
17. Maeda K, Markowitz N, Hawley RC, Ristic M, Cox D, McDade JE. Human infection with *Ehrlichia canis*, a leukocytic rickettsia. N Engl J Med. 1987;316:853–6. https://doi.org/10.1056/NEJM198704023161406
18. CDC. Ehrlichiosis: epidemiology and statistics [cited 2021 June 23]. https://www.cdc.gov/ehrlichiosis/stats/index.html
19. CDC. Nationally notifiable infectious diseases and conditions, United States: annual tables [cited 2021 June 23]. https://wonder.cdc.gov/nndss/static/2019/annual/2019-table2f.html
20. CDC. Anaplasmosis: epidemiology and statistics [cited 2021 June 23]. https://www.cdc.gov/anaplasmosis/stats/index.html
21. Dahlgren FS, Mandel EJ, Krebs JW, Massung RF, McQuiston JH. Increasing incidence of *Ehrlichia chaffeensis* and *Anaplasma phagocytophilum* in the United States, 2000–2007. Am J Trop Med Hyg. 2011;85:124–31. https://doi.org/10.4269/ajtmh.2011.10-0613
22. Springer YP, Eisen L, Beati L, James AM, Eisen RJ. Spatial distribution of counties in the continental United States with records of occurrence of *Amblyomma americanum* (Ixodida: Ixodidae). J Med Entomol. 2014;51:342–51. https://doi.org/10.1603/ME13115
23. Biggs HM, Behravesh CB, Bradley KK, Dahlgren FS, Drexler NA, Dumler JS, et al. Diagnosis and management of tickborne rickettsial diseases: Rocky Mountain spotted fever and other spotted fever group rickettsioses, ehrlichioses, and anaplasmosis—United States. A practical guide for health care and public health professionals. MMWR Recomm Rep. 2016;65:1–44. https://doi.org/10.15585/mmwr.rr6502a1
24. Aguero-Rosenfeld ME, Donnarumma L, Zentmaier L, Jacob J, Frey M, Noto R, et al. Seroprevalence of antibodies that react with *Anaplasma phagocytophila*, the agent of human granulocytic ehrlichiosis, in different populations in Westchester County, New York. J Clin Microbiol. 2002; 40:2612–5. https://doi.org/10.1128/JCM.40.7.2612-2615.2002
25. Leiby DA, Chung AP, Cable RG, Trouern-Trend J, McCullough J, Homer MJ, et al. Relationship between tick bites and the seroprevalence of *Babesia microti* and *Anaplasma phagocytophila* (previously *Ehrlichia* sp.) in blood donors. Transfusion. 2002;42:1585–91. https://doi.org/10.1046/j.1537-2995.2002.00251.x
26. Arguin PM, Singleton J, Rotz LD, Marston E, Treadwell TA, Slater K, et al. An investigation into the possibility of transmission of tick-borne pathogens via blood transfusion. Transfusion-Associated Tick-Borne Illness Task Force. Transfusion. 1999;39:828–33. https://doi.org/10.1046/j.1537-2995.1999.39080828.x
27. Kalantarpour F, Chowdhury I, Wormser GP, Aguero-Rosenfeld ME. Survival of the human granulocytic ehrlichiosis agent under refrigeration conditions. J Clin Microbiol. 2000;38:2398–9. https://doi.org/10.1128/JCM.38.6.2398-2399.2000
28. McQuiston JH, Childs JE, Chamberland ME, Tabor E. Transmission of tick-borne agents of disease by blood transfusion: a review of known and potential risks in the United States. [Erratum in Transfusion. 2000;40:891.] Transfusion. 2000;40:274–84. https://doi.org/10.1046/j.1537-2995.2000.40030274.x
29. McKechnie DB, Slater KS, Childs JE, Massung RF, Paddock CD. Survival of *Ehrlichia chaffeensis* in refrigerated, ADSOL-treated RBCs. Transfusion. 2000;40:1041–7. https://doi.org/10.1046/j.1537-2995.2000.40091041.x
30. Food and Drug Administration. Recommendations for reducing the risk of transfusion-transmitted babesiosis [cited on 2021 June 23]. https://www.fda.gov/media/114847/download
31. Food and Drug Administration. Information for blood establishments regarding FDA's determination that Zika virus is no longer a relevant transfusion-transmitted infection [cited 2021 September 7]. https://www.fda.gov/vaccines-blood-biologics/blood-blood-products/information-blood-establishments-regarding-fdas-determination-zika-virus-no-longer-relevant
32. Annen K, Friedman K, Eshoa C, Horowitz M, Gottschall J, Straus T. Two cases of transfusion-transmitted *Anaplasma phagocytophilum*. Am J Clin Pathol. 2012;137:562–5. https://doi.org/10.1309/AJCP4E4VQQQOZIAQ
33. Proctor MC, Leiby DA. Do leukoreduction filters passively reduce the transmission risk of human granulocytic anaplasmosis? Transfusion. 2015;55:1242–8. https://doi.org/10.1111/trf.12976
34. Food and Drug Administration. INTERCEPT blood system for cryoprecipitation package insert for the manufacturing of pathogen reduced plasma, cryoprecipitate reduced [cited on 2021 June 23]. https://www.fda.gov/media/90594/download
35. Vora NM, Basavaraju SV, Feldman KA, Paddock CD, Orciari L, Gitterman S, et al.; Transplant-Associated Rabies Virus Transmission Investigation Team. Raccoon rabies virus variant transmission through solid organ transplantation. JAMA. 2013;310:398–407. https://doi.org/10.1001/jama.2013.7986

Address for correspondence: Sridhar V. Basavaraju, Centers for Disease Control and Prevention, 1600 Clifton Rd NE, Mailstop V18-4, Atlanta, GA 30329-4027, USA; email: smowla1@uga.edu

Article DOI: https://doi.org/10.3201/eid2711.211127

Ehrlichiosis and Anaplasmosis among Transfusion and Transplant Recipients in the United States

Appendix

Table 1. Characteristics of transfusion-transmitted ehrlichiosis and anaplasmosis described in the published literature

Author, year	Recipient US state of residence	Donor US state of residence	Recipient sex/age, y	Donor age, y	Genus and species†	Transmission route	Age of organ	Symptoms/clinical details	Method of diagnosis	Recipient outcome
Eastlund, 1999	Minnesota	NA	M/75	NA	*A. phagocytophilum*	Non–LR RBC transfusion	30 d	Fever, rigors, nausea, vomiting	PCR, serology	Survived
Kemperman, 2008	Minnesota	Minnesota	M/68	64	*A. phagocytophilum*	Non–LR RBC transfusion	16 d	Thrombocytopenia, sepsis, multisystem organ failure, hypotension and fever	PCR	Survived
Bachowski, 2008	Minnesota	Minnesota	F/85	81	*A. phagocytophilum*	LR RBC	29 d	NA	PCR	Unknown
Annen, 2012	Wisconsin	Wisconsin	F/81	53	*A. phagocytophilum*	LR RBC transfusion	NA	Fever, myalgias, and pancytopenia, multiorgan failure,	PCR	Survived
Annen, 2012	Wisconsin	Wisconsin	F/51	NA	*A. phagocytophilum*	LR IR RBC transfusion	NA	Fever, fatigue, tachycardia, leukopenia, thrombocytopenia	PCR	Survived
Regan, 2013	Georgia	Florida	M/9	NA	*E. ewingii*	LR IR apheresis platelet transfusion	5 d	Fever, fatigue, malaise, vomiting, diarrhea, and petechial rash, neutropenia, thrombocytopenia, and elevated liver enzymes	PCR	Survived
Alhumaiden, 2013	Rhode Island	Rhode Island	M/64	81	*A. phagocytophilum*	LR RBC transfusion	12 d	Headache, fever, and chills, dyspnea, dry cough, leukopenia, transferred to ICU for respiratory failure	PCR	Survived
Townsend, 2014	Connecticut	New York	M/41	53	*A. phagocytophilum*	LR apheresis platelet transfusion	5 d	NA	PCR	Died from other complications
Shields, 2015	Massachusetts	Massachusetts or New Hampshire	F/34	NA	*A. phagocytophilum*	LR IR RBC transfusion	9 d	Nausea, fevers, myalgia, leukopenia, thrombocytopenia	PCR	Survived
Fine, 2015	Rhode Island	NA	F/78	19	*A. phagocytophilum*	LR WBD platelet transfusion	5 d	Chills, fever, cough, leukopenia, thrombocytopenia hypotension, and hypoxia, transferred to ICU	PCR, serology	Survived
Goel, 2018	New York	New York	M/78	NA	*A. phagocytophilum*	LR IR RBC transfusion	22 d	Fever, tachycardia and hypotension, dyspnea, hypoxia, thrombocytopenia, leukopenia, and transaminitis, multiple organ failure	PCR	Died
Mah, 2018	Oklahoma	NA	F/59	NA	*E. chaffeensis*	LR RBCs and platelets	NA	Fever, pneumonitis, myocarditis, transaminitis, acute kidney injury, graft loss	PCR	Survived

*HLH, hemophagocytic lymphohistiocytosis; ICU, intensive care unit; IHC, immunohistochemistry; IR, infrared; LR, leukoreduced; NA, not available; RBC, red blood cells; SIRS, systemic inflammatory response syndrome
†Genera: *A., Anaplasma*; *E., Ehrlichia*

Table 2. Characteristics of donor-derived ehrlichiosis and anaplasmosis related to solid organ transplant recipients

Author, year†	Recipient US state of residence	Donor US state of residence	Recipient sex/age, y	Donor age, y	Organ	Donor characteristics	Genus and species*	Time, transplant to symptoms	Symptoms/clinical details	Method of diagnosis	Recipient outcome
Sachdev, 2014	Maryland	Maryland	F/57	54	Kidney	Deceased	*E. chaffeensis*	22 d	Fever, pancytopenia, pleural effusion, renal dysfunction	PCR	Survived
Sachdev, 2014	Maryland	Maryland	M/56	54	Kidney	Deceased	*E. chaffeensis*	25 d	Fever, lethargy, thrombocytopenia, anemia, features of TTP-HUS, acute anuric kidney failure	Serology	Survived
CDC†, 2019	Missouri	Kansas	M/17	38	Kidney	Living	*E. chaffeensis*	16 d	Fever	PCR	Survived
CDC†, 2020	New Jersey	Delaware	M/70	57	Kidney	Deceased	*E. chaffeensis*	18 d	Fever, intermittent diarrhea, chills, mild cough, fatigue, chronic bilateral, lower extremity mild swelling (Right side greater than left), pancytopenia	PCR	Died
CDC†, 2020	New York	Delaware	M/66	57	Kidney	Deceased	*E. chaffeensis*	11 d	Fever, re-hospitalized and subsequently developed progressive multisystem organ failure (transplant kidney, liver, lung, brain) in the setting of pancytopenia	PCR	Died
CDC†, 2020	Missouri	Missouri	M/5	29	Kidney	Deceased	*E. chaffeensis*	10 d	Fever, pancytopenia	PCR	Survived
CDC†, 2020	Missouri	Missouri	M/5	29	Kidney	Deceased	*E. chaffeensis*	11 d	Fever, hyponatremia, dehydrations,	PCR	Survived
CDC†, 2020	Illinois	Missouri	M/69	29	Liver	Deceased	*E. chaffeensis*	11 d	Fever, headache, malaise, agitation	PCR	Survived

*Genus: *Ehrlichia*
†Centers for Disease Control and Prevention–led investigation

Table 3. Characteristics of ehrlichiosis and anaplasmosis related deaths among solid organ transplant recipients

Author, year†	Recipient US state of residence	Donor US state of residence	Recipient sex/age, y	Donor age, y	Organ	Genus and species†	Time, transplant to symptoms	Symptoms/clinical details	Method of diagnosis	Likely source of infection
Trofe, 2001	Southeastern United States	NA	M/50	NA	Kidney, Pancreas	*A. phagocytophilum*	9 mo	Weight loss, low-grade fever, and leukopenia, increases in LDH and serum creatinine	Bone marrow biopsies and peripheral blood smears	Reactivation of *Anaplasma* secondary to potent immunosuppression or possible tick exposure
Trofe, 2001	Southeastern United States	NA	F/ 41	NA	Pancreas	*E. chaffeensis*	20 mo	Allograft rejection, Fever, leukopenia, thrombocytopenia, increases in LDH and serum creatinine	Bone marrow biopsies and peripheral blood smears	Reactivation of *Ehrlichia* secondary to potent immunosuppression or possible tick exposure
CDC‡, 2020	New York	Delaware	M/66	57	Kidney	*E. chaffeensis*	11 d	Fever, re-hospitalized and subsequently developed progressive multisystem organ failure (transplant kidney, liver, lung, brain) in the setting of pancytopenia	PCR	Donor-derived
CDC‡, 2020	New Jersey	Delaware	M/70	57	Kidney	*E. chaffeensis*	18 d	Fever, intermittent diarrhea, chills, mild cough, fatigue, chronic bilateral, lower extremity mild swelling (Right side greater than left), pancytopenia	PCR	Donor-derived

Table 4. Characteristics of ehrlichiosis and anaplasmosis cases occurring within 1 year of solid organ transplantation

Author, year	Recipient state of US residence	Sex/ Age, y	Organ	Genus and species†	Time, transplant to symptoms	Symptoms/clinical details	Method of diagnosis	Tick exposure	Donor characteristics	Likely source of infection	Recipient outcome
Schutze, 1997	Arkansas	NA	Kidney	*E. chaffeensis*	6 wk	Fever	Serology; morulae seen on bone marrow	NA	Living, related	NA	Survived
Tan, 2001	Maryland	M/47	Liver	*E. chaffeensis*	8 mo	Hypotension, fever, and tachypnea, thrombocytopenia, acute cellular rejection, progressive multi-system organ failure, transferred to ICU	PCR	Yes	NA	Post-transplant infection; removed tick from skin 10 d before admission	Survived
Trofe, 2001	Alabama, Tennessee, or Mississippi	M/50	Kidney-Pancreas	*A. phagocytophilum*	9 mo	Weight loss, low-grade fever, leukopenia, rejection of the kidney and pancreas most likely due to chemotherapy	Peripheral blood smears	NA	NA	Living in heavily wooded area or reactivation secondary to potent immunosuppression	Died
Trofe, 2001	Alabama, Tennessee, or Mississippi	M/38	Kidney-Pancreas	*A. phagocytophilum*	2 mo	Fever, leukopenia, hyperglycemia, and elevated LDH, severe rejection of pancreas most likely unrelated to anaplasmosis	Bone marrow biopsy	NA	NA	Living in heavily wooded area or reactivation secondary to potent immunosuppression	Survived
Cotant, 2006	Tennessee	M/60	Kidney	*E. chaffeensis*	6 mo	Fever, weakness, leukopenia, thrombocytopenia, transferred to ICU	PCR; IHC of bone marrow	No	Deceased	Post-transplant infection	Survived
Thomas, 2007	Tennessee	M/59	Heart	*E. chaffeensis*	113 d	Fever, nausea	PCR	NA	NA	NA	Survived
Thomas, 2007	Tennessee	M/38	Heart	*E. chaffeensis*	269 d	Fever, headache, nausea, vomiting	PCR	NA	NA	NA	Survived
Thomas, 2007	Tennessee	M/54	Heart	*E. chaffeensis*	203 d	Fever, headache, nausea, vomiting, diarrhea, cough	PCR	NA	NA	NA	Survived
Lawrence, 2009	Missouri	F/58	Lung	*E. chaffeensis*	9 mo	Fever, headache	PCR	NA	NA	NA	Survived
Lawrence, 2009	Missouri	M/44	Kidney	*E. chaffeensis*	1 mo	Fever	PCR	NA	NA	NA	Survived
Lawrence, 2009	Missouri	M/63	Heart	*E. chaffeensis*	8 mo	Fever, malaise	PCR	NA	NA	NA	Survived
Masterson, 2020	North Carolina	F/35	Kidney	*E. chaffeensis*	4 mo	Fever, headache, leukopenia, thrombocytopenia	PCR	No	Deceased	Post-transplant infection	Survived
Hassan, 2020	Arkansas	M/57	Kidney	*E. chaffeensis*	2 wk	Fever, rigors, sweats, nausea, fatigue, headache, leukopenia, thrombocytopenia, transaminitis, renal dysfunction, transferred to ICU	PCR	No	Deceased	Post-transplant infection	Survived

*HLH, hemophagocytic lymphohistiocytosis; ICU, intensive care unit; IHC, immunohistochemistry; LDH, lactate dehydrogenase; NA, not available; SIRS, systemic inflammatory response syndrome
†Genera: *A., Anaplasma*; *E., Ehrlichia*

Table 5. Characteristics of ehrlichiosis and anaplasmosis cases occurring ≥1 year of solid organ transplantation*

Author, year†	Recipient state of US residence	Sex/ Age, y	Organ	Genus and species‡	Time, transplant to symptoms	Symptoms/clinical details	Method of diagnosis	Tick exposure	Donor characteristics	Likely source of infection	Recipient outcome
Antony, 1995	Kentucky	M/51	Liver	*E. chaffeensis*	6 y	Fever, leukopenia, thrombocytopenia, hypotension, monitored in ICU before therapy	Serology	Y	NA	Post-transplant infection; tick bite 2 wk before symptoms	Survived
Adachi, 1997	Minnesota	M/67	Kidney	*A. phagocytophilum*	16 mo	Fever, rigors, nausea, and myalgias, thrombocytopenia, leukopenia and anemia, hypoxemia	Peripheral smear	Y	Living	Post-transplant infection; tick bite 1 wk before symptoms	Survived
Sadikot, 1999	Arkansas	M/35	Kidney	*E. chaffeensis*	4 y	Fever, headaches, myalgia, pancytopenia, oliguric acute renal failure, transferred to ICU	PCR	Y	Deceased	Post-transplant infection, exposure to ticks 1 wk before symptoms	Survived
Buller, 1999	Missouri	M/11	Kidney	*E. ewingii*	9 y	Fever, headache, myalgia, thrombocytopenia, lymphadenopathy	PCR	Y	Living, related	Post-transplant infection mo prior	Survived
Trofe, 2001	Alabama, Tennessee, or Mississippi	F/41	Pancreas	*E. chaffeensis*	20 mo	Fever, acute respiratory decompensation, multi-system organ failure most likely unrelated to ehrlichiosis, transferred to ICU	Peripheral blood smears	NA	NA	Living in heavily wooded area; possible reactivation secondary to potent immunosuppression	Died
Vannorsdall, 2002	Maine	F/66	Kidney	*A. phagocytophilum*	21 y	Fever, thrombocytopenia, leukopenia	PCR, positive blood smear	N	Deceased	Post-transplant infection	Survived
Safdar, 2002	Missouri	M/38	Lung	*E. chaffeensis*	2 y	Fever, myalgia, headache, acute renal failure, developed features of thrombotic thrombocytopenic purpura	PCR	N	NA	Post-transplant infection	Survived
Liddell, 2002	Missouri	M/56	Liver	*E. chaffeensis*	5 y	Fever, myalgias, headache, nausea, leukopenia, thrombocytopenia	Serology	Y	NA	Post-transplant infection (reinfection)	Survived
Liddell, 2002	Missouri	M/58	Liver	*E. chaffeensis*	7 y	Fever, headache, arthralgias, leukopenia, thrombocytopenia	PCR	Y	NA	Post-transplant infection (reinfection)	Survived
Thomas, 2007	Tennessee	M/50	Kidney	*E. chaffeensis*	3.9 y	Fever, headache	Serology	NA	NA	NA	Survived
Thomas, 2007	Tennessee	F/34	Kidney	*E. ewingii*	3.8 y	Fever, headache, myalgia	PCR	NA	NA	NA	Survived
Thomas, 2007	Tennessee	F/15	Kidney	*E. ewingii*	5.3 y	Fever, cough, nausea, vomiting	PCR	NA	NA	NA	Survived
Thomas, 2007	Tennessee	M/17	Liver	*E. chaffeensis*	16.4 y	Fever, headache, anorexia	PCR	NA	NA	NA	Survived
Thomas, 2007	Tennessee	M/44	Kidney	*E. chaffeensis*	4 y	Fever, epigastric pain, nausea, cough	PCR	NA	NA	NA	Survived
Thomas, 2007	Tennessee	M/63	Heart	Undetermined *Ehrlichia* species	11.6 y	Fever, nausea, vomiting, diarrhea	PCR	NA	NA	NA	Survived
Thomas, 2007	Tennessee	M/36	Kidney	*E. chaffeensis*	2.6 y	Fever, headache	PCR	NA	NA	NA	Survived
Thomas, 2007	Tennessee	M/61	Heart	*E. chaffeensis*	6.2 y	Fever, headache	PCR	NA	NA	NA	Survived
Thomas, 2007	Tennessee	M/65	Lung	*E. ewingii*	6.1 y	Fever, headache, nausea, vomiting	PCR	NA	NA	NA	Survived
Thomas, 2007	Tennessee	M/51	Kidney	*E. chaffeensis*	1.6 y	Fever, headache, nausea, vomiting	PCR	NA	NA	NA	Survived
Thomas, 2007	Tennessee	M/22	Kidney	*E. chaffeensis*	1.9 y	Fever, diarrhea	PCR	NA	NA	NA	Survived
Thomas, 2007	Tennessee	M/73	Heart	*E. chaffeensis*	14.3 y	Fever	PCR	NA	NA	NA	Survived
Assi, 2007	Wisconsin	M/66	Kidney	*A. phagocytophilum*	9 y	Fever, chills, malaise, diffuse myalgia, and headache	PCR	Y	NA	Post-transplant infection	Survived
Lawrence, 2009	Missouri	F/68	Lung	*E. chaffeensis*	30 mo	Fever, cough	PCR	NA	NA	NA	Survived
Lawrence, 2009	Missouri	F/63	Lung	*E. ewingii*	82 mo	Fever, cough	PCR	NA	NA	NA	Survived
Lawrence, 2009	Missouri	M/57	Lung	*E. chaffeensis*	24 mo	Fever, headache, abdominal pain	PCR	NA	NA	NA	Survived
Lawrence, 2009	Missouri	F/26	Lung	*E. chaffeensis*	126 mo	Fever, headache, nausea, vomiting	PCR	NA	NA	NA	Survived
Lawrence, 2009	Missouri	M/62	Kidney	*E. chaffeensis*	12 mo	Chills, fatigue	PCR	NA	NA	NA	Survived
Lawrence, 2009	Missouri	M/64	Kidney	*E. ewingii*	17 mo	Fever, arthralgias, malaise, weakness	PCR	NA	NA	NA	Survived
Lawrence, 2009	Missouri	M/55	Kidney	*E. chaffeensis*	159 mo	Fever, chills, headache, myalgias	PCR	NA	NA	NA	Survived
Lawrence, 2009	Missouri	M/45	Kidney	*E. chaffeensis*	42 mo	Fever, nausea, vomiting, anorexia	PCR	NA	NA	NA	Survived
Lawrence, 2009	Missouri	M/50	Kidney	*E. ewingii*	101 mo	Fever, rash	PCR	NA	NA	NA	Survived

Author, year†	Recipient state of US residence	Sex/ Age, y	Organ	Genus and species‡	Time, transplant to symptoms	Symptoms/clinical details	Method of diagnosis	Tick exposure	Donor characteristics	Likely source of infection	Recipient outcome
Lawrence, 2009	Missouri	F/65	Kidney	*E. chaffeensis*	97 mo	Fever, headache	PCR	NA	NA	NA	Survived
Lawrence, 2009	Missouri	M/55	Kidney	*E. ewingii*	99 mo	Fever, headache	PCR	NA	NA	NA	Survived
Lawrence, 2009	Missouri	M/48	Kidney	*E. chaffeensis*	84 mo	Fever, headache, nausea, vomiting, diarrhea	PCR	NA	NA	NA	Survived
Lawrence, 2009	Missouri	F/44	Kidney	*E. chaffeensis*	130 mo	Fever, malaise	PCR	NA	NA	NA	Survived
Lawrence, 2009	Missouri	M/34	Kidney	*E. ewingii*	36 mo	Fever, cough, nausea, dyspnea, malaise	PCR	NA	NA	NA	Survived
Lawrence, 2009	Missouri	M/30	Kidney	*E. chaffeensis*	64 mo	Fever, chills, headache, nausea, vomiting	PCR	NA	NA	NA	Survived
Lawrence, 2009	Missouri	F/33	Kidney	*E. chaffeensis*	223 mo	Fever, chills, night sweats, nausea, vomiting	PCR	NA	NA	NA	Survived
Lawrence, 2009	Missouri	F/50	Liver	*E. ewingii*	51 mo	Fever, headache, myalgias	PCR	NA	NA	NA	Survived
Lawrence, 2009	Missouri	M/37	Liver	*E. chaffeensis*	92 mo	Fever, headache, vomiting, lethargy	PCR	NA	NA	NA	Survived
Lawrence, 2009	Missouri	M/58	Liver	*E. chaffeensis*	71 mo	Fever, headache, arthralgias	PCR	NA	NA	NA	Survived
Lawrence, 2009	Missouri	M/51	Liver	*E. ewingii*	65 mo	Fever, headache	PCR	NA	NA	NA	Survived
Lawrence, 2009	Missouri	M/54	Heart	*E. chaffeensis*	109 mo	Fever, headache, nausea	PCR	NA	NA	NA	Survived
Dorn, 2012	Virginia	M/27	Kidney	*E. chaffeensis*	4 y	SIRS, acute cellular rejection, admitted to ICU	Peripheral blood smear, serology	Y, ≤6 wk prior to symptoms	Living	Post-transplant infection	Survived
Kumar, 2014	Kentucky	M/63	Kidney	*E. chaffeensis*	10 y	Fever, leukopenia, thrombocytopenia and elevated transaminases, renal dysfunction, HLH	PCR	NA	Deceased	Post-transplant infection	Survived
Regunath, 2017	Missouri	F/69	Lung	*E. ewingii*	13 y	Fever, chills, nausea, non-bilious vomiting, mild leukopenia and thrombocytopenia	PCR	Y	Deceased, CMV+	Post-transplant infection	Survived
Khatri, 2019	Connecticut	M/67	Kidney	*A. phagocytophilum*	18 y	Malaise, acute diffuse scrotal pain, fever, headache, rhinorrhea, leukopenia and thrombocytopenia	PCR, blood smear	N	NA	NA	Survived
Albitar, 2019	Minnesota	M/33	Liver	*A. phagocytophilum*	17 y	Fever, leukocytosis	PCR, blood smear	Went deer hunting, no mention of ticks	Deceased	Post-transplant infection	Survived

*CMV+, cytomegalovirus positive; HLH, hemophagocytic lymphohistiocytosis; ICU, intensive care unit; NA, not available; SIRS, systemic inflammatory response syndrome

†In addition to these reports, Otrock et al. reported on 51 solid organ transplant and 5 stem cell transplant recipients diagnosed with ehrlichiosis during May 2007–October 2016 at Barnes-Jewish Hospital in St. Louis, Missouri, USA, which were excluded from this review. Characteristics of 56 recipients: median age (range) 56.9y (9–72y); 42M/14F; 37 tick exposure, 19 no tick exposure; 49 infected by *E. chaffeensis*, 7 infected by *E. ewingii*; organs received: 18 kidneys, 12 hearts, 12/56 lungs, 7 livers, 2 kidney and pancreas, and 5 received allogeneic stem cells.

‡Genera: *A., Anaplasma*; *E.*, *Ehrlichia*