Acknowledgments

The authors are grateful to all healthcare centers' employees and personnel for cooperating and conducting the survey, as well as to all participants who took part in this research.

This research was supported by a grant from Iran's Ministry of Health and Deputy of Research at Guilan University of Medical Sciences.

About the Author

Dr. Shakiba is an epidemiologist and faculty member at Guilan University of Medical Sciences. Her research interests include survey design and causal inference methodology.

References

1. World Health Organization. Coronavirus disease (COVID-19) situation reports 2020 [cited 2020 Aug 10]. https://www.who.int/emergencies/diseases/novel-coronavirus-2019/situation-reports
2. Russell TW, Hellewell J, Jarvis CI, van Zandvoort K, Abbott S, Ratnayake R, et al.; Cmmid Covid-Working Group. Estimating the infection and case fatality ratio for coronavirus disease (COVID-19) using age-adjusted data from the outbreak on the Diamond Princess cruise ship, February 2020. Euro Surveill. 2020;25:2000256. https://doi.org/10.2807/1560-7917.ES.2020.25.12.2000256
3. Clapham H, Hay J, Routledge I, Takahashi S, Choisy M, Cummings D, et al. Seroepidemiologic study designs for determining SARS-COV-2 transmission and immunity. Emerg Infect Dis. 2020;26:1978–86. https://doi.org/10.3201/eid2609.201840
4. Mansournia MA, Altman DG. Inverse probability weighting. BMJ. 2016;352:i189. https://doi.org/10.1136/bmj.i189
5. Cassaniti I, Novazzi F, Giardina F, Salinaro F, Sachs M, Perlini S, et al.; Members of the San Matteo Pavia COVID-19 Task Force. Performance of VivaDiag COVID-19 IgM/IgG Rapid Test is inadequate for diagnosis of COVID-19 in acute patients referring to emergency room department. J Med Virol. 2020;92:1724–7. https://doi.org/10.1002/jmv.25800
6. Van Elslande J, Houben E, Depypere M, Brackenier A, Desmet S, André E, et al. Diagnostic performance of seven rapid IgG/IgM antibody tests and the Euroimmun IgA/IgG ELISA in COVID-19 patients. Clin Microbiol Infect. 2020;26:1082–7. https://doi.org/10.1016/j.cmi.2020.05.023
7. Pollán M, Pérez-Gómez B, Pastor-Barriuso R, Oteo J, Hernán MA, Pérez-Olmeda M, et al.; ENE-COVID Study Group. Prevalence of SARS-CoV-2 in Spain (ENE-COVID): a nationwide, population-based seroepidemiological study. Lancet. 2020;396:535–44. https://doi.org/10.1016/S0140-6736(20)31483-5
8. Sood N, Simon P, Ebner P, Eichner D, Reynolds J, Bendavid E, et al. Seroprevalence of SARS-CoV-2-specific antibodies among adults in Los Angeles County, California, on April 10–11, 2020. JAMA. 2020;323:2425–7. https://doi.org/10.1001/jama.2020.8279
9. Stringhini S, Wisniak A, Piumatti G, Azman AS, Lauer SA, Baysson H, et al. Seroprevalence of anti-SARS-CoV-2 IgG antibodies in Geneva, Switzerland (SEROCoV-POP): a population-based study. Lancet. 2020;396:313–9. https://doi.org/10.1016/S0140-6736(20)31304-0
10. Bhatraju PK, Ghassemieh BJ, Nichols M, Kim R, Jerome KR, Nalla AK, et al. Covid-19 in critically ill patients in the Seattle region—case series. N Engl J Med. 2020;382:2012–22. https://doi.org/10.1056/NEJMoa2004500

Address for correspondence: Mohammad Ali Mansournia, 5th Fl, Building of School of Public Health, Tehran University of Medical Sciences, Poursina St, 16 Azar St, Tehran 14155-6446, Iran; email: mansournia_ma@yahoo.com; Abtin Heidarzadeh, Pasdaran St, Deputy of Health, Guilan University of Medical Sciences, Rasht 41937-13111, Iran; email: heidarzadeh@gums.ac.ir

Intrauterine Transmission of SARS-CoV-2

Emanuele Therezinha Schueda Stonoga,[1] Laura de Almeida Lanzoni,[1] Patricia Zadorosnei Rebutini,[1] André Luiz Permegiani de Oliveira, Jullie Anne Chiste, Cyllian Arias Fugaça, Daniele Margarita Marani Prá, Ana Paula Percicote, Andrea Rossoni, Meri Bordignon Nogueira, Lucia de Noronha, Sonia Mara Raboni

Author affiliations: Hospital de Clínicas da Universidade Federal do Paraná, Parana, Brazil (E.T.S. Stonoga, L.A. Lanzoni, J.A. Chiste, C.A. Fugaça, M.B. Nogueira); Pontifícia Universidade Católica do Paraná, Parana (P.Z. Rebutini, A.L.P. Oliveira, D.M. Marani Prá, L. de Noronha); Universidade Federal do Paraná, Parana (A.P. Percicote, A. Rossoni, S.M. Raboni)

DOI: https://doi.org/10.3201/eid2702.203824

We documented fetal death associated with intrauterine transmission of severe acute respiratory syndrome coronavirus 2. We found chronic histiocytic intervillositis, maternal and fetal vascular malperfusion, microglial hyperplasia, and lymphocytic infiltrate in muscle in the placenta and fetal tissue. Placenta and umbilical cord blood tested positive for the virus by PCR, confirming transplacental transmission.

[1]These first authors contributed equally to this article.

A woman 42 years of age at 27 weeks' gestation sought treatment at Hospital de Clínicas da Universidade Federal do Paraná, Parana, Brazil, for symptoms of coronavirus disease (COVID-19). Dyspnea, dry cough, high temperature (38.5°C), anosmia, nausea, vomiting, and diarrhea had developed 2 days before hospitalization. At admission, we collected a nasopharyngeal swab sample and tested it for severe acute respiratory syndrome coronavirus 2 (SARS-CoV-2) and rhinovirus by reverse transcription PCR (RT-PCR) (XGEN MASTER COVID-19 Kit; Mobius Life Science, Inc, https://mobiuslife.com.br) (Appendix Figure 1, https://wwwnc.cdc.gov/EID/article/27/2/20-3824-App1.pdf). The sample tested positive for both viruses. We prescribed azithromycin, oseltamivir, prophylactic enoxaparin, and corticosteroids for fetal lung maturation. A chest computed tomography scan revealed bilateral ground glass opacities and interlobular septal thickening. After 4 days, the patient needed ventilatory and hemodynamic support.

The patient's prenatal care had been uneventful. She had undergone routine tests and ultrasound scans; the most recent had been at 25 weeks' gestation. Her medical history included a previous pregnancy complicated by hypertension that resolved with delivery. The current pregnancy was her seventh; she previously had delivered 3 children and had 2 abortions and 1 ectopic pregnancy.

Six days after admission, obstetric ultrasound demonstrated a single intrauterine pregnancy. The fetus was in a transverse position with shoulder presentation; the ultrasound showed reduced amniotic fluid volume and absence of fetal movements and heart rate. Because misoprostol failed to induce labor, we conducted a cesarean delivery. The fetus was stillborn. Immediately after delivery, we used an aseptic technique to collect samples of amniotic fluid (before amniotic membranes ruptured), umbilical cord blood, placental membranes, and cotyledon fragments (Table).

We obtained informed written consent for fetal autopsy, placental grossing, and histologic examination. External examination showed a female concept with skin discoloration and moderate peeling; the fetus had gestational age of ≈28 weeks and weighed 1,020 g (50th percentile). Internal examination revealed red serous effusions in the chest and abdomen and petechial hemorrhage in the heart and lungs. We conducted evisceration using the Letulle method and separated the organs into functional groups. We noted hepatic discoloration and friability and lung and kidney hypoplasia (both <5th percentile). We did not identify other macroscopic abnormalities.

The placental disc was round, and had tan and glistening membranes peripherally attached. The umbilical cord had 3 vessels; it was 28 cm long, inserted eccentrically, and under coiled. The fetal surface was gray with normal chorionic plate vessels. The trimmed placental disc weighed 135 g and measured 12 × 12 cm (<3rd percentile) (Appendix Figure 2). We collected additional samples of fetal liver, spleen, lung, central nervous system tissue, ovary, and muscle for RT-PCR (Table). Tissue samples were fixed in 10% buffered formalin, routinely processed, stained in hematoxylin and eosin, and underwent immunohistochemical staining using CD68 antibodies (Figure; Appendix Figure 2).

Few reports have described the effects of SARS-CoV-2 infection in utero; because pathogen detection requires multiple samples, it has been difficult to characterize congenital infection (*1*,*2*). According to Shah et al. (*3*), congenital SARS-CoV-2 infection can be confirmed by PCR of placental tissue. We detected

Table. Results of PCR for severe acute respiratory syndrome coronavirus 2 in a pregnant woman and fetus, Brazil, 2020*

		Cycle threshold†		
Sample	Day	ORF1ab	N	RNaseP‡
Maternal nasopharyngeal swab sample	0	21.0	24.0	23.0
Maternal nasopharyngeal swab sample	4	20.9	24.8	29.9
Umbilical cord blood	8	31.9	30.3	27.0
Placenta§	8	24.5	25.5	25.6
Fetal liver	9	Undetectable	Undetectable	29.0
Fetal spleen	9	Undetectable	Undetectable	27.8
Fetal lungs	9	Undetectable	Undetectable	25.7
Fetal central nervous system	9	Undetectable	Undetectable	29.4
Fetal skeletal muscle	9	Undetectable	Undetectable	26.5
Fetal heart	9	Undetectable	Undetectable	26.5
Fetal ovary	9	Undetectable	Undetectable	25.4

*PCR conducted using XGEN MASTER COVID-19 Kit (Mobius Life Science, Inc, https://mobiuslife.com.br). N, nucleocapsid protein gene; ORF, open reading frame.
†Cycle threshold value is considered positive if both viral genes are <38.
‡PCR is selective for human RNaseP gene as a control for sample integrity.
§Insufficient sample.

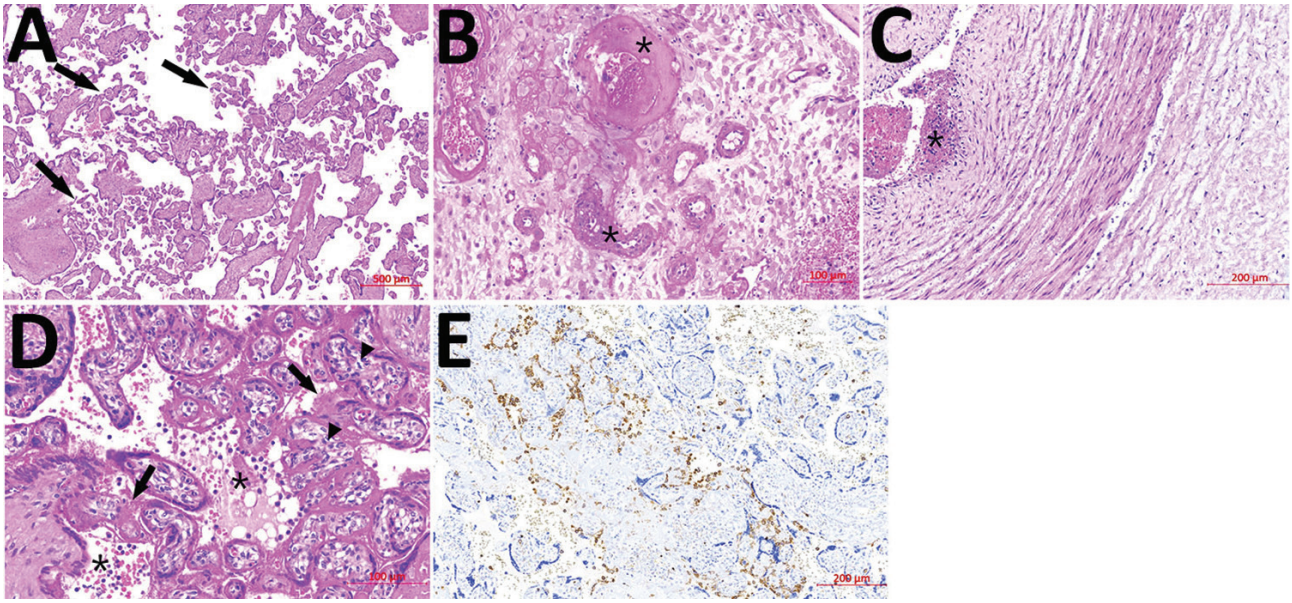

Figure. Histologic sections from the placenta of stillborn fetus of a woman with severe acute respiratory syndrome coronavirus 2 infection, Brazil, 2020. Tissue stained with hematoxylin and eosin. A) Placenta shows accelerated villous maturation with increase in syncytial knots. Black arrows indicate small or short hyper mature villi. B) Membranes and basal decidua show decidual arteriopathy, including fibrinoid necrosis with foam cells, mural hypertrophy, absence of spiral artery remodeling, and arterial thrombosis associated with decidual infarct. Asterisks (*) indicate fibrinoid necrosis. C) The umbilical cord shows subendothelial edema and nonocclusive arterial thrombosis, which was also focally observed in a chorionic plate and stem vessels. Asterisks (*) indicate arterial thrombosis. D–E) Photomicrographs show diffuse perivillous fibrin deposition associated with multifocal mononuclear inflammatory infiltrate in the intervillous space and occasional intervillous thrombi. Black arrows indicate fibrin deposition; asterisks (*) indicate mononuclear infiltrate; arrowheads indicate increase in number of Hofbauer cells. E) Immunohistochemical assay using CD68 antibodies highlights histiocyte infiltrate in paraffin-embedded samples (KP1 Clone; Biocare Medical LLC, https://biocare.net).

SARS-CoV-2 RNA in cotyledon samples, membranes, and umbilical cord blood aspirate, suggesting a breakdown of the placental barrier and fetal intrauterine viremia. We used immunohistochemical staining with CD68 antibodies to identify multifocal chronic histiocytic intervillositis in the placenta (Figure, panels D, E). This condition was also described in other pregnant women with COVID-19 (*4*,*5*). We also noted microglial hyperplasia, mild lymphocytic infiltrate, and edema in skeletal muscle (Appendix Figure 3). These findings might suggest infection. However, all fetal tissue samples tested negative for SARS-CoV-2 RNA (Table). Other findings might have been caused by intrauterine asphyxia (Appendix Figure 3).

COVID-19 is associated with cytokine storm, an exaggerated inflammatory response that is usually indicative of disease severity (*6*). Excessive inflammation could cause endothelial damage and disrupt the coagulation system; some evidence suggests that thrombotic and microvascular injury might affect manifestations of COVID-19 (*7*,*8*). We noted severe maternal vascular malperfusion injuries in the placenta, including substantial recent infarcts, decidual vasculopathy, accelerated villous maturation, and low placental weight. Similar findings are often observed in placentas from women with hypertensive disorders and have been associated with oligohydramnios, preterm birth, and stillbirth. Although the patient's blood pressure was within reference limits, her age and history of gestational hypertension are risk factors for such alterations and the probable cause of placental insufficiency and fetal demise (*9*,*10*). We also observed multifocal small intervillous thrombi and focal thrombosis of fetal placental vessels. Therefore, the extent and apparently rapid development of these findings suggests that infection contributed to vascular damage.

The effects of congenital transmission of SARS-CoV-2 remain largely unknown. This study highlights the need for placental and fetal gross and microscopic evaluation, which can help elucidate the pathophysiology of COVID-19.

About the Author

Dr. Stonoga is a first-year pathology resident at Hospital de Clínicas da Universidade Federal do Paraná, Parana. Her research interests include perinatal pathology and infectious disease research.

References

1. Alzamora MC, Paredes T, Caceres D, Webb CM, Valdez LM, La Rosa M. Severe COVID-19 during pregnancy and possible vertical transmission. Am J Perinatol. 2020;37:861–5. https://doi.org/10.1055/s-0040-1710050
2. Kirtsman M, Diambomba Y, Poutanen SM, Malinowski AK, Vlachodimitropoulou E, Parks WT, et al. Probable congenital SARS-CoV-2 infection in a neonate born to a woman with active SARS-CoV-2 infection. CMAJ. 2020;192:E647–50. https://doi.org/10.1503/cmaj.200821
3. Shah PS, Diambomba Y, Acharya G, Morris SK, Bitnun A. Classification system and case definition for SARS-CoV-2 infection in pregnant women, fetuses, and neonates. Acta Obstet Gynecol Scand. 2020;99:565–8. https://doi.org/10.1111/aogs.13870
4. Sisman J, Jaleel MA, Moreno W, Rajaram V, Collins RRJ, Savani RC, et al. Intrauterine transmission of SARS-COV-2 infection in a preterm infant. Pediatr Infect Dis J. 2020; 39:e265–7.
5. Vivanti AJ, Vauloup-Fellous C, Prevot S, Zupan V, Suffee C, Do Cao J, et al. Transplacental transmission of SARS-CoV-2 infection. Nat Commun. 2020;11:3572. https://doi.org/10.1038/s41467-020-17436-6
6. Huang C, Wang Y, Li X, Ren L, Zhao J, Hu Y, et al. Clinical features of patients infected with 2019 novel coronavirus in Wuhan, China. [Erratum in: Lancet. 2020;395:496]. Lancet. 2020;395:497–506. https://doi.org/10.1016/S0140-6736(20)30183-5
7. Nagashima S, Mendes MC, Camargo Martins AP, Borges NH, Godoy TM, Miggiolaro AFRDS, et al. Endothelial dysfunction and thrombosis in patients with COVID-19—brief report. Arterioscler Thromb Vasc Biol. 2020;40:2404–7. https://doi.org/10.1161/ATVBAHA.120.314860
8. Benhamou D, Keita H, Ducloy-Bouthors AS; CARO working group. Coagulation changes and thromboembolic risk in COVID-19 obstetric patients. Anaesth Crit Care Pain Med. 2020;39:351–3. https://doi.org/10.1016/j.accpm.2020.05.003
9. Shanes ED, Mithal LB, Otero S, Azad HA, Miller ES, Goldstein JA. Placental pathology in COVID-19. Am J Clin Pathol. 2020;154:23–32. https://doi.org/10.1093/ajcp/aqaa089
10. Baergen RN, Heller DS. Placental pathology in Covid-19 positive mothers: preliminary findings. Pediatr Dev Pathol. 2020;23:177–80. https://doi.org/10.1177/1093526620925569

Address for correspondence: Patricia Zadorosnei Rebutini, Postgraduate Program of Health Sciences, Pontifícia Universidade Católica do Paraná, Rua Imaculada Conceição, 1155, Prado Velho, Curitiba, Parana, Brazil; email: patricia.rebutini@hc.ufpr.br

COVID-19 and Infant Hospitalizations for Seasonal Respiratory Virus Infections, New Zealand, 2020

Adrian Trenholme,[1] Rachel Webb,[1] Shirley Lawrence, Sharon Arrol, Susan Taylor, Shanthi Ameratunga, Catherine A. Byrnes

Author affiliations: Kidz First Children's Hospital, Auckland, New Zealand (A. Trenholme, R. Webb, S. Lawrence); University of Auckland, Auckland (A. Trenholme, R. Webb, C.A. Byrnes); Department of Health Informatics, Auckland (R. Webb, S. Arrol); Middlemore Hospital, Auckland (S. Arrol, S. Taylor. S. Ameratunga); Population Health Directorate, Auckland (S. Ameratunga); Starship Children's Health, Auckland (C.A. Byrnes)

DOI: https://doi.org/10.3201/eid2702.204041

In March 2020, a national elimination strategy for coronavirus disease was introduced in New Zealand. Since then, hospitalizations for lower respiratory tract infection among infants <2 years of age and cases of respiratory syncytial or influenza virus infection have dramatically decreased. These findings indicate additional benefits of coronavirus disease control strategies.

In New Zealand, the incidence of hospitalization of infants with lower respiratory tract infection (LRTI) is high. LRTIs disproportionately affect Māori and Pacific Islander children and are predominantly caused by respiratory syncytial virus (RSV) (*1*).

The first case of coronavirus disease (COVID-19) in New Zealand was identified on February 28, 2020. Subsequently, the government pursued an elimination strategy, commencing with a national lockdown on March 25, along with strict international border controls, mandatory 14-day isolation of all international arriving passengers, intensive community testing, school closures, and contact tracing. This strategy seems to have largely succeeded, although recent small clusters of cases in the Auckland region demonstrate continuing vulnerabilities (*2*).

Kidz First Children's Hospital serves an urban population of ≈550,000 persons in South Auckland, where 50% of infants are of Māori or Pacific Islander ethnicity. Since 2007, clinicians have performed nasopharyngeal sampling for respiratory virus PCR

[1]These first authors contributed equally to this article.

Article DOI: https://doi.org/10.3201/eid2702.203824

Intrauterine Transmission of SARS-CoV-2

Appendix

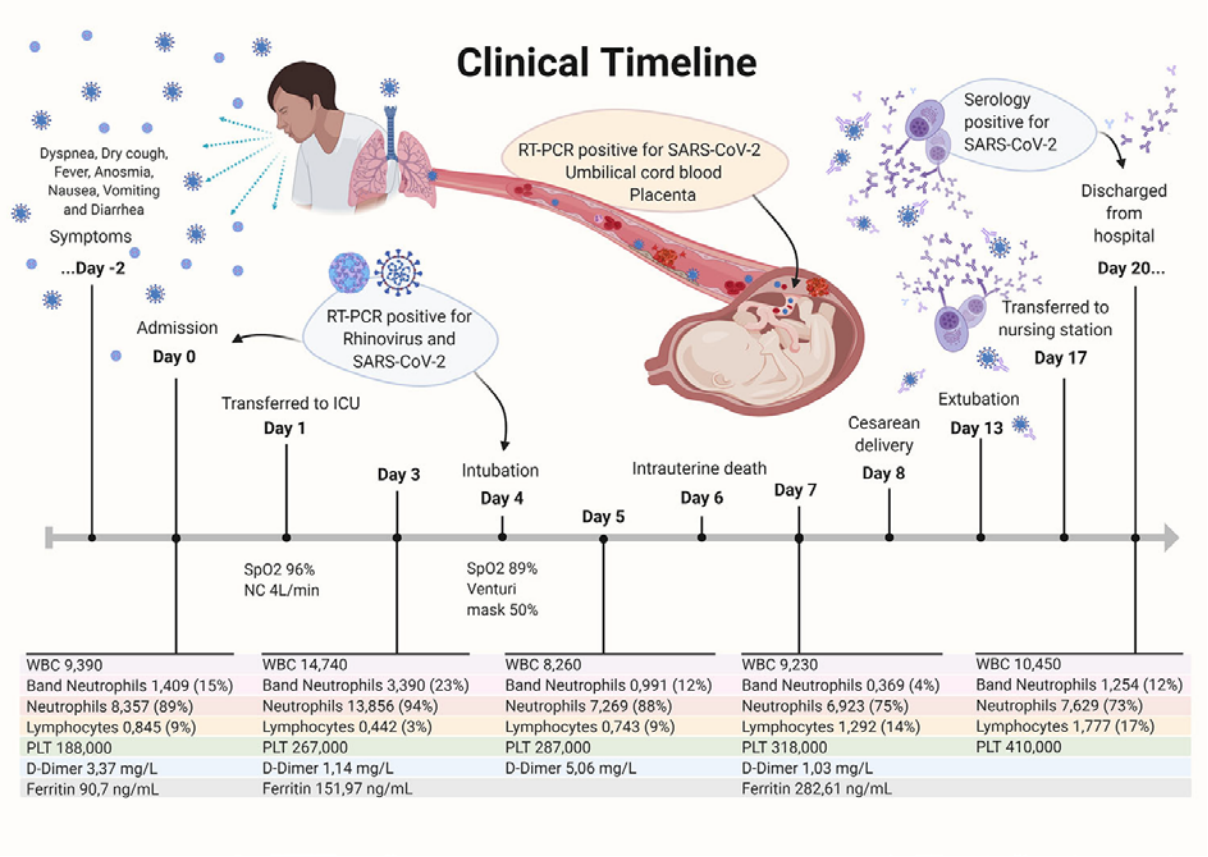

Appendix Figure 1. Timeline of intrauterine transmission of SARS-CoV-2, Brazil, 2020. PCR conducted with XGEN MASTER COVID-19 Kit (Mobius Life Science, Inc, https://mobiuslife.com.br). Image created with BioRender (https://www.getbiorender.com). ICU, intensive care unit; NC, nasal cannula; PLT, platelets; RT-PCR, reverse transcription PCR; SARS-CoV-2, severe acute respiratory syndrome coronavirus 2; SpO2, oxygen saturation; leukocyte, leukocyte.

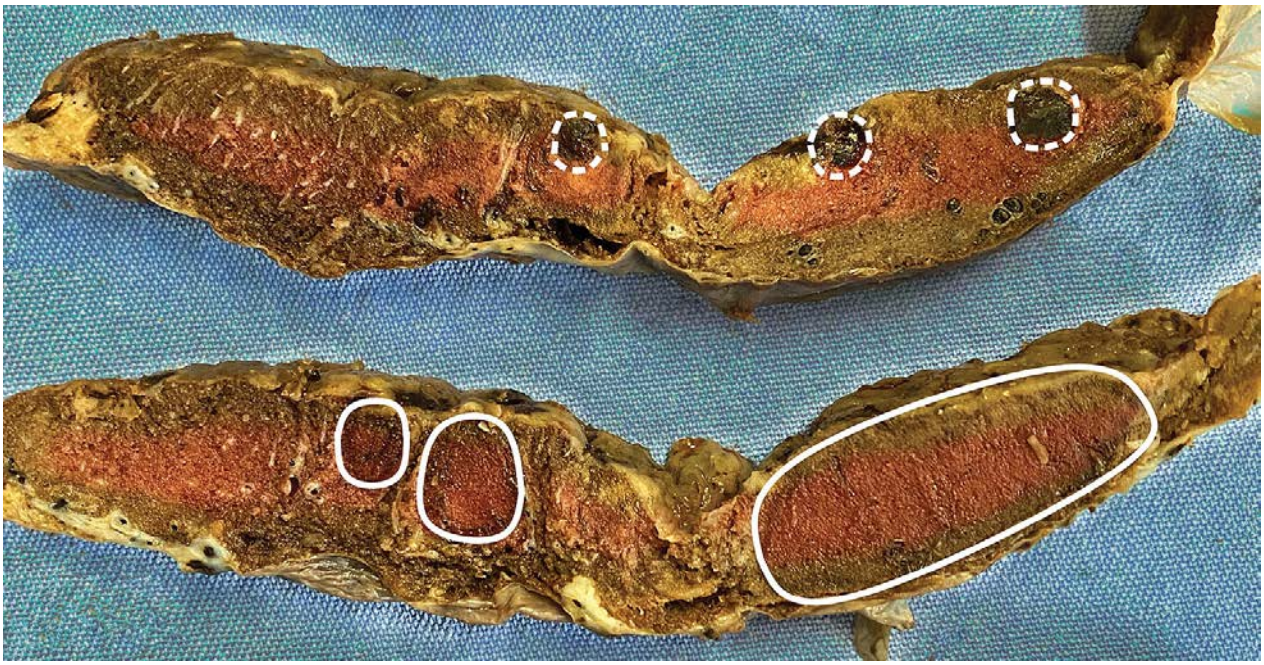

Appendix Figure 2. Placenta of stillborn fetus of a woman with severe acute respiratory syndrome coronavirus 2 infection, Brazil, 2020. Serial sectioning of placental disc shows spongy dark red parenchyma with recent and hemorrhagic nonperipheral infarcts. White circles indicate recent infarcts; dashed white circles indicate hemorrhagic infarcts.

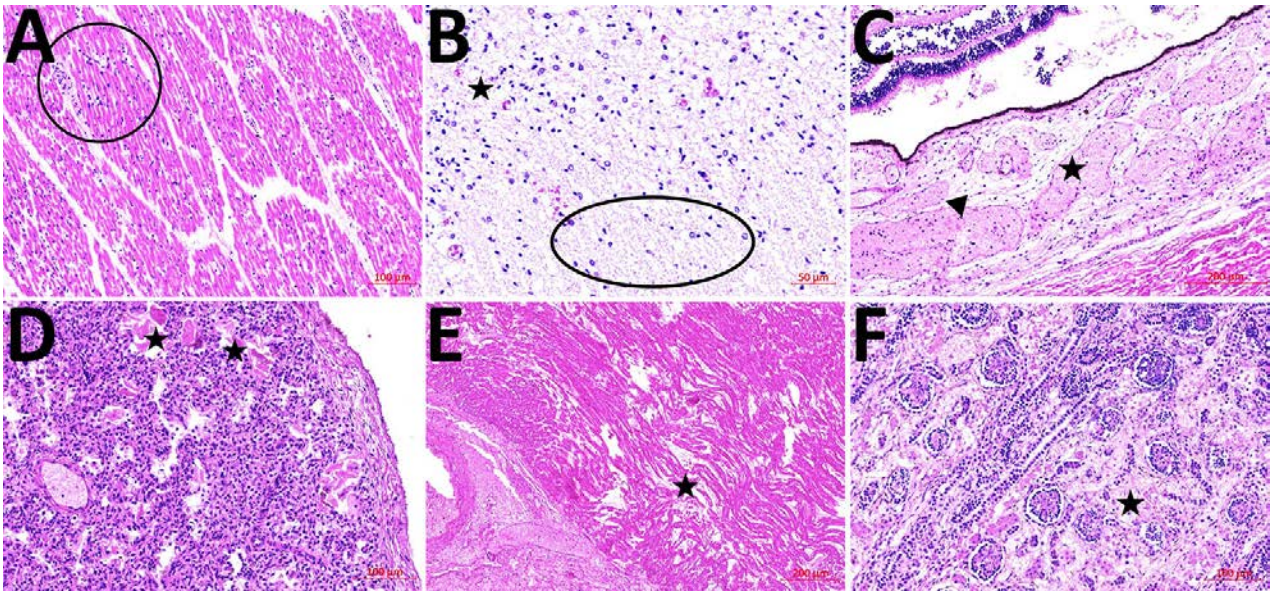

Appendix Figure 3. Histological sections of tissues from a fetus of a woman with severe acute respiratory syndrome coronavirus 2 infection, Brazil, 2020. Tissue stained with hematoxylin and eosin. A) Skeletal muscle with mild interstitial edema. Circled area indicates scattered lymphocytic infiltrate. B) Brain samples show white matter with areas of increased cellularity, suggesting microglial activation. Star

indicates increased cellularity; circled area shows reference area for comparison. C) Cross-section of the eye shows accentuated choroidal edema and congestion. Arrowhead indicates edema; star indicates congestion. D) Lungs show large number of aspirated squamous cells. Stars indicate distal alveolar branches. E) Heart samples show mild interstitial edema and mild lymphocytic infiltrate in the pericardium. Star indicates interstitial edema. F) Kidney shows systemic congestion associated with interstitial hemorrhage. Star indicates congestion.