(https://www.megasoftware.net). This tree included isolates from other countries in Asia downloaded from PubMLST (https://pubmlst.org); the isolate in this study was most closely related to ST175 from Thailand (Appendix Figure 2) (*6*).

The accuracy of the identifications made by VITEK 2 (63%–81%), Phoenix (0%–28%), and API 20NE (37%–99%) systems varied substantially (*7*,*8*). Zakharova et al. found that commercially available biochemical identification systems commonly misidentified *B. pseudomallei* as *Chromobacterium violaceum* or *B. cepacia* complex (*9*). We found that although the isolate in this study was misidentified by multiple systems, most systems accurately identified the genus. MALDI-TOF mass spectrometry is a rapid, accurate, and highly reproducible technique for bacterial identification. Several studies have explored the potential of MALDI-TOF mass spectroscopy for the identification of *B. pseudomallei*. We prefer the Bruker Biotyper system, which is more accurate because the VITEK databases lack reference spectra for *B. pseudomallei* (*10*). In conclusion, scientists must be aware of the potential misidentification of *B. pseudomallei* by automated identification systems, especially those in regions to which *B. pseudomallei* is not endemic.

About the Author

Mr. Wu is a member of the Department of Laboratory Medicine of Guangzhou First People's Hospital, Guangzhou. His primary research interest is bacterial infections.

References

1. Chewapreecha C, Holden MT, Vehkala M, Valimaki N, Yang Z, Harris SR, et al. Global and regional dissemination and evolution of *Burkholderia pseudomallei*. Nat Microbiol. 2017;2:16263. https://doi.org/10.1038/nmicrobiol.2016.263
2. Kiratisin P, Santanirand P, Chantratita N, Kaewdaeng S. Accuracy of commercial systems for identification of *Burkholderia pseudomallei* versus *Burkholderia cepacia*. Diagn Microbiol Infect Dis. 2007;59:277–81. https://doi.org/10.1016/j.diagmicrobio.2007.06.013
3. Kobayashi H, Seike S, Yamaguchi M, Ueda M, Takahashi E, Okamoto K, et al. *Aeromonas sobria* serine protease decreases epithelial barrier function in T84 cells and accelerates bacterial translocation across the T84 monolayer in vitro. PLoS One. 2019;14:e0221344. https://doi.org/10.1371/journal.pone.0221344
4. Lipsitz R, Garges S, Aurigemma R, Baccam P, Blaney DD, Cheng AC, et al. Workshop on treatment of and postexposure prophylaxis for *Burkholderia pseudomallei* and *B. mallei* Infection, 2010. Emerg Infect Dis. 2012;18:e2. https://doi.org/10.3201/eid1812.120638
5. Godoy D, Randle G, Simpson AJ, Aanensen DM, Pitt TL, Kinoshita R, et al. Multilocus sequence typing and evolutionary relationships among the causative agents of melioidosis and glanders, *Burkholderia pseudomallei* and *Burkholderia mallei*. J Clin Microbiol. 2003;41:2068–79. https://doi.org/10.1128/JCM.41.5.2068-2079.2003
6. Kamthan A, Shaw T, Mukhopadhyay C, Kumar S. Molecular analysis of clinical *Burkholderia pseudomallei* isolates from southwestern coastal region of India, using multi-locus sequence typing. PLoS Negl Trop Dis. 2018;12:e0006915. https://doi.org/10.1371/journal.pntd.0006915
7. Zong Z, Wang X, Deng Y, Zhou T. Misidentification of *Burkholderia pseudomallei* as *Burkholderia cepacia* by the VITEK 2 system. J Med Microbiol. 2012;61:1483–4. https://doi.org/10.1099/jmm.0.041525-0
8. Hoffmaster AR, AuCoin D, Baccam P, Baggett HC, Baird R, Bhengsri S, et al. Melioidosis diagnostic workshop, 2013. Emerg Infect Dis. 2015;21.
9. Zakharova IB, Lopasteyskaya YA, Toporkov AV, Viktorov DV. Influence of biochemical features of *Burkholderia pseudomallei* strains on identification reliability by Vitek 2 System. J Glob Infect Dis. 2018;10:7–10. https://doi.org/10.4103/jgid.jgid_39_17
10. Lau SK, Sridhar S, Ho CC, Chow WN, Lee KC, Lam CW, et al. Laboratory diagnosis of melioidosis: past, present and future. Exp Biol Med (Maywood). 2015;240:742–51. https://doi.org/10.1177/1535370215583801

Address for correspondence: Banglao Xu, Guangzhou First People's Hospital, School of Medicine, South China University of Technology, Department of Laboratory Medicine, 1 Panfu Rd, Guangzhou, 510180, China; email: eyxubl@scut.edu.cn

Autochthonous Case of Pulmonary Histoplasmosis, Switzerland

Yvonne Schmiedel,[1] Annina E. Büchi,[1] Sabina Berezowska, Alexander Pöllinger, Konrad Mühlethaler, Manuela Funke-Chambour

Author affiliations: Basel University Hospital, Basel, Switzerland (Y. Schmiedel); Hôpital du Jura, Delémont, Switzerland (Y. Schmiedel); Inselspital, Bern University Hospital, University of Bern, Bern, Switzerland (Y. Schmiedel, A.E. Büchi, A. Pöllinger, M. Funke-Chambour); Lausanne University Hospital and University of Lausanne Lausanne, Switzerland (S. Berezowska); Institute of Pathology, University of Bern, Bern, Switzerland (S. Berezowska); Institute for Infectious Diseases, University of Bern, Bern (K. Mühlethaler)

DOI: https://doi.org/10.3201/eid2703.191831

[1]These authors contributed equally to this article.

In Europe, pulmonary histoplasmosis is rarely diagnosed except in travelers. We report a probable autochthonous case of severe chronic pulmonary histoplasmosis in an immunocompetent man in Switzerland without travel history outside of Europe. Diagnosis was achieved by histopathology, fungal culture, and serology, but the source of the infection remains speculative.

A 48-year-old man in Switzerland sought treatment for a 1-year history of progressive dyspnea, cough, 20-kg weight loss, and increased sweating; he was receiving oxygen therapy. Results of previous consultations had been inconclusive. An HIV screening test was negative. Medical history included hyperreflexia, depression, and chronic hepatitis B. The man had stopped cocaine inhalation and heroin consumption 20 years earlier but continued smoking cigarettes and cannabis. Regular medications included omeprazole and trimipramine. Except for a short trip to Greece and Italy many years before, the patient reported no foreign travel.

In the absence of travel history to an endemic area, histoplasmosis was not initially considered at the time this patient sought treatment. A prolonged diagnostic process and delayed treatment initiation had meanwhile resulted in significant deterioration of health, including need for home oxygen therapy, and loss of ability to work. Meanwhile, the patient was cachectic and had clubbing on his fingers and toes. Spirometry revealed nearly normal dynamic lung volumes. Forced expiratory volume was 3 L (75%) and forced vital capacity 4.1 L (83%), but diffusion capacity was severely impaired; diffusing capacity for carbon monoxide was 20%. A 6-minute walking test was limited to 400 m (59% predicted), initial oxygen saturation dropping from 90% to 78%. A chest computed tomography (CT) scan showed a diffuse reticulonodular pattern with predominantly upper lung opacifications and bronchiectases indicating fibrotic lung disease (Figure, panels A, B). Reversed halo signs and right upper lobe nodules were found. Bronchoscopy results including bronchoalveolar lavage were unremarkable. Initial sampling with microbiological screening was negative.

Differential diagnoses included toxic lung damage or other interstitial lung disease, (e.g. atypical presentation of Langerhans cell histiocytosis or sarcoidosis). A wedge biopsy showed predominantly upper-lobe fibrosis and multiple, confluent, necrotizing granulomas harboring yeasts, establishing the diagnosis of pulmonary histoplasmosis (Appendix Figure, https://wwwnc.cdc.gov/EID/article/27/3/19-1831-App1.pdf).

A qualitative immunodiffusion test (IMMY, https://www.immy.com) was positive for antibodies in plasma, but an antigen immunoassay for *Histoplasma* in urine (IMMY) was negative; a beta-1,3-D glucan test (Fungitell, https://www.fungitell.com) was highly positive (>500 pg/mL; limit <80 pg/mL). At

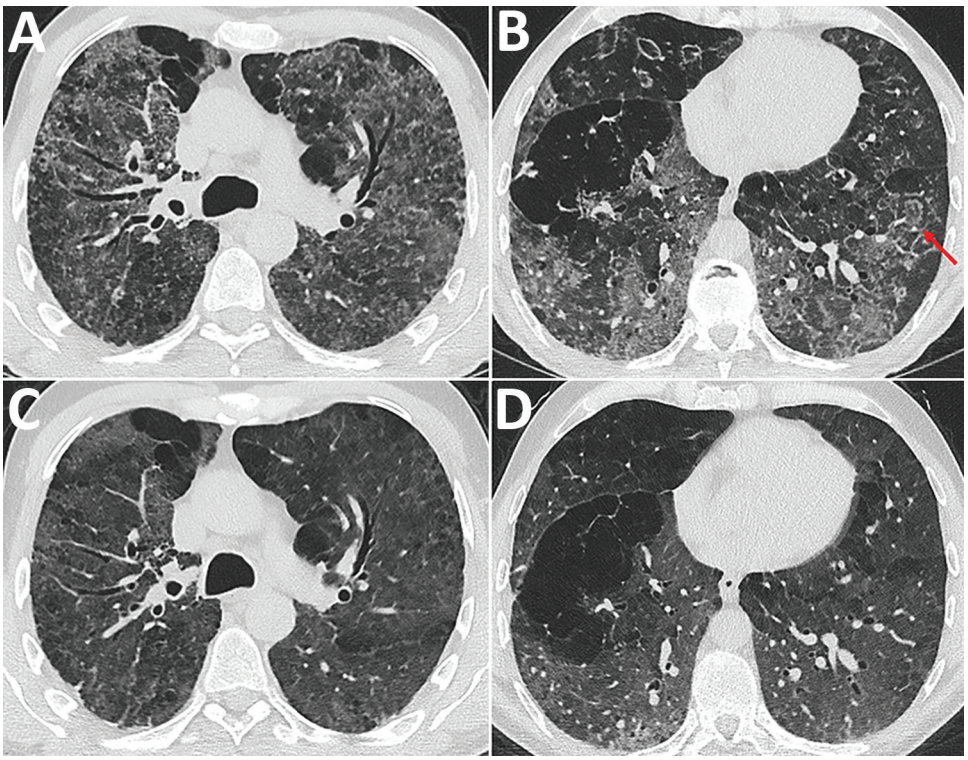

Figure. Chest computed tomography (CT) images at the level of the upper third and the lower third of the lung in a patient with pulmonary histoplasmosis, Switzerland. A, B) Initial CT shows diffuse reticulonodular pattern with ground glass opacifications, predominantly located in the upper two thirds of the lungs, and several areas with reverse halo signs (red arrows). C, D) Follow-up CT scan exhibited reduced ground-glass opacities and a regression of the micronodules. The reversed halos showed complete regression. CT, computed tomography.

prolonged incubation (14 days, 30°C), a fungal culture on BD Difco dehydrated culture media Sabouraud brain heart infusion agar base (with chloramphenicol and cycloheximide) (https://www.bd.com) showed flat, floccose to powdery, whitish growth. We found microscopically large, tuberculated macroconidia (7–12 μM) and small round microconidia on short, lateral pegs consistent with *Histoplasma capsulatum*. Matrix-assisted laser desorption/ionization time-of-flight mass spectrometry (MALDI Biotyper, https://www.bruker.com) results confirmed the diagnosis. Molecular identification was done using an in-house panfungal PCR assay with consecutive sequence analysis. We used the internal transcribed spacer region as target and internal transcribe sequences 1 and 2 for amplification primers (*1*,*2*). Microsynth AG (https://www.microsynth.ch) performed DNA sequencing. Sequences produced alignments of *H. capsulatum* in BLAST (https://blast.ncbi.nlm.nih.gov/Blast.cgi) and CBS (Centraalbureau voor Schimmelcultures; Westerdijk Institute, https://wi.knaw.nl) databases.

Some radiologic features were unusual. There was no cavity formation (*3*), and the reverse halo sign has rarely been described in chronic pulmonary histoplasmosis (*4*). However, bullae seen on the scan, previously observed in patients with heavy tobacco use and underlying lung disease, were compatible with the diagnosis. Despite slow growth, cultures for histoplasmosis together with histopathology remain the diagnostic standard (*1*). Panfungal PCR is sensitive, but its performance depends on internal validation processes (*2*). Immunocompetence and lack of dissemination could explain repeatedly negative urine antigen testing. (*1*).

Underlying lung disease likely predisposed this patient for severe disease. However, his clinical response to treatment was remarkable. We initiated antifungal treatment with liposomal amphotericin B and oral prednisolone. After a few days, the patient improved substantially, and oxygen supplementation was stopped. At 10 days, therapy was switched to oral itraconazole. Steroid treatment was continued at a tapered dosage over 3 months, with trimethoprim/sulfamethoxazole used as *Pneumocystis jirovecii* pneumonia prophylaxis. At 3-month follow-up, the patient had improved considerably. Repeated spirometry was nearly normal, showing persistent impairment of diffusion capacity. Follow-up chest CT scan (Figure 1, panels C, D) showed regression of ground-glass opacities and micronodules; the reversed halos had disappeared. Overall, optimal treatment duration remains unclear (*5*), but because of probable underlying preexisting lung disease, persistent pathological findings from CT, and continued desaturation under exercise, continuing treatment for >12 months seemed necessary.

The source of infection for this patient remains speculative. However, possible risk exposures were guano from flying bats in the garden (*6*), previous use of organic fertilizer possibly containing histoplasma (*7*), and regular work-related unpacking of fruits and spices from straw-filled boxes from West Africa, although *H. capsulatum* var. *capsulatum* is less common in that region (*8*).

In addition to previous findings of histoplasmosis in badgers (*9*), this case confirms the likely environmental occurrence of *H. capsulatum* in Switzerland. Although diagnoses of autochthonous histoplasmosis have been rare, and few autochthonous cases have been described (*10*), our finding of a probable autochthonous case of chronic pulmonary histoplasmosis in an immunocompetent male in Switzerland highlights the incomplete understanding of histoplasmosis endemicity and indicates that it has likely been underestimated in Europe.

About the Author

Ms. Schmiedel has a masters degree in epidemiology and a diploma in tropical medicine from Cayetano Heredia Universidad in Lima, Peru, and has completed specialized training in infectious diseases and internal medicine. She currently works as a senior infectious disease consultant at Hôpital du Jura (affiliated with Basel University Hospital) and has a strong interest in infection control and tropical medicine. Ms. Büchi has a masters degree in immunology and microbiology from Bern University in Switzerland and is studying to become an internist at the Inselspital in Bern. She has a primary research interest in bloodstream infection.

References

1. Hage CA, Ribes JA, Wengenack NL, Baddour LM, Assi M, McKinsey DS, et al. A multicenter evaluation of tests for diagnosis of histoplasmosis. Clin Infect Dis. 2011;53:448–54. https://doi.org/10.1093/cid/cir435
2. Kauffman CA. Histoplasmosis: a clinical and laboratory update. Clin Microbiol Rev. 2007;20:115–32. https://doi.org/10.1128/CMR.00027-06
3. Wheat LJ, Conces D, Allen SD, Blue-Hnidy D, Loyd J. Pulmonary histoplasmosis syndromes: recognition, diagnosis, and management. Semin Respir Crit Care Med. 2004;25:129–44. https://doi.org/10.1055/s-2004-824898
4. Marchiori E, Melo SMD, Vianna FG, Melo BSD, Melo SSD, Zanetti G. Pulmonary histoplasmosis presenting with the reversed halo sign on high-resolution CT scan. Chest. 2011;140:789–91. https://doi.org/10.1378/chest.11-0055
5. Wheat LJ, Freifeld AG, Kleiman MB, Baddley JW, McKinsey DS, Loyd JE, et al.; Infectious Diseases Society of America. Clinical practice guidelines for the management of patients with histoplasmosis: 2007 update by the Infectious Diseases Society of America. Clin Infect Dis. 2007;45:807–25. https://doi.org/10.1086/521259

6. Staffolani S, Buonfrate D, Angheben A, Gobbi F, Giorli G, Guerriero M, et al. Acute histoplasmosis in immunocompetent travelers: a systematic review of literature. BMC Infect Dis. 2018;18:673. https://doi.org/10.1186/s12879-018-3476-z
7. Gómez LF, Torres IP, Jiménez-A MDP, McEwen JG, de Bedout C, Peláez CA, et al. Detection of *Histoplasma capsulatum* in organic fertilizers by Hc100 nested polymerase chain reaction and its correlation with the physicochemical and microbiological characteristics of the samples. Am J Trop Med Hyg. 2018;98:1303–12. https://doi.org/10.4269/ajtmh.17-0214
8. Azar MM, Hage CA. Laboratory diagnostics for histoplasmosis. J Clin Microbiol. 2017;55:1612–20. https://doi.org/10.1128/JCM.02430-16
9. Akdesir E, Origgi FC, Wimmershoff J, Frey J, Frey CF, Ryser-Degiorgis MP. Causes of mortality and morbidity in free-ranging mustelids in Switzerland: necropsy data from over 50 years of general health surveillance. BMC Vet Res. 2018;14:195. https://doi.org/10.1186/s12917-018-1494-0
10. Ashbee HR, Evans EG, Viviani MA, Dupont B, Chryssanthou E, Surmont I, et al.; European Confederation of Medical Mycology Working Group on Histoplasmosis. Histoplasmosis in Europe: report on an epidemiological survey from the European Confederation of Medical Mycology Working Group. Med Mycol. 2008;46:57–65. https://doi.org/10.1080/13693780701591481

Address for correspondence: Yvonne Schmiedel, Inselspital University Hospital Bern, Department of Infectious Diseases, Freiburgstrasse Bern 3010, Switzerland; email: yvonneschmiedel@gmail.com

etymologia

Histoplasma capsulatum [hĭs′tə-plăz′mə kăp′sə-lā′təm]

Monika Mahajan

In 1905, Samuel Taylor Darling serendipitously identified a protozoan-like microorganism in an autopsy specimen while trying to understand malaria, which was prevalent during the construction of the Panama Canal. He named this microorganism *Histoplasma capsulatum* because it invaded the cytoplasm (plasma) of histiocyte-like cells (Histo) and had a refractive halo mimicking a capsule (capsulatum), a misnomer.

Histoplasma capsulatum, a dimorphic fungus, now belongs to Kingdom Fungi and causes histoplasmosis (Darling's disease) through inhalation of spores found in soil and bird droppings. The fungus thrives in the central and eastern parts of United States, especially around the Ohio and Mississippi River valleys, and in South America, Africa, Asia, and Australia. Three varieties exist globally: *H. capsulatum* var. *capsulatum, H. capsulatum* var. *duboisii,* and *H. capsulatum* var. *farciminosum.*

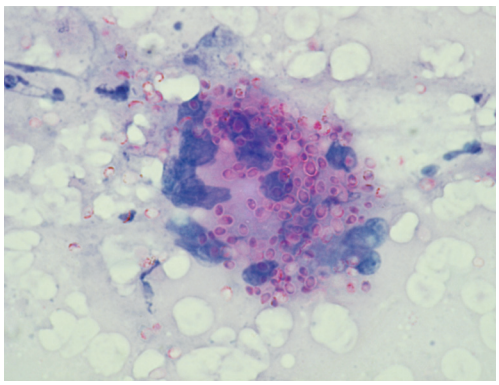

Figure. Numerous, capsulated yeast cells (shown in pink) of *Histoplasma capsulatum* in a bone marrow aspirate (Giemsa-stained, original magnification ×400). Source: Shivaprakash Rudramurthy, PGIMER, Chandigarh, India.

Sources

1. Darling ST. A protozoon general infection producing pseudotubercules in the lungs and focal necrosis in the liver, spleen, and lymphnodes. JAMA. 1906;46:1283. https://doi.org/10.1001/jama.1906.62510440037003
2. Hagan T. The discovery and naming of histoplasmosis: Samuel Taylor Darling. JAMA. 1903;40:1905–7 [cited 2020 Nov 19]. http://www.antimicrobe.org/hisphoto/history/Discovery%20of%20Histoplasmosis-Darling.asp
3. Histoplasmosis, types of diseases, fungal diseases, CDC [cited 2020 Aug 21]. https://www.cdc.gov/fungal/diseases/histoplasmosis/
4. Ramsey TL, Applebaum AA. Histoplasmosis "darling." Am J Clin Pathol. 1942;12:85–94. https://doi.org/10.1093/ajcp/12.2.85
5. Slavin MA, Chakrabarti A. Opportunistic fungal infections in the Asia–Pacific region. Med Mycol. 2012; 50:18–25. https://doi.org/10.3109/13693786.2011.602989

Author affilation: Post Graduate Institute of Medical Education and Research, Chandigarh, India

Address for correspondence: Monika Mahajan, Department of Medical Microbiology, Post Graduate Institute of Medical Education and Research, Research Block A, Sector 12, UT Chandigarh 160012, India; email: monideepmj@yahoo.com

DOI: https://doi.org/10.3201/eid2703.ET2703

Article DOI: https://doi.org/10.3201/eid2703.191831

Autochthonous Case of Pulmonary Histoplasmosis, Switzerland

Appendix

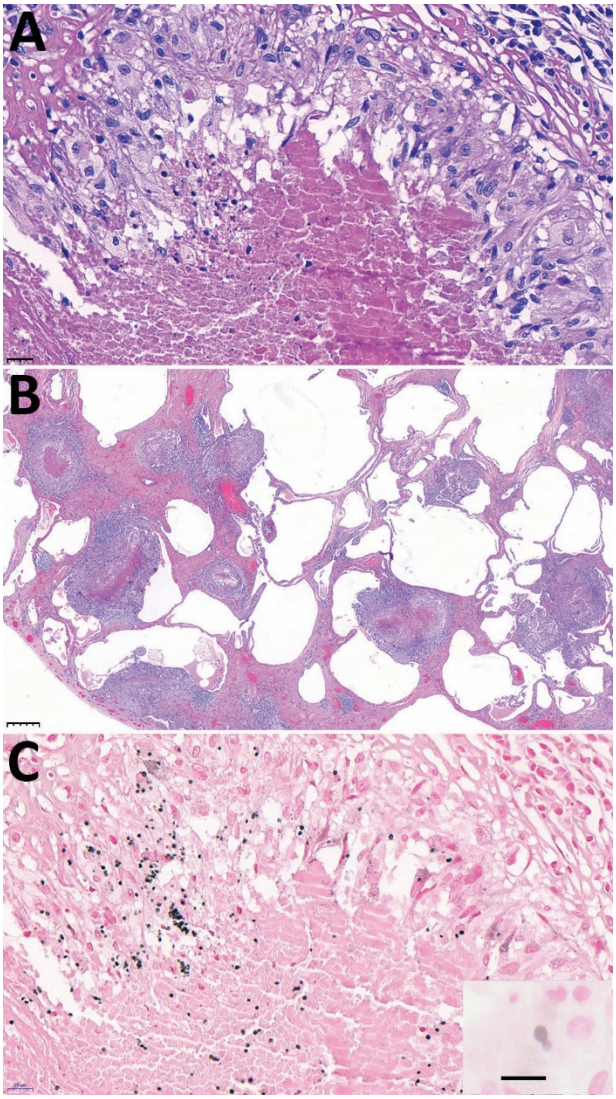

Appendix Figure. Diagnostic wedge-biopsy establishing diagnosis of pulmonary histoplasmosis. A) (hematoxylin and eosin staining; 20× magnification) Overview of the diagnostic wedge-biopsy showing emphysema, fibrosis, and necrotizing granulomas. B) Higher magnification (hematoxylin and eosin staining; 400×) highlights the necrosis and the surrounding histiocytic wall. C) (400× magnification) Grocott silver staining discloses the ovoid histoplasma organisms (black staining).