Implementing quarantine early in a pandemic is crucial for slowing the spread of a novel pathogen (*5*). Previous studies have suggested that the incubation period for Omicron could be shorter than that for the SARS-CoV-2 Delta variant (J. Chen, unpub. data, https://arxiv.org/abs/2112.01318). Estimating the duration of infectiousness is more challenging than measuring incubation periods; one study that measured viral load of Omicron suggested that viral load had diminished by days 10–13, which is in line with our findings (*6*).

To mitigate spread of highly contagious pathogens, the most effective public health measures are isolation and quarantine; however, these measures inevitably lead to personal and socioeconomic costs, necessitating evidence-based guidance from policy makers. A 10-day quarantine period may encompass most persons exposed to Omicron; however, quarantine duration may become shorter after balancing societal cost with public health benefit.

Acknowledgments

We thank the relevant ministries, including the Ministry of Interior and Safety, Si/Do and Si/Gun/Gu, medical staff in health centers, and medical facilities for their efforts in responding to the COVID-19 pandemic.

The opinions expressed by authors contributing to this journal do not necessarily reflect the opinions of the Korea Disease Control and Prevention Agency or the institutions with which the authors are affiliated.

About the Author

Mrs. H.R. Lee is a public health officer at Korea Disease Control and Prevention Agency. Her main research interest is epidemiologic investigation and surveillance measures of infectious diseases. Dr. Choe is a clinical assistant professor of pediatrics at Korea University Anam Hospital. His main research addresses quantification of and understanding the mechanisms of the effects of immunization programs on public health.

References

1. Meo SA, Meo AS, Al-Jassir FF, Klonoff DC. Omicron SARS-CoV-2 new variant: global prevalence and biological and clinical characteristics. Eur Rev Med Pharmacol Sci. 2021;25:8012–8.
2. Lee JJ, Choe YJ, Jeong H, Kim M, Kim S, Yoo H, et al. Importation and transmission of SARS-CoV-2 B.1.1.529 (Omicron) variant of concern in Korea, November 2021. J Korean Med Sci. 2021;36:e346. https://doi.org/10.3346/jkms.2021.36.e346
3. Petersen E, Ntoumi F, Hui DS, Abubakar A, Kramer LD, Obiero C, et al. Emergence of new SARS-CoV-2 Variant of Concern Omicron (B.1.1.529) - highlights Africa's research capabilities, but exposes major knowledge gaps, inequities of vaccine distribution, inadequacies in global COVID-19 response and control efforts. Int J Infect Dis. 2021 Dec 1;114:268–72.
4. Quarantine Management Team, COVID-19 National Emergency Response Center. Coronavirus disease-19: quarantine framework for travelers entering Korea. Osong Public Health Res Perspect. 2020;11:133–9. https://doi.org/10.24171/j.phrp.2020.11.3.04
5. Nussbaumer-Streit B, Mayr V, Dobrescu AI, Chapman A, Persad E, Klerings I, et al. Quarantine alone or in combination with other public health measures to control COVID-19: a rapid review. Cochrane Database Syst Rev. 2020;4:CD013574.
6. National Institute of Infectious Diseases Disease Control and Prevention Center, National Center for Global Health and Medicine. Active epidemiological investigation on SARS-CoV-2 infection caused by Omicron variant (Pango lineage B.1.1.529) in Japan: preliminary report on infectious period [cited 2022 Jan 15]. https://www.niid.go.jp/niid/en/2019-ncov-e/10884-covid19-66-en.html

Address for correspondence: Young-Joon Park, Director of Epidemiologic Investigation, (28159) Korea Disease Control and Prevention Agency, Osong Health Technology Administration Complex, 187, Osongsaengmyeong 2-ro, Osong-eup, Heungdeok-gu, Cheongju-si, Chungcheongbuk-do, Republic of Korea; email: pahmun@korea.kr

Legionella pneumophila Subspecies *fraseri* Infection after Allogeneic Hematopoietic Stem Cell Transplant, China

Xiaojuan Wang,[1] Yifan Guo,[1] Yawei Zhang, Qi Wang, Shuo Yang, Hua Yang, Tianyi Wang, Hui Wang

Author affiliations: Peking University People's Hospital, Beijing, China (X. Wang, Y. Guo, Y. Zhang, Q. Wang, S. Yang, H. Wang); Peking University Health Science Center, Beijing (Y. Guo, T. Wang); Zhongshan Torch Development Zone Hospital, Zhongshan, China (H. Yang) DOI: https://doi.org/10.3201/eid2804.211433

DOI: https://doi.org/10.3201/eid2804.211433

[1]These authors contributed equally to this article.

We describe an immunosuppressed patient with bacteremia and pneumonia caused by *Legionella pneumophila* subspecies *fraseri* in China. We confirmed this diagnosis by using nanopore sequencing of positive blood cultures and subsequent recovery from buffered-charcoal yeast extract culture. Nanopore sequencing is an effective tool for early diagnosis of atypical infections.

Legionella pneumophila is an opportunistic atypical pathogen of community-acquired or hospital-acquired pneumonia (*1*–*3*). Underestimates of its prevalence are likely because the *Legionella* urinary antigen testing and buffered-charcoal yeast extract (BCYE) culture routinely used for diagnosis are sometimes available only in a few tertiary hospitals that specialize in respiratory diseases. Therefore, early diagnosis and prompt therapy for *L. pneumophila* infection are crucial. We report a case of *L. pneumophila* subspecies *fraseri* bloodstream infection in a patient in China after allogeneic hematopoietic stem cell transplant (aHSCT). We confirmed this diagnosis by using nanopore sequencing of positive blood cultures and by recovering *L. pneumofila* using BCYE medium. Chest radiography and computed tomography (CT) suggested acute *L. pneumophila* pneumonia. The study was approved by the Institutional Review Board of the Peking University People's Hospital (approval no. 2019PHB134–01).

A 55-year-old man with acute T/myeloid mixed-cell leukemia was hospitalized because of nasal bleeding on day 62 after aHSCT. After treatment for thrombocytopenia, he experienced mild diarrhea on day 101. Three days later (day 104), his temperature was 38.8°C (Appendix Figure 1, https://wwwnc.cdc.gov/EID/article/28/4/21-1433-App1.pdf), but he had no accompanying symptoms. One aerobic blood culture vial, 1 anaerobic blood culture vial, and 1 Myco/F blood culture vial (BD, https://www.bd.com) per puncture point (2 puncture points) were collected for culture. Chest radiography and CT displayed multiple solid nodules in both lungs; the largest was in the right lower lobe, which suggested infection (Figure). The patient then experienced a 3-day continuous high fever with a maximum temperature of 39.5°C, a small amount of white sputum, and a blood oxygen saturation of 90% on day 107; the same number of blood culture vials were collected. CT showed a large, solid, fuzzy shadow with a unclear boundary, uneven internal density, and low-density plaques in the lower lobe of the right lung (Figure). The patient was administered linezolid (0.6 g every 12 h) and imipenem (0.5 g every 8 h) to control the infection. The patient's temperature decreased to a normal level, but the C-reactive protein values did not decrease to reference range (Appendix Figure 2).

After ≈10 days (256 h) of incubation, we observed that the blood cultures in the Myco/F vial collected on day 104 after aHSCT, which are commonly used to culture *Mycobacterium* spp. and fungus, contained the only growing gram-negative bacilli. We then transferred the positive blood cultures to blood nutrition plates for further culture in 5% carbon dioxide, anaerobic, and microaerobic environments, but this culture failed. Simultaneously, we directly used a serum separator-gel tube and matrix-assisted laser desorption/ionization time-of-flight (MALDI-TOF) mass spectrometry (*4*) to identify positive blood cultures but were unsuccessful. Subsequently, we extracted DNA from the positive blood cultures for nanopore sequencing (*5*,*6*); *L. pneumophila* subsp. *fraseri* was detected after 1 hour (Appendix; BioProject Short Read Archive accession no.

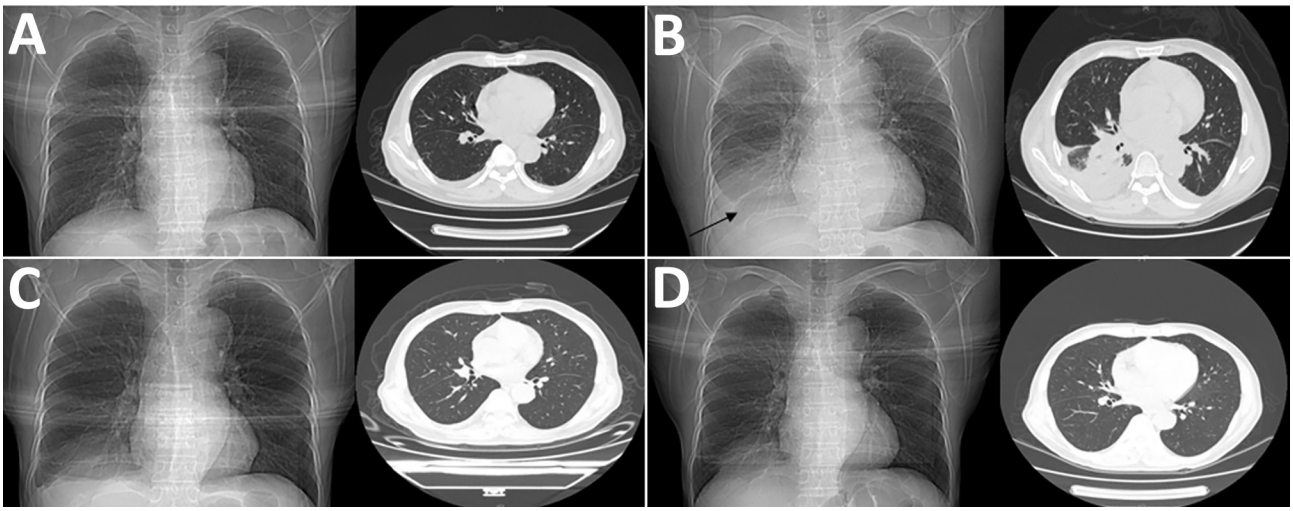

Figure. Chest radiography and computed tomography images during acute infection with *Legionella pneumophila* subspecies *fraseri* after allogeneic hematopoietic stem cell transplant, China, 2021. A) May 13, B) May 17, C) May 24, D) June 1. Arrow in panel B indicates a large, solid, fuzzy shadow with unclear boundary, uneven internal density, and low-density plaques in the lower lobe of the right lung.

PRJNA744850). The coverage length and depth were 37.67% and 2.04 with 1,337 raw reads. After timely communication of the sequencing results to the clinical department, the patient was administered azithromycin (0.5 g 1×/d for 1 d), followed by moxifloxacin (0.4 g 1×/d for 9 days) to ease symptoms of discomfort caused by azithromycin. The infection was finally controlled, and diarrhea symptoms improved 3 days after appropriate moxifloxacin therapy was initiated.

Afterward, we analyzed serum collected on May 24 (day 115) and May 27 (day 118) and detected *L. pneumophila* IgM by using an ELISA kit (Euroimmun, https://www.euroimmun.com). *Legionella* urinary antigen testing was not performed. Meanwhile, 100 µL of the positive blood cultures was inoculated on the in-house BCYE agar supplied with *Legionella* BCYE growth supplement medium (OXOID; Thermo Fisher Scientific, https://www.thermofisher.com). Two days later, we successfully isolated *L. pneumophila* and displayed wet blue-purple luster colonies (Appendix Figure 3); *L. pneumophila* was finally identified using MALDI-TOF mass spectrometry. During the course of infection, no more sputum specimens were available because the patient had no obvious cough or expectoration.

The fatality rate of Legionnaires' disease is between 5% and 30% (*7*). Risk factors for *L. pneumophila* infection include age >50 years, solid tumors or hematologic malignancies, solid organ transplant, and immunosuppression (*8*,*9*). Hence, shortening the turnaround time to identify microorganisms is crucial for timely diagnosis and appropriate therapy, which influence death rates. In this case, the diagnosis of *L. pneumophila* pneumonia was not possible on the basis of the atypical radiologic evidence, high fever (>38°C), elevated C-reactive protein, and diarrhea, although such manifestations are the most common symptoms of *L. pneumophila* infections (*10*). Furthermore, administration of corticosteroids and immunosuppressive drugs likely obscured the respiratory symptoms. Rapid nanopore sequencing with a short turnaround time has the potential to effectively expedite the detection of *L. pneumophila* infection, guaranteeing the appropriate antibiotic therapy, especially for immunosuppressed patients with atypical symptoms.

Acknowledgments

We thank Zhenzhong Li and Hongbin Chen for bioinformatics analysis, Ying Shang and Zhengwu Yang for serologic testing for *L. pneumophila* IgM, Jingzhi Wang for clinical communication and consultation, and Feifei Zhang for preparing of BYCE culture medium.

This work was supported by the National Key Research and Development Program of China (2018YFE0102100 and 2018YFC1200102).

About the Author

Dr. Wang is a researcher in the Department of Clinical Laboratory, Peking University People's Hospital, Beijing, China, focusing on the detection and study of resistance mechanisms of antimicrobial agents. Mr. Yifan Guo is a PhD candidate under the supervision of Dr. Wang in the Institute of Medical Technology, Peking University Health Science Center and the Department of Clinical Laboratory, Peking University People's Hospital, focusing on metagenomic sequencing and bioinformatics analysis.

References

1. Gonçalves IG, Simões LC, Simões M. Legionella pneumophila. Trends Microbiol. 2021;29:860–1. https://doi.org/10.1016/j.tim.2021.04.005
2. Miyashita N, Higa F, Aoki Y, Kikuchi T, Seki M, Tateda K, et al. Distribution of *Legionella* species and serogroups in patients with culture-confirmed *Legionella pneumonia.* J Infect Chemother. 2020;26:411–7. https://doi.org/10.1016/j.jiac.2019.12.016
3. Qin T, Ren H, Chen D, Zhou H, Jiang L, Wu D, et al. National surveillance of Legionnaires' disease, China, 2014-2016. Emerg Infect Dis. 2019;25:1218–9. https://doi.org/10.3201/eid2506.171431
4. Yonetani S, Ohnishi H, Ohkusu K, Matsumoto T, Watanabe T. Direct identification of microorganisms from positive blood cultures by MALDI-TOF MS using an in-house saponin method. Int J Infect Dis. 2016;52:37–42. https://doi.org/10.1016/j.ijid.2016.09.014
5. Charalampous T, Kay GL, Richardson H, Aydin A, Baldan R, Jeanes C, et al. Nanopore metagenomics enables rapid clinical diagnosis of bacterial lower respiratory infection. Nat Biotechnol. 2019;37:783–92. https://doi.org/10.1038/s41587-019-0156-5
6. Moon J, Jang Y, Kim N, Park WB, Park KI, Lee ST, et al. Diagnosis of *Haemophilus influenzae* pneumonia by Nanopore 16S Amplicon sequencing of sputum. Emerg Infect Dis. 2018;24:1944–6. https://doi.org/10.3201/eid2410.180234
7. Edelstein PH, Roy CR. *Legionella*. In: Bennett JE, Dolin R, Blaser MJ, editors. Mandell, Douglas, and Bennett's principles and practice of infectious diseases, 8th ed. Philadelphia (PA); Elsevier; 2014. p. 2633–44.
8. Pouderoux C, Ginevra C, Descours G, Ranc AG, Beraud L, Boisset S, et al. Slowly or nonresolving Legionnaires' disease: case series and literature review. Clin Infect Dis. 2020;70:1933–40. https://doi.org/10.1093/cid/ciz538
9. Cunha BA, Burillo A, Bouza E. Legionnaires' disease. Lancet. 2016;387:376–85. https://doi.org/10.1016/S0140-6736(15)60078-2
10. Phin N, Parry-Ford F, Harrison T, Stagg HR, Zhang N, Kumar K, et al. Epidemiology and clinical management of Legionnaires' disease. Lancet Infect Dis. 2014;14:1011–21. https://doi.org/10.1016/S1473-3099(14)70713-3

Address for correspondence: Hui Wang, Department of Clinical Laboratory, Peking University People's Hospital, Xicheng District, Beijing, 100044, China; email: wanghui@pkuph.edu.cn

Article DOI: https://doi.org/10.3201/eid2804.211433

Legionella pneumophila Subspecies *fraseri* Infection after Allogeneic Hematopoietic Stem Cell Transplant, China

Appendix

Nanopore Sequencing and Bioinformatic Analysis Pipeline

A nanopore sequencing method that could detect unknown pathogens in 1 hour was adopted to identify the unknown Gram-negative bacilli from the positive blood cultures. The total DNA extraction and libraries preparation steps take 5–6 hours. The total DNA was extracted from 3 mL of positive blood cultures by using the Quick-DNA/RNA TM Viral Kit (Zymo Research, https://www.zymoresearch.com). Sterile deionized water was used as the external negative control. The DNA concentration was determined with the Qubit dsDNA High-Sensitivity (HS) Assay Kit (ThermoFisher Scientific, https://www.thermofisher.com). The ONT libraries were prepared using the PCR Barcoding Kit (SQK-PBK004, Oxford Nanopore Technologies, https://nanoporetech.com). Sequencing was performed using an Oxford Nanopore GridlON X5 instrument (Oxford Nanopore Technologies). The real-time sequencing process was controlled using ONT MinKNOW software version 3.6.5 (Oxford Nanopore Technologies).

The ONT Guppy software version 3.2.10 was applied to process raw sequenced data (fast5 files) into reads (fastq files). Then, the sequencing reads were demultiplexed using the blastn-short (version 2.7.1+) and the lastal (version 980) software, followed by removal of the short (read length ≤500 nt) and low-quality reads (mean q-score ≤8). Subsequently, the host reads were eliminated by aligning them to the human reference genome (GRCh38) using the minimap2 software (version 2.14-r883). The remaining reads were assigned to taxonomy using

Centrifuge software (version 1.0.4) and validated using megablast software (version 2.10.0+). Reads with alignments to multiple bacterial species were excluded from further analyses. Abundance was calculated as the number of reads of a microbe divided by the total number of reads of all microbes.

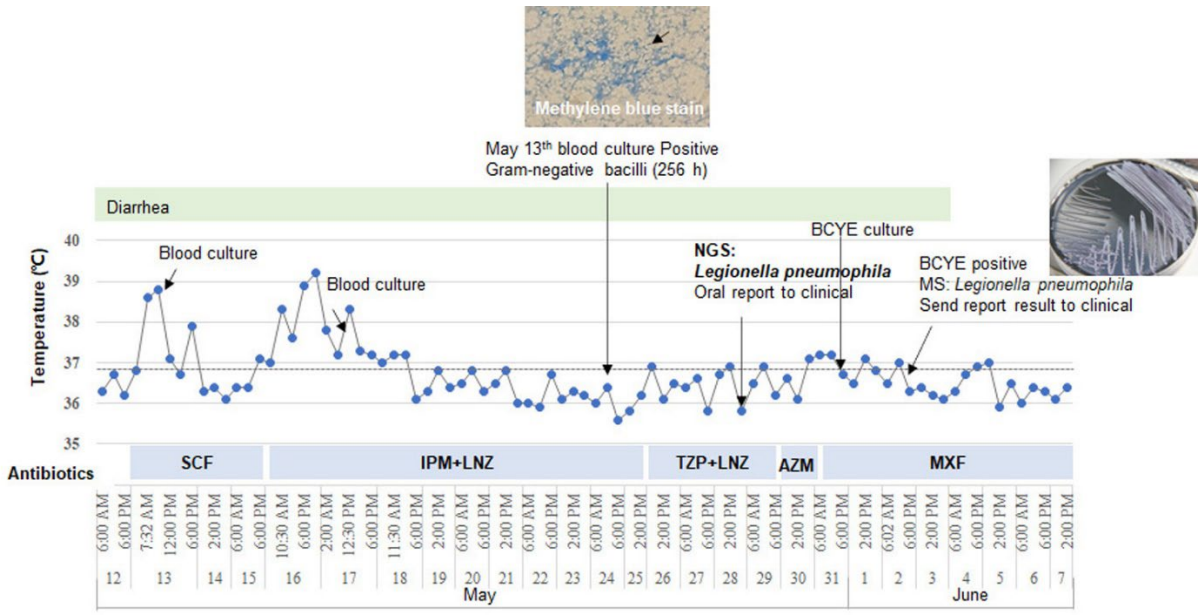

Appendix Figure 1. Temperature, symptoms, and antibiotic therapy of patient with acute infection with *Legionella pneumophila* subsp. *fraseri* after allogeneic hematopoietic stem cell transplantation, China, May 12, 2021–June 7, 2021. The microscopic morphology with methylene blue staining of the positive blood cultures was based on 1 drop (1 mL syringe) syringed from positive blood cultures followed by methylene blue staining. AZM, azithromycin; BCYE, buffered-charcoal yeast extract; IPM, imipenem; LNZ, linezolid; MXF, moxifloxacin; MS, matrix-assisted laser desorption ionization time-of-flight mass spectrometry; SCF, cefoperazone/sulbactam; TZP, piperacillin/tazobactam.

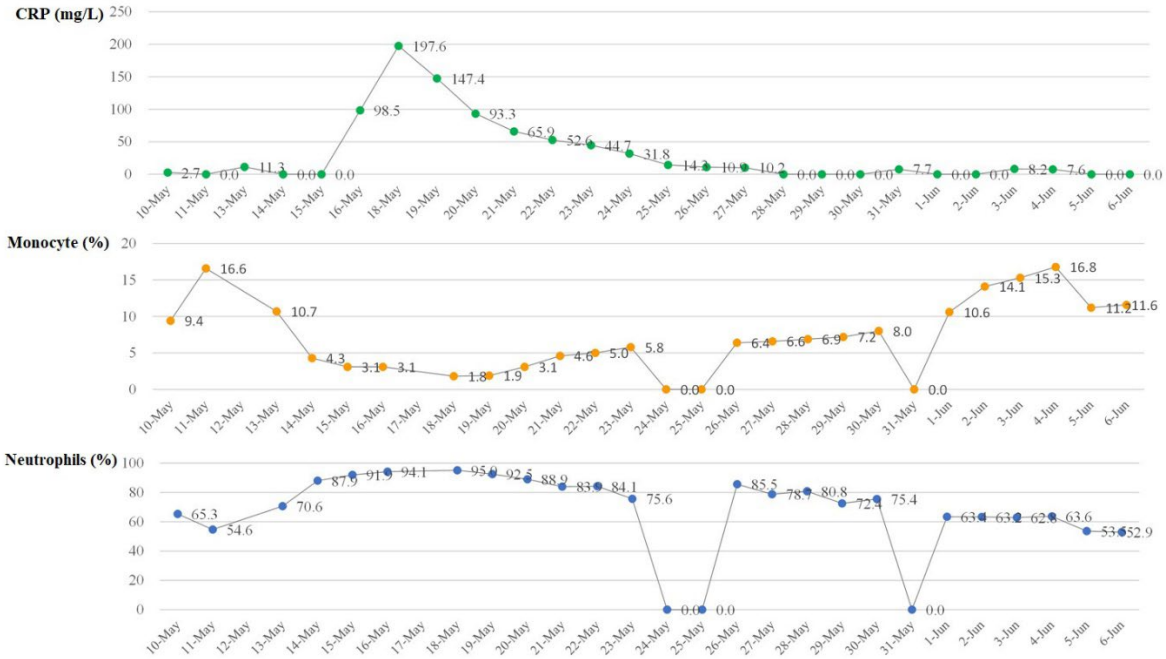

	10-May	11-May	13-May	14-May	15-May	16-May	18-May	19-May	20-May	21-May	22-May	23-May	24-May	25-May	26-May	27-May	28-May	29-May	30-May	31-May	1-Jun	2-Jun	3-Jun	4-Jun	5-Jun	6-Jun
CRP (mg/L)	2.7		11.3			98.5	197.6	147.4	93.3	65.9	52.6	44.7	31.8	14.3	10.9	10.2				7.7			8.2	7.6		
Monocyte (%)	9.4	16.6	10.7	4.3	3.1	3.1	1.8	1.9	3.1	4.6	5.0	5.8			6.4	6.6	6.9	7.2	8.0		10.6	14.1	15.3	16.8	11.2	11.6
Neutrophils (%)	65.3	54.6	70.6	87.9	91.9	94.1	95.0	92.5	88.9	83.9	84.1	75.6			85.5	78.7	80.8	72.4	75.4		63.4	63.2	62.8	63.6	53.5	52.9

Appendix Figure 2. The C-reactive protein (CRP) levels, monocyte percentage and neutrophils percentage trends of patient during acute infection with *Legionella pneumophila* subsp. *fraseri* after allogeneic hematopoietic stem cell transplantation, China, May 10, 2021–June 6, 2021. Values marked with red boxes were higher than normal values. The normal value ranges of CRP, monocyte percentages, and neutrophils percentages are <8 mg/L, 3%–10% and 40%–75%.

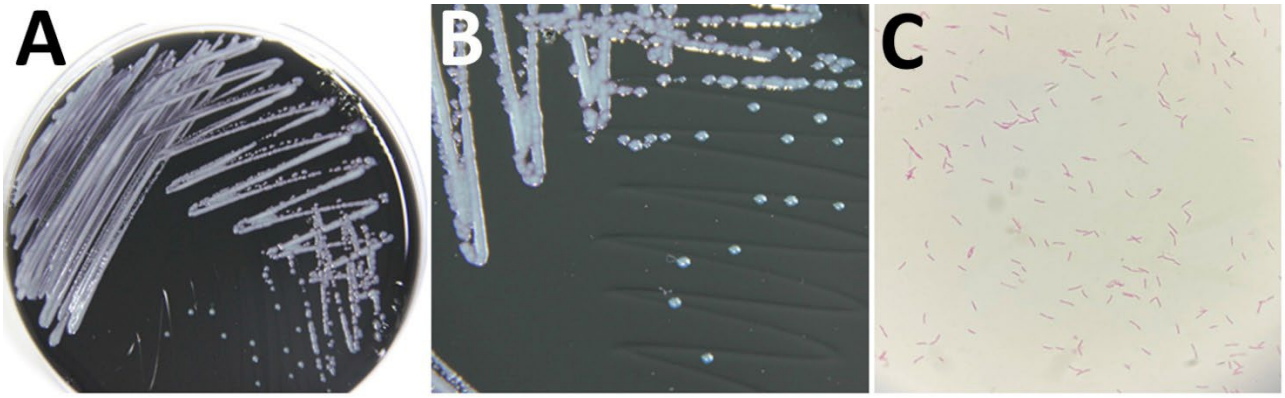
A
B
C