9. Nei T, Sato A, Sonobe K, Miura Y, Takahashi K, Saito R. *Streptobacillus moniliformis* bacteremia in a rheumatoid arthritis patient without a rat bite: a case report. BMC Res Notes. 2015;8:694. https://doi.org/10.1186/s13104-015-1642-6
10. Onodera H, Uekita H, Watanabe T, Taira K, Watanabe C, Saito H, et al. Rat-bite fever due to *Streptobacillus moniliformis* in a patient without bite history: an unexpected cause of consciousness disturbance. Jpn J Infect Dis. 2020; 73:85–7. https://doi.org/10.7883/yoken.JJID.2019.271

Address for correspondence: Satoshi Kutsuna, Disease Control and Prevention Center, National Center for Global Health and Medicine, 1–21–1 Toyama, Shinjuku-ku, Tokyo, 162–8655, Japan; email: skutsuna@hosp.ncgm.go.jp

Autochthonous *Leishmania infantum* in Dogs, Zambia, 2021

David Squarre,[1] Herman M. Chambaro,[1] Kyoko Hayashida,[1] Lavel C. Moonga, Yongjin Qiu, Yasuyuki Goto, Elizabeth Oparaocha, Chisoni Mumba, Walter Muleya, Patricia Bwalya, Joseph Chizimu, Mwelwa Chembensofu, Edgar Simulundu, Wizaso Mwasinga, Nelly Banda, Racheal Mwenda, Junya Yamagishi, King S. Nalubamba, Fredrick Banda, Musso Munyeme, Hirofumi Sawa, Paul Fandamu

Authors affiliations: University of Edinburgh, Edinburgh, Scotland, UK (D. Squarre); Ministry of Fisheries and Livestock, Lusaka, Zambia (D. Squarre, H.M. Chambaro, P. Bwalya, F. Banda, P. Fandamu); Hokkaido University, Sapporo, Japan (H.M. Chambaro, K. Hayashida, L.C. Moonga, Y. Qiu, J. Chizimu, J. Yamagishi, H. Sawa); Central Veterinary Research Institute, Lusaka (H.M. Chambaro, F. Banda); University of Tokyo, Tokyo, Japan (Y. Goto); Showgrounds Veterinary Clinic, Lusaka (E. Oparaocha); University of Zambia, Lusaka (C. Mumba, W. Muleya, M. Chembensofu, E. Simulundu, W. Mwasinga, N. Banda, R. Mwenda, K.S. Nalubamba, M. Munyeme); Macha Research Trust, Macha, Zambia (E. Simulundu); Global Virus Network, Baltimore, Maryland, USA (H. Sawa)

DOI: https://doi.org/10.3201/eid2804.212378

[1]These authors contributed equally to this article

Leishmaniases are neglected tropical diseases of humans and animals. We detected *Leishmania infantum* in 3 mixed-breed dogs in Zambia that had no travel history outside the country. Our findings suggest presence of and probable emergence of leishmaniasis in Zambia, indicating the need for physicians and veterinarians to consider the disease during diagnosis.

Leishmaniasis, a neglected tropical disease of humans and animals, is estimated to affect ≤1 million persons annually (https://www.who.int/health-topics/leishmania). The disease is caused by intracellular protozoan parasites of the genus *Leishmania* (Trypanosomatida: *Trypanosomatidae*), which are vectored by female sand flies of the genera *Phlebotomus* in the Old World and *Lutzomyia* in the New World (*1*). Although leishmaniasis is endemic to several resource-poor countries in eastern, western, and northern Africa, there is a dearth of information on the epidemiology of the disease in southern Africa, largely caused by weak surveillance systems (*1*,*2*).

In Zambia, human visceral leishmaniasis was reported in 1973 in the Eastern Province (*3*) and subsequently in 1976 in the same area (*4*). In 1994, a case of canine visceral leishmaniasis was reported in a dog in Lusaka Province (*5*). We report detection of canine leishmaniasis caused by *Leishmania infantum*, suggesting possible reemergence or reintroduction of the disease in Zambia.

The study was approved by the Department of Veterinary Services, Government of the Republic of Zambia. In June 2021, two female mixed-breed shelter dogs (case 1 and case 2) rescued in Southern Province of Zambia during 2020 were brought to a veterinary clinic in Lusaka. These 2 dogs had chronic weight loss, generalized alopecia, and ulcerative and exfoliative dermatitis (Figure, panel A). The dogs had been previously treated for tickborne and helminth infections but showed no improvement. Physical examination showed that the prescapular and popliteal lymph nodes were enlarged. Case 1 had onychogryphosis (Figure, panel A) and focal corneal opacity in the left eye (Figure, panel B).

Biochemistry profiles for both dogs showed increased levels of serum proteins (>93.3 g/L) and hyperglobulinemia (>74.9 g/L) and hypoalbuminemia (<14.7 g/L), which are common manifestations suggestive of canine leishmaniasis. Giemsa staining of fine-needle lymph node aspirate identified *Leishmania* spp. amastigotes (Figure, panel C).

We performed serologic analysis of *Leishmania* antibodies by using *L. donovani* soluble lysate antigen from cultured promastigotes and recombinant

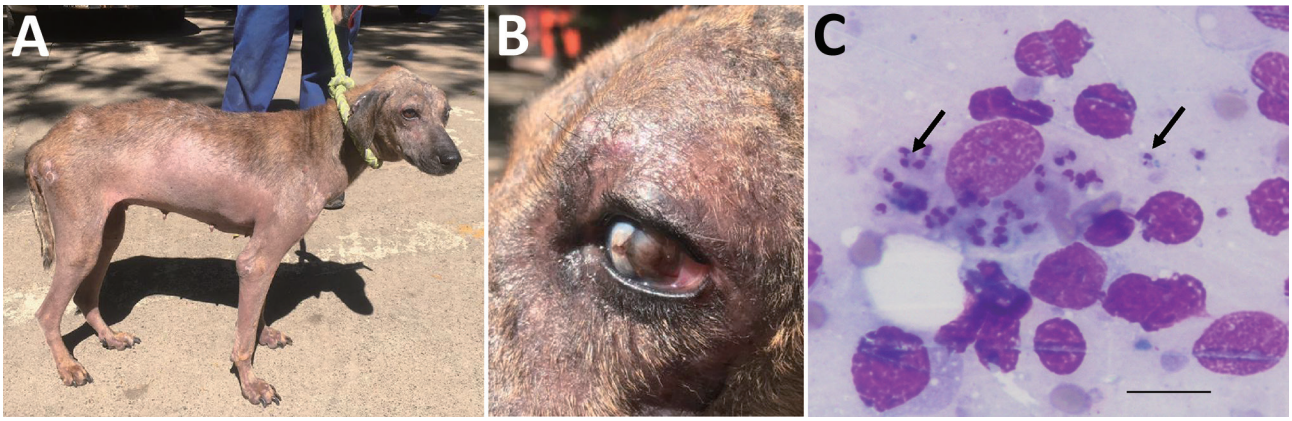

Figure. Clinical manifestations and microscopic imaging of *Leishmania infantum*–infected dog, Zambia. A, B) Dog (case 1) showing dermatitis and onychogryphosis (excessive growth of nails) (A) and focal corneal opacity of the left eye (B). C) Intracellular *Leishmania* amastigotes (black arrows) in fine-needle lymph node aspirate from the same dog. Scale bar indicates 20 μm.

LinJ14.1160r4 antigens as described (*6*). Both dogs had high antibody titers, >1.0 optical density units (Appendix Figure, https://wwwnc.cdc.gov/EID/article/28/4/21-2378-App1.pdf). Among in-contact dogs from Southern Province that had no clinical signs (n = 6), 1 dog (case 3) had high antibody titers for both assays, and 2 dogs (dogs 6 and 7) had high antibody titers for LinJ14.1160r4 only. All control serum samples (n = 39) from Central Province were negative for *Leishmania* antibodies on both assays (Appendix Figure). For the purpose of disease control and the absence of antileishmanial agents in Zambia, the dogs (cases 1 and 2) were euthanized by rapid intravenous infusion of pentobarbitone sodium (0.7 mL/kg body weight). Case 3, an in-contact dog that showed high antibody titers for both assays, was euthanized 1 month after clinical disease was detected and the initial diagnosis.

At necropsy, we aseptically harvested spleen tissue and processed this tissue for genomic DNA extraction by using the QuickGene DNA Tissue Kit (Kurabo, https://www.kurabo.co.jp) according to the manufacturer's protocol. We performed PCRs targeting the partial small subunit ribosomal RNA gene (*7*) and internal transcribed spacer (ITS) 1 and ITS 2 genes (*8*). PCR for 3 dogs showed expected band sizes, which we purified and sequenced on a 3500 Genetic Analyzer (Applied Biosystems, https://www.thermofisher.com). Sequences obtained were 100% identical with the *L. infantum* reference strain (JPCM5) isolated in Spain (*9*). The ITS sequence type was type A, which was assigned according to 12 microsatellite regions in ITS1 and ITS2 within the *L. donovani* complex (*8*). ITS type A is the dominant *L. infantum* type reported mainly from the Mediterranean basin, and types D, E, F, and G are associated with *L. donovani* from eastern Africa (*8*). Nucleotide sequences from this study were deposited in the DNA DataBank of Japan (GenBank accession nos. LC652643–LC652645).

Our study confirmed the presence and probable emergence of leishmaniasis and *Leishmania* parasites in Zambia. An in-contact, seropositive dog that did not have clinical signs had clinical disease develop 1 month after the initial diagnosis. However, the probable route of infection remains unclarified.

Although the geographic distribution of vector sandflies has not been described in Zambia, neighboring countries have reported presence of *Phlebotomus* spp. sand flies (*10*). In addition, although the extent of disease distribution in the country, including Southern Province, is yet to be determined, autochthonous leishmania cases reported in Zambia (*3*–*5*) suggests the presence of an infection foci. To further clarify the epidemiology of leishmaniasis in Zambia, there is need for improved understanding of the epidemiology of the disease in dogs, vector distribution, and the risk for human infection, particularly in high-risk populations, such as immunocompromised persons.

This study was supported in part by the Department of Veterinary Services under the Ministry of Fisheries and Livestock of the Government of the Republic of Zambia, the Japan Agency for Medical Research and Development (JP21wm0125008), and the Lusaka Animal Welfare Society.

About the Author

Dr. Squarre is a state wildlife veterinarian in Lusaka, Zambia. His research interests include molecular epidemiology of emerging and reemerging zoonosis in free-ranging wildlife and domestic animals and their interaction at the human-wildlife–livestock interface.

References

1. Alvar J, Vélez ID, Bern C, Herrero M, Desjeux P, Cano J, et al.; WHO Leishmaniasis Control Team. Leishmaniasis worldwide and global estimates of its incidence. PLoS One. 2012;7:e35671. https://doi.org/10.1371/journal.pone.0035671
2. Otranto D, Dantas-Torres F, Mihalca AD, Traub RJ, Lappin M, Baneth G. Zoonotic parasites of sheltered and stray dogs in the era of the global economic and political crisis. Trends Parasitol. 2017;33:813–25. https://doi.org/10.1016/j.pt.2017.05.013
3. Hira PR, Naik KG, Egere JU. Letter: kala-azar in Zambia. Lancet. 1973;302:1026–7. https://doi.org/10.1016/S0140-6736(73)91117-3
4. Naik KG, Hira PR, Bhagwandeen SB, Egere JU, Versey AA. Kala-azar in Zambia: first report of two cases. Trans R Soc Trop Med Hyg. 1976;70:328–32. https://doi.org/10.1016/0035-9203(76)90090-0
5. Matsukawa K, Chiti L, Yoshima M, Sayer PD. Canine visceral leishmaniosis: first case in Zambia. Onderstepoort J Vet Res. 1997;64:77–9.
6. Goto Y, Carter D, Guderian J, Inoue N, Kawazu S, Reed SG. Upregulated expression of B-cell antigen family tandem repeat proteins by *Leishmania* amastigotes. Infect Immun. 2010;78:2138–45. https://doi.org/10.1128/IAI.01102-09
7. Meredith SE, Zijlstra EE, Schoone GJ, Kroon CC, van Eys GJ, Schaeffer KU, et al. Development and application of the polymerase chain reaction for the detection and identification of *Leishmania parasites* in clinical material. Arch Inst Pasteur Tunis. 1993;70:419–31.
8. el Tai NO, Osman OF, el Fari M, Presber W, Schönian G. Genetic heterogeneity of ribosomal internal transcribed spacer in clinical samples of *Leishmania donovani* spotted on filter paper as revealed by single-strand conformation polymorphisms and sequencing. Trans R Soc Trop Med Hyg. 2000;94:575–9. https://doi.org/10.1016/S0035-9203(00)90093-2
9. González-de la Fuente S, Peiró-Pastor R, Rastrojo A, Moreno J, Carrasco-Ramiro F, Requena JM, et al. Resequencing of the *Leishmania infantum* (strain JPCM5) genome and de novo assembly into 36 contigs. Sci Rep. 2017;7:18050. https://doi.org/10.1038/s41598-017-18374-y
10. Seccombe AK, Ready PD, Huddleston LM. A catalogue of Old World phlebotomine sandflies (Diptera: Psychodidae, Phlebotominae). (Occasional papers on systematic entomology, number 8.) Portsmouth (UK): Natural History Museum; 1993.

Address for correspondence: Herman M. Chambaro, Ministry of Fisheries and Livestock, Department of Veterinary Services, Central Veterinary Research Institute, PO Box 33980, Lusaka, Zambia; email: hermcham@gmail.com

Pseudo-Outbreak of *Bordetella parapertussis* Caused by Contaminated Swabs in the Netherlands

Jacky Flipse, Angelino T. Tromp, Janneke Bosman, Christine ten Hove, Hans Beks, Titia Kortbeek, Guido J.H. Bastiaens, Ellen M. Mascini

Author affiliations: Rijnstate, Arnhem, the Netherlands (J. Flipse, A.T. Tromp, J. Bosman, C. ten Hove, G.J.H. Bastiaens, E.M. Mascini); Safety and Public Health Services Gelderland Midden, Arnhem (H. Beks); National Institute for Public Health and the Environment, Bilthoven, the Netherlands (T. Kortbeek)

DOI: https://doi.org/10.3201/eid2804.212097

An increase in positive *Bordetella parapertussis* tests among patients in a teaching hospital in the Netherlands resulted in enhanced infection control and microbiological surveillance. Further analysis revealed that batches of contaminated nasopharyngeal swabs were associated with a pseudo-outbreak, resulting in incorrect diagnoses, antimicrobial treatments, isolation precautions, and public health notifications.

We report a pseudo-outbreak of *Bordetella parapertussis* in the Department of Pediatrics in Rijnstate, an 809-bed teaching hospital in the Netherlands. The department provides level II care to infants, neonates, and preterm infants. In March 2021, we diagnosed *B. parapertussis* in 3 infants hospitalized for respiratory symptoms by using an in-house PCR against insertion sequences (IS) *IS481* and *IS1001* (*1*). During calendar week 21 (Figure), we identified more *B. parapertussis* cases in the same department, bringing the total case count to 5 in neonates, 1 in a toddler, and 6 in infants. Several of these patients were born prematurely.

PCR-positive case-patients had pertussis-like complaints, and we confirmed *B. parapertussis* in the patients or their siblings. We traced all positive tests to the Department of Pediatrics. Because we suspected nosocomial transmission, we started contact tracing investigations among parents and healthcare workers (HCWs) and identified *B. parapertussis* in another 4 patients and in 3 HCWs.

Cases among HCWs were particularly unexpected. Because of the coronavirus disease (COVID-19) pandemic, all HCW were using type IIR surgical masks and keeping ≥1.5 m distance from each other. In addition, all patients had private rooms, and we observed no increase in other respiratory pathogens.

Article DOI: https://doi.org/10.3201/eid2804.212378

Autochthonous *Leishmania infantum* in Dogs, Zambia, 2021

Appendix

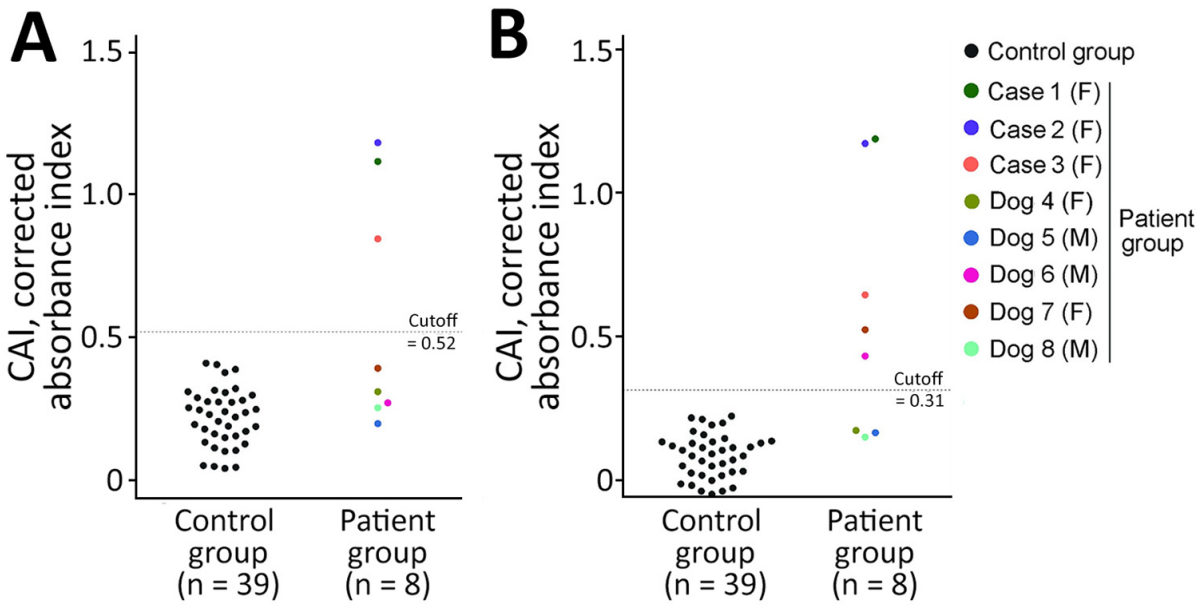

Reference

1. Goto Y, Carter D, Guderian J, Inoue N, Kawazu S, Reed SG. Upregulated expression of B-cell antigen family tandem repeat proteins by *Leishmania* amastigotes. Infect Immun. 2010;78:2138–45. PubMed https://doi.org/10.1128/IAI.01102-09