our case highlights the challenges of genotypic resistance prediction in uncommon RGM species.

In summary, we report a case of *M. iranicum* CRB-SI that was treated successfully with catheter removal and 2 weeks of amikacin and imipenem followed by 4 weeks of de facto monotherapy with trimethoprim/sulfamethoxazole. This case illustrates the value of using next generation sequencing to identify novel pathogens and the challenges of choosing appropriate treatment because of limited knowledge of drug-resistance mechanisms.

About the Author

Dr. Ranson is an infectious diseases fellow at the University of California, Los Angeles, CA. Her primary research interests focus on care delivery for people living with HIV and injection drug users.

References

1. Grandjean Lapierre S, Toro A, Drancourt M. *Mycobacterium iranicum* bacteremia and hemophagocytic lymphohistiocytosis: a case report. BMC Res Notes. 2017;10:372. https://doi.org/10.1186/s13104-017-2684-8
2. Shojaei H, Daley C, Gitti Z, Hashemi A, Heidarieh P, Moore ERB, et al. *Mycobacterium iranicum* sp. nov., a rapidly growing scotochromogenic species isolated from clinical specimens on three different continents. Int J Syst Evol Microbiol. 2013;63:1383–9. PubMed https://doi.org/10.1099/ijs.0.043562-0
3. Tan JL, Ngeow YF, Wee WY, Wong GJ, Ng HF, Choo SW. Comparative genomic analysis of *Mycobacterium iranicum* UM_TJL against representative mycobacterial species suggests its environmental origin. Sci Rep. 2014;4:7169. https://doi.org/10.1038/srep07169
4. Griffith DE, Aksamit T, Brown-Elliott BA, Catanzaro A, Daley C, Gordin F, et al.; ATS Mycobacterial Diseases Subcommittee; American Thoracic Society; Infectious Disease Society of America. An official ATS/IDSA statement: diagnosis, treatment, and prevention of nontuberculous mycobacterial diseases. Am J Respir Crit Care Med. 2007;175:367–416. https://doi.org/10.1164/rccm.200604-571ST
5. Rodriguez-Coste MA, Chirca I, Steed LL, Salgado CD. Epidemiology of rapidly growing *Mycobacteria* bloodstream infections. Am J Med Sci. 2016;351:253–8. https://doi.org/10.1016/j.amjms.2015.12.012
6. El Helou G, Viola GM, Hachem R, Han XY, Raad II. Rapidly growing mycobacterial bloodstream infections. Lancet Infect Dis. 2013;13:166–74. https://doi.org/10.1016/S1473-3099(12)70316-X
7. Martín-de-Hijas NZ, García-Almeida D, Ayala G, Fernández-Roblas R, Gadea I, Celdrán A, et al. Biofilm development by clinical strains of non-pigmented rapidly growing mycobacteria. Clin Microbiol Infect. 2009;15:931–6. https://doi.org/10.1111/j.1469-0691.2009.02882.x
8. Price TK, Realegeno S, Mirasol R, Tsan A, Chandrasekaran S, Garner OB, et al. Validation, implementation, and clinical utility of whole genome sequence-based bacterial identification in the clinical microbiology laboratory. J Mol Diagn. 2021;23:1468–77. https://doi.org/10.1016/j.jmoldx.2021.07.020
9. Realegeno S, Mirasol R, Garner OB, Yang S. Clinical whole genome sequencing for clarithromycin and amikacin resistance prediction and subspecies identification of *Mycobacterium abscessus*. J Mol Diagn. 2021;23:1460–7. https://doi.org/10.1016/j.jmoldx.2021.07.023
10. El Helou G, Hachem R, Viola GM, El Zakhem A, Chaftari AM, Jiang Y, et al. Management of rapidly growing mycobacterial bacteremia in cancer patients. Clin Infect Dis. 2013;56:843–6. https://doi.org/10.1093/cid/cis1032

Address for correspondence: Elizabeth L. Ranson, UCLA Division of Infectious Diseases, David Geffen School of Medicine at UCLA, 10833 Le Conte Ave, 52-215CHS, Los Angeles, CA, 90095, USA; email: eranson@mednet.ucla.edu

Monkeypox Virus Infection in 18-Year-Old Woman after Sexual Intercourse, France, September 2022

Alexandre Vallée, Audrey Chatelain, Marie Carbonnel, Catherine Racowsky, Erwan Fourn, David Zucman, Jean-Marc Ayoubi

Author affiliations: Foch Hospital, Suresnes, France (A. Vallée, A. Chatelain, M. Carbonnel, C. Racowsky, E. Fourn, D. Zucman, J.-M. Ayoubi); University of Versailles, Versailles, France (A. Chatelain, M. Carbonnel, J.-M. Ayoubi)

DOI: https://doi.org/10.3201/eid2901.221643

A monkeypox virus outbreak has spread worldwide since April 2022. We report a young woman in France positive for monkeypox virus transmitted through oral and vaginal sex. Ulceronecrotic lesions developed intravaginally and around her vulva. Health professionals should become familiar with all aspects of infection from this virus, including possible vertical transmission.

A monkeypox virus (MPXV) outbreak has spread worldwide since April 2022. Although the risk to the general public was previously considered low, the World Health Organization is now responding to this outbreak as a high priority to avoid further spread (*1*). The community of men who have sex with men appears to be particularly exposed (*2*), although

rare cases among women have been described. We report a sexually transmitted case of MPXV with typical genital lesions in a young woman in France. The study was approved by the Institutional Review Board of Foch Hospital (IRB no. IRB00012437 [approval no. 22-10-02]), Suresnes, France. Written consent for publication was obtained from the patient for clinical information and photographs. Deidentified data were securely transferred and stored.

On September 7, 2022, an 18-year-old woman sought care at the outpatient clinic of Foch Hospital for symptoms such as fever, myalgia, and multiple eruptions on her vulva that began 7 days earlier (Figure). She reported a headache began on September 2, 2022, followed by feverish episodes on September 2 that stopped on September 7. The first eruptions appeared on September 2 on the gluteal area and then spread. Rashes on her hands and wrists appeared on September 7. At examination, the patient showed no odynophagia, coughing, or sputum. A gynecological examination showed ulceronecrotic lesions around the vulva and intravaginally. The cutaneous lesions were infracentimetric pustules located on the torso, fingers, and palms of the hands and above the intergluteal groove. We observed bilateral laterocervical and inguinal lymphadenopathies, but no axillary lymphadenopathy or anal lesions were evident.

Tests for chlamydia and gonococcus on pharyngeal and self-collected anal swabs were negative, and no previous sexually transmitted infections were

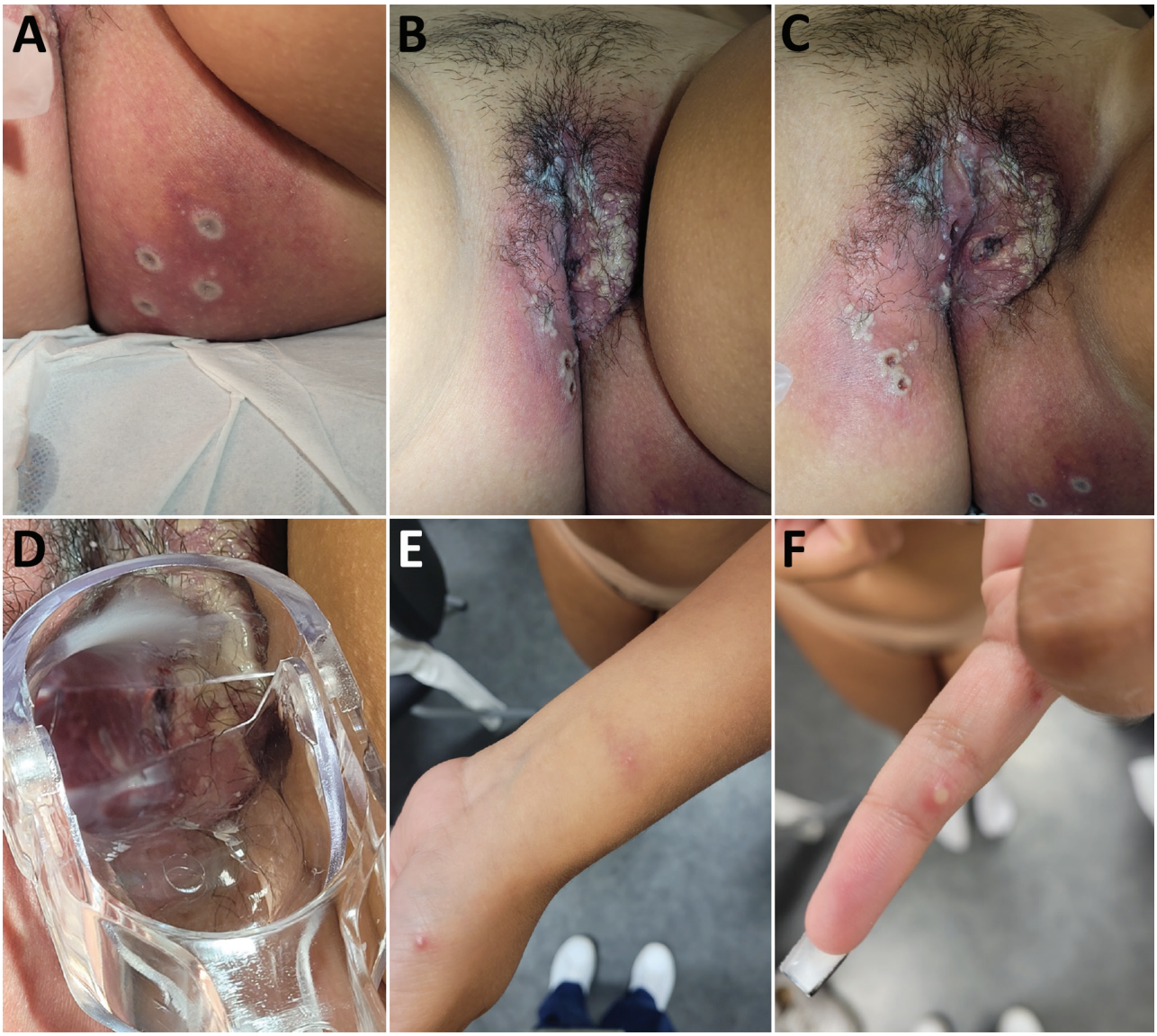

Figure. Pustules in gluteal area (A), genital area (B, C), intravaginal area (D), arm and hand (E), and finger (F) in young woman with monkeypox virus infection after sexual intercourse, France, September 2022.

reported for the patient or her boyfriend. Tests for HIV, syphilis, herpes, toxoplasmosis, rubella, and hepatitis (A, B, and C) were all negative for both persons. A real-time reverse transcription PCR, designed at the French National Reference Center of Orthopoxvirus, was performed on a pharyngeal swab sample from the patient on September 7 and tested positive for MPXV on September 8.

The patient had been in a relationship for 9 months with her boyfriend and had only had vaginal and oral intercourse with him; the most recent intercourse was 8 days before her first symptoms. On August 25, 2022, after a vacation in the southwest of France, her boyfriend began experiencing fever, pimples on his penis, and swollen inguinal glands. His rashes disappeared on September 1. We have no additional information for him. The main transmission hypothesis for MPXV in this case is oral and vaginal sex with the patient's boyfriend. She was not hospitalized but placed in confinement in her home. On October 12, the patient was seen at Foch Hospital for follow up, at which time the rashes were beginning to disappear (Appendix, https://wwwnc.cdc.gov/EID/article/29/1/22-1643-App1.pdf).

Most current MPXV outbreaks in Europe have involved young men who have sex with men who attend festivals and other public events (*3*). Conversely, data regarding MPXV cases in women are sparse; only a few cases have been reported in the literature (*4*). To date, only a small proportion of infections have been reported in women; only 1.2% of total cases in Europe have been reported in women (*5*). Our patient had a regular sexual partner who had MPXV symptoms, thus reinforcing that sexual transmission might play a predominant role in the outbreak (*2*).

Pharyngitis and rectal symptoms are being increasingly described as occurring after traditional skin lesions in MPXV infections (*6*), although these symptoms were not evident in our patient. The most reported clinical symptoms are painful perianal and genital lesions, together with fever, lymphadenopathy, headache, and malaise. Classic cases of MPXV included a febrile prodrome followed by generalized rash, although the ongoing outbreak has been characterized mainly by painless anogenital lesions, often without a prodrome. However, because of observed variability in clinical manifestations, the spread of the current MPXV outbreak might be underestimated.

To date, only 10 cases in pregnancy have been reported worldwide, predominantly in Brazil and the United States (*7*). Those cases were mainly reported by local media, and none were severe. However, studies in pregnant women remain limited. A transplacental transmission to the fetus might be responsible for congenital MPXV, although no cases of fetal malformations or death have been reported. Nevertheless, cases of vertical transmission with clinical signs of MPXV infection, such as cutaneous maculopapular lesions on the head, trunk, and extremities and hydrops, have been reported (*8*). A neonate born from an infected mother in the United States received prophylactic vaccinia immunoglobin and did not develop MPXV disease. Of note, the ACAM2000 vaccine (Sanofi, https://www.sanofi.com) is contraindicated during pregnancy because it is a vaccinia virus (live virus); other vaccines, such as third-generation vaccines (LC16m8 or JYNNEOS [Bavarian Nordic, https://www.bavariannordic.com]), are preferred in pregnant women (*9*). It is imperative that health professionals become familiar with all aspects of this disease affecting women (*10*).

About the Author

Dr. Vallée is head of the department of Epidemiology, Data, and Biostatistics at Foch Hospital, Suresnes, France. His primary research interests are epidemiology and clinical research.

References

1. Thornhill JP, Barkati S, Walmsley S, Rockstroh J, Antinori A, Harrison LB, et al.; SHARE-net Clinical Group. Monkeypox virus infection in humans across 16 countries—April–June 2022. N Engl J Med. 2022;387:679–91. https://doi.org/10.1056/NEJMoa2207323
2. Vallée A, Farfour E, Zucman D. Monkeypox virus: a novel sexually transmitted disease? A case report from France. Travel Med Infect Dis. 2022;49:102394. https://doi.org/10.1016/j.tmaid.2022.102394
3. Antinori A, Mazzotta V, Vita S, Carletti F, Tacconi D, Lapini LE, et al.; INMI Monkeypox Group. Epidemiological, clinical and virological characteristics of four cases of monkeypox support transmission through sexual contact, Italy, May 2022. Euro Surveill. 2022;27. https://doi.org/10.2807/1560-7917.ES.2022.27.22.2200421
4. Adler H, Gould S, Hine P, Snell LB, Wong W, Houlihan CF, et al.; NHS England High Consequence Infectious Diseases (Airborne) Network. Clinical features and management of human monkeypox: a retrospective observational study in the UK [Erratum in: Lancet Infect Dis. 2022;22:e177]. Lancet Infect Dis. 2022;22:1153–62. https://doi.org/10.1016/S1473-3099(22)00228-6
5. Vaughan AM, Cenciarelli O, Colombe S, Alves de Sousa L, Fischer N, Gossner CM, et al. A large multi-country outbreak of monkeypox across 41 countries in the WHO European Region, 7 March to 23 August 2022. Euro Surveill. 2022;27. https://doi.org/10.2807/1560-7917.ES.2022.27.36.2200620
6. Basgoz N, Brown CM, Smole SC, Madoff LC, Biddinger PD, Baugh JJ, et al. Case 24-2022: a 31-year-old man with perianal and penile ulcers, rectal pain, and rash. N Engl J Med. 2022;387:547–56. https://doi.org/10.1056/NEJMcpc2201244
7. Khalil A, Samara A, O'Brien P, Coutinho CM, Duarte G, Quintana SM, et al. Monkeypox in pregnancy: update on current outbreak. Lancet Infect Dis. 2022;22:1534–5.

8. D'Antonio F, Pagani G, Buca D, Khalil A. Monkeypox infection in pregnancy: a systematic review and metaanalysis. Am J Obstet Gynecol MFM. 2022;5:100747. https://doi.org/10.1016/j.ajogmf.2022.100747
9. Poland GA, Kennedy RB, Tosh PK. Prevention of monkeypox with vaccines: a rapid review. Lancet Infect Dis. 2022 Sep 15 [Epub ahead of print].
10. Kozlov M. Monkeypox outbreaks: 4 key questions researchers have. Nature. 2022;606:238–9. https://doi.org/10.1038/d41586-022-01493-6

Address for correspondence: Alexandre Vallée, Department of Epidemiology-Data-Biostatistics, Delegation of Clinical Research and Innovation (DRCI), Foch Hospital, 92150, Suresnes, France; email: al.vallee@hopital-foch.com

Monkeypox Virus Infection in 22-Year-Old Woman after Sexual Intercourse, New York, USA

Nawras Zayat, Shirley Huang, Jude Wafai, Melissa Philadelphia

Author affiliations: State University of New York Downstate Health Sciences University, Brooklyn, New York, USA (N. Zayat, S. Huang); St. George's University School of Medicine, West Indies, Grenada (J. Wafai); Kings County Hospital Center, Brooklyn (M. Philadelphia)

DOI: https://doi.org/10.3201/eid2901.221662

We report a case of a 22-year-old woman in New York, USA, who had painful vulvar and intravaginal lesions after sexual intercourse and tested positive for monkeypox virus. Literature documenting the clinical manifestations of monkeypox in female genitalia remains insufficient.

We report monkeypox virus infection in a 22-year-old woman with no remarkable medical history who sought care at the Kings County Hospital Center (Brooklyn, NY, USA) emergency department with numerous painful vulvar and intravaginal lesions. The patient reported a sexual encounter with 1 male partner 2.5 weeks before. She reported that they had vaginal sex and noted that her partner had a few dark bumps on his penis that resembled ingrown hairs. It was unknown if this partner had any sexually transmitted infections.

Two weeks after the encounter, the patient experienced onset of myalgias, fatigue, and fever. Two days after the onset of fever, she first noticed 3 mildly painful flesh-colored bumps, which progressed the following day and became white in color and more numerous. The lesions prompted the patient to go to the emergency department at an outside hospital. At arrival, the patient was febrile to 100.7° F. She underwent screening for sexually transmitted infections, including testing for monkeypox. She was discharged home with prescriptions of lidocaine, bacitracin, and ibuprofen as needed for pain while laboratory results were pending.

On day 3 after the lesions first appeared, they became larger and more painful, to the point of causing substantial distress when the woman sat, and had spread toward her perianal region. On day 4 after the lesions' appearance, the woman could no longer tolerate the pain and went to the emergency department at Kings County Hospital Center. At arrival, her temperature was 98.4° F, heart rate was 63 beats/min, respiratory rate was 18 breaths/min, and blood pressure was 118/72 mm Hg. Gynecologic examination revealed numerous singular, raised lesions that were umbilicated, ulcerated, vesicular, papular, and pustular, in different stages (Figure). The right labia majora was erythematous without any induration or fluctuance. We observed no lymphadenopathy on examination to the inguinal regions bilaterally. The vagina and cervix appeared normal otherwise. The uterus was small and mobile, and we noted no adnexal masses or tenderness. We observed no cutaneous lesions elsewhere in the body. Results of heart, lung, abdominal, and neurologic examinations were unremarkable.

The patient was tested for gonorrhea, chlamydia, HIV, herpes simplex virus, syphilis, and monkeypox. The patient also underwent a vulvar biopsy because the gynecology team was unfamiliar with the type of genital lesions she was experiencing. While waiting for the test results, the patient was informed by her male partner that he had tested positive for monkeypox virus earlier that day. The patient was admitted to the hospital and began a 14-day course of tecovirimat (600 mg every 12 h) with accompanying isolation precautions for 21 days as per the recommendations of the physicians within Kings County Hospital's Infectious Disease department. All results of laboratory tests were negative except for a positive PCR result for monkeypox virus. The

Article DOI: https://doi.org/10.3201/eid2901.221643

Monkeypox Virus Infection in 18-Year-Old Woman after Sexual Intercourse, France, September 2022

Appendix

Timeline of Monkeypox Virus Infection

August 25, 2022: Boyfriend develops fever and rashes.

August 26, 2022: Oral and vaginal intercourse between the woman and her boyfriend

September 1, 2022: Rashes disappear in boyfriend (no additional information available).

September 2, 2022: Feverish episode for the female

September 2, 2022: First eruptions on gluteal area for woman (photographed on September 7, 2022) (Appendix Figure 1)

September 3, 2022: First eruptions on genital area (photographed on September 7, 2022) (Appendix Figure 2)

September 7, 2022: Clinical visit at Foch Hospital, Suresnes, France. Rashes on hands and wrists of the woman have developed (photographed on September 7, 2022) (Appendix Figure 3)

September 7, 2022: Intravaginal lesions (photographed on September 7, 2022) (Appendix Figure 4)

September 8, 2022: Woman tests positive for monkeypox virus by reverse transcription PCR positive

October 12, 2022: Second visit at Foch Hospital. Beginning of disappearance of rashes for woman (photographed on October 12, 2022) (Appendix Figure 5)

Appendix Figure 1. Pustules in gluteal area of young woman with monkeypox virus infection after sexual intercourse, France, September 2022

Appendix Figure 2. Pustules in genital area of young woman with monkeypox virus infection after sexual intercourse, France, September 2022

Appendix Figure 3. Pustules on arm, hand, and finger of young woman with monkeypox virus infection after sexual intercourse, France, September 2022

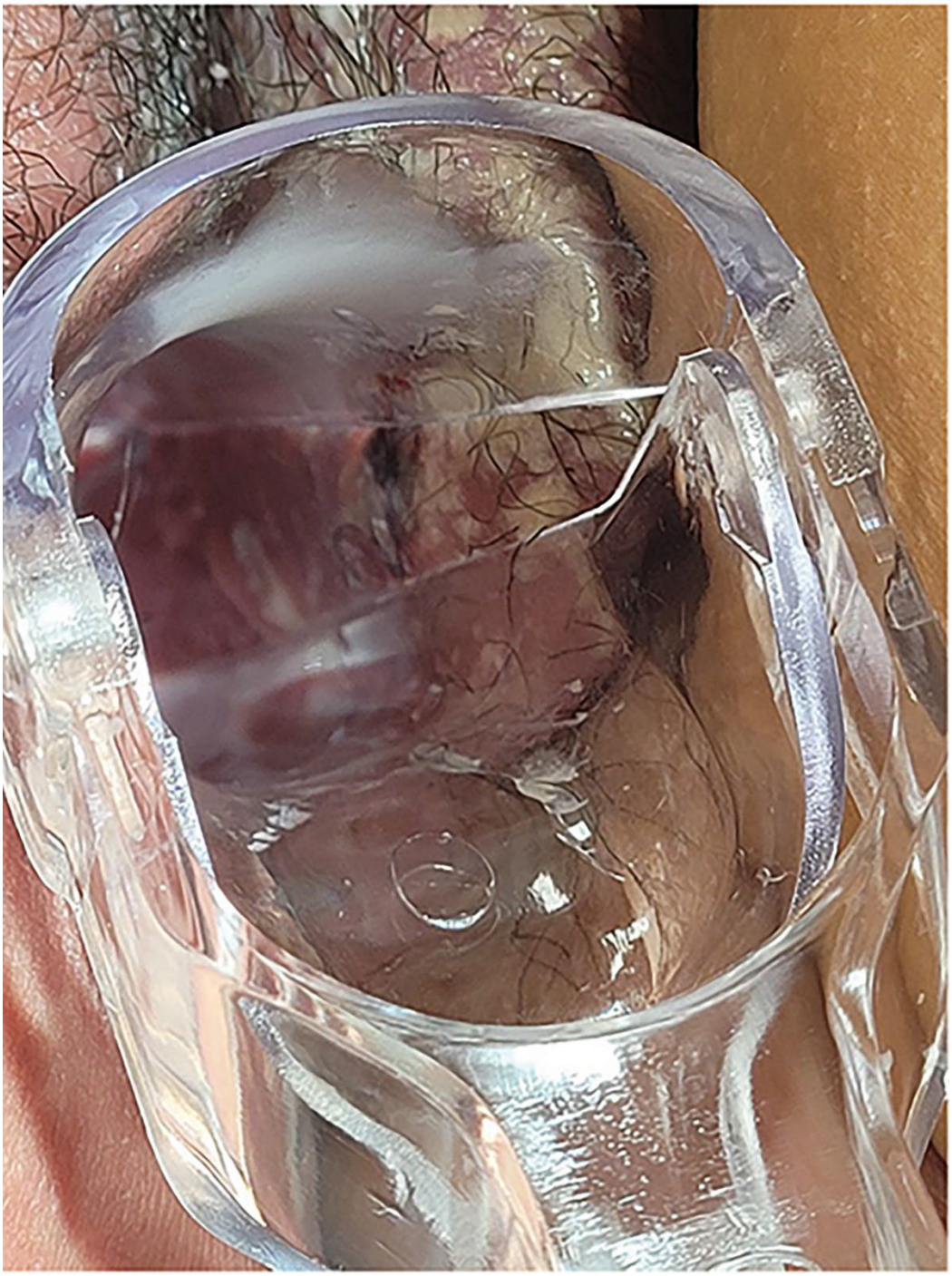

Appendix Figure 4. Pustules in intravaginal area of young woman with monkeypox virus infection after sexual intercourse, France, September 2022

Appendix Figure 5. Healing pustules in young woman with monkeypox virus infection after sexual intercourse, France, September 2022