This study was funded by the Consultative Group for International Agricultural Research (CGIAR) COVID-19 Hub and the CGIAR Initiative "Protecting human health through a One Health approach."

About the Author

Dr. Bui is a research scientist and leader in the Department of Virology, National Institute of Veterinary Research, Hanoi, Vietnam. His research interests are molecular epidemiology, pathogenesis of viruses, and viral diseases. Dr. Dao is a research scientist in the Department of Virology, National Institute of Veterinary Research. His research interests include molecular epidemiology, biology, and bioinformatics analysis of influenza virus, coronavirus, foot-and-mouth disease virus, classical swine fever, African swine fever, porcine reproductive and respiratory syndrome, porcine circovirus type 2, hepatitis E virus, dengue virus, and other viruses.

References

1. World Health Organization. Protocol: real-time RT-PCR assays for the detection of SARS-CoV-2. 2020 [cited 2023 Jan 20]. https://www.who.int/docs/default-source/coronaviruse/real-time-rt-pcr-assays-for-the-detection-of-sars-cov-2-institut-pasteur-paris.pdf?sfvrsn=3662fcb6_2
2. Killington RA. Stokes A, Hierholzer JC. Virus purification. In: Mahy BWJ, Kangro HO, editors. Virology method manual. New York: Academic Press; 1996. p. 71–89 [cited 2023 Jan 20]. https://www.sciencedirect.com/book/9780124653306/virology-methods-manual
3. Xiu L, Binder RA, Alarja NA, Kochek K, Coleman KK, Than ST, et al. A RT-PCR assay for the detection of coronaviruses from four genera. J Clinical Virol. 2020; 128:104391.
4. Thompson JD, Higgins DG, Gibson TJ. CLUSTAL W: improving the sensitivity of progressive multiple sequence alignment through sequence weighting, position-specific gap penalties and weight matrix choice. Nucleic Acids Res. 1994;22:4673–80. https://doi.org/10.1093/nar/22.22.4673
5. Kumar S, Stecher G, Li M, Knyaz C, Tamura K. MEGA X: molecular evolutionary genetics analysis across computing platforms. Mol Biol Evol. 2018;35:1547–9. https://doi.org/10.1093/molbev/msy096

Address for correspondence: Hu Suk Lee, International Livestock Research Institute, Regional Office for East and Southeast Asia, Room 301-302, B1 Building, Van Phuc Diplomatic Compound, 298 Kim Ma St, Ba Dinh District, Hanoi, Vietnam; email: H.S.Lee@cgiar.org; or Hu Suk Lee, College of Veterinary Medicine, Chungnam National University, Daejeon, South Korea; email: hs.lee@cnu.ac.kr

Emergence of *Mycobacterium orygis*–Associated Tuberculosis in Wild Ruminants, India

Megha Sharma, Karikalan Mathesh, Premanshu Dandapat, Asok Kumar Mariappan, Ravi Kumar, Soni Kumari, Vivek Kapur, Sushila Maan, Naresh Jindal, Nitish Bansal, Riyaz Kadiwar, Abhishek Kumar, Nitin Gupta, A.M. Pawde, A.K. Sharma

Author affiliations: Indian Council of Agricultural Research—Indian Veterinary Research Institute, Izatnagar, India (M. Sharma, K. Mathesh, A.K. Mariappan, R. Kumar, S. Kumari, A.M. Pawde, A.K. Sharma); Indian Council of Agricultural Research—Indian Veterinary Research Institute, Eastern Regional Station, Kolkata, India (P. Dandapat); Pennsylvania State University, University Park, Pennsylvania, USA (V. Kapur); Lala Lajpat Rai University of Veterinary and Animal Sciences, Hisar, India (S. Maan, N. Jindal, N. Bansal); Sakkarbaug Zoological Garden, Junagarh, India (R. Kadiwar, A. Kumar); Bandhavgarh National Park, Madhya Pradesh, India (N. Gupta)

DOI: https://doi.org/10.3201/eid2903.221228

Tuberculosis caused by *Mycobacterium orygis* was detected in 2 spotted deer from a wildlife sanctuary in western India and an Indian bison from a national park in central India. Nationwide surveillance is urgently required to clarify the epidemiology of the *Mycobacterium tuberculosis* complex at the human–livestock–wildlife interface.

Tuberculosis (TB) caused by *Mycobacterium orygis* has been reported in humans, cattle, and, rarely, wild animals in India (*1*–*3*). We report 3 cases of *M. orygis*–associated TB in wild animals from among 85 unexplained deaths screened as part of disease investigations during February 2016–March 2020, which also revealed cases of suppurative bronchopneumonia (n = 32), TB caused by *M. tuberculosis* or *M. bovis* (n = 29), verminous pneumonia (n = 9), fungal granulomas (n = 6), and neoplasms (n = 6).

In February 2016, two adult free-range spotted deer (a male [case 1] and a female [case 2]) were found dead in Girnar Wildlife Sanctuary, Gujarat, western India. Postmortem examination revealed nonuniform, multifocal, coalescing pale-yellow nodules embedded in the parenchyma of the lungs with caseated yellowish-white material and enlarged liver and mesenteric lymph nodes with surface nodules. In January 2017, an emaciated adult male bison (case 3) was found dead at Bandhavgarh National Park, Madhya Pradesh, central

India. Similar to the deer, the bison had variable-sized white caseous nodules on the visceral pleura, superficial lung parenchyma, and pulmonary lymph nodes.

To investigate the causative agent, tissues from the lungs, liver, and lymph nodes were collected on ice and 10% neutral buffered formalin and processed for histopathology, Ziehl-Neelsen staining, and culture isolation. Histopathologic examination of these tissues revealed large granulomas with extensive caseous necrosis and multiple calcified areas surrounded by epithelioid cells, lymphocytes, giant cells, and fibroblasts (most abundant in case 3). Acid-fast bacilli were abundant (50–75/oil immersion field), both extracellularly and within the macrophages. We cultured all samples in triplicate in Löwenstein–Jensen media with glycerol and in Löwenstein–Jensen with sodium pyruvate, which revealed moist, smooth, and granular colonies (*4*). Primary screening of bacterial isolates by single-tube multiplex PCR that targets the 16S rRNA, specific for the *Mycobacterium* genus, and MPB70 genes, specific for members of MTBC, confirmed that the isolates were MTBC (*5*). We performed further PCR on the MTBC-positive samples to determine the presence or absence of genomic regions of difference (RD4 and RD9) using published primers (*6*); this testing indicated the absence of RD9 and presence of RD4, thus excluding the possibility of *M. tuberculosis*, *M. canetti*, *M. bovis*, or *M. bovis* BCG in all 3 cases.

To determine the exact species of MTBC involved and their genetic similarities with strains affecting livestock and humans circulating in India, we performed paired-end whole-genome sequencing on the Illumina MiSeq platform (https://www.illumina.com). The presence of standard genetic markers for *M. orygis* (RD1, RD4, and Rv044c) and the absence of RD9 and RD12 confirmed our sequences as *M. orygis*. We submitted the whole-genome data generated to the National Center for Biotechnology Information Sequence Read Archive database under accession nos. SRX15482219 (case 1), SRX6969199 (case 2), and SRX6969201 (case 3).

We phylogenetically compared the sequences generated in this study with other available *M. orygis* sequences. The phylogenetic branching patterns

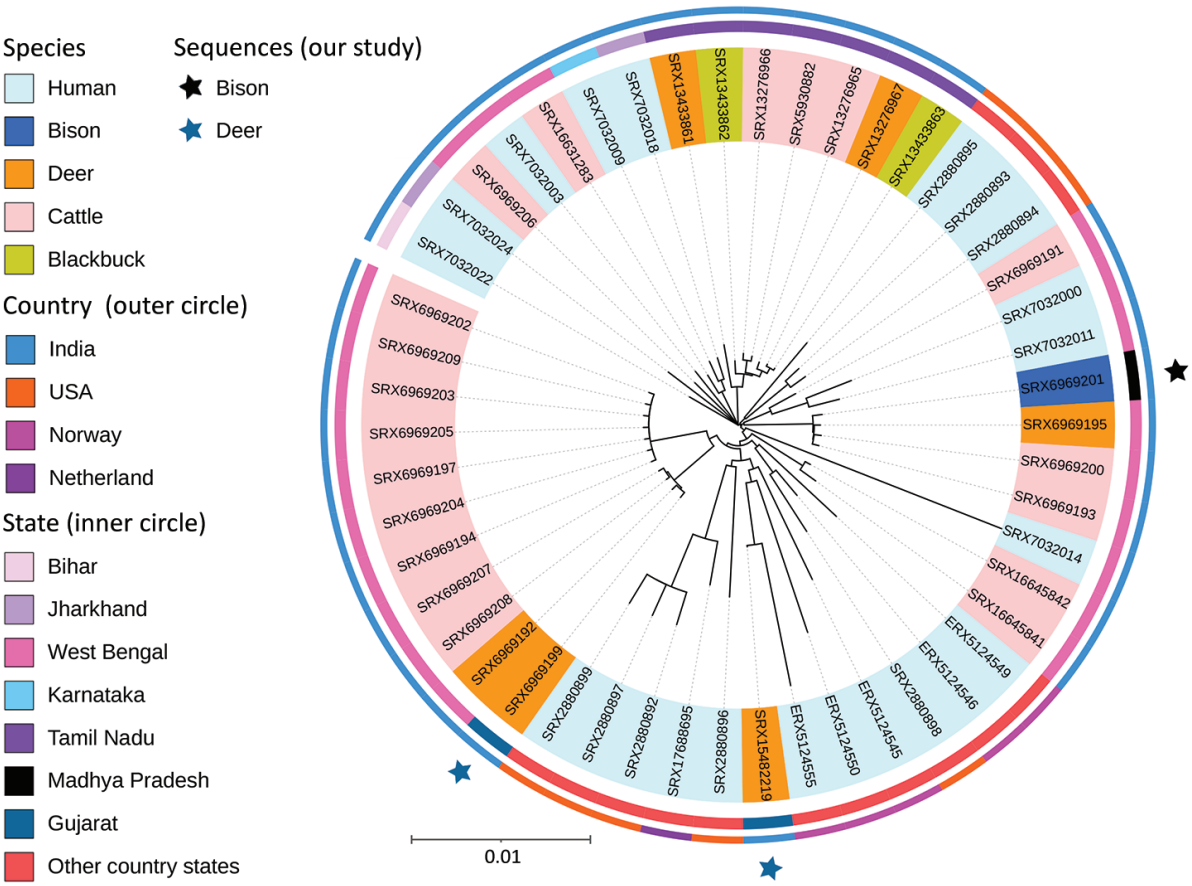

Figure. Phylogeny of newly sequenced *Mycobacterium orygis* wildlife isolates from 3 wild animals in India (black star, bison; blue stars, deer) and reference sequences. The outer circle shows the distribution of isolates in India, Norway, the Netherlands, and the United States. The inner circle shows the statewise distribution within countries. Shading of branch labels corresponds to different species. Scale bar of 0.01 indicates 1 change for every 100 nucleotides.

suggest that the isolate from the case 1 spotted deer was genetically closer to the isolate recovered from the bison (case 3) than the case 2 deer isolate (Figure 1). The average pairwise difference across all the isolates in this study was 272; it was 73 between the isolates. The restricted diversity observed among several of the newly described isolates, including those recovered from among free-living wildlife, is noteworthy and requires future investigations.

Recently, *M. orygis* has emerged as a zoonotic threat in south Asia (*7*); multispecies cases have been reported in India involving humans, dairy cattle, and wild ungulates (*1*–*3*,*7*,*8*). Studies from Nepal and Bangladesh have also revealed the circulation of *M. orygis* in free-ranging wild animals and cattle, which indicates the possibility of *M. orygis* in the India multihost wildlife system (*9*). Reports on the transmission of *M. orygis* infection from an India-origin farm worker to cattle in New Zealand (*10*) and the confirmation of *M. orygis* in 10 human patients in south Asia (*2*) imply endemicity in the region, highlighting the urgent need for genomic epidemiologic investigations.

We report the circulation of *M. orygis* in free-ranging wildlife populations in India, suggesting an unexplored threat to wildlife conservation in regions where various endangered species coexist. In this study, the transmission dynamics of *M. orygis* are unknown; however, spillover and spillback episodes might have occurred because of the shared space and resources at the livestock-wildlife-human interface. In India, human population explosion has led to encroachment on forest areas and shrinking wildlife habitats, which has increased the threat of pathogen transmission among wildlife, livestock, and humans. Although the epidemiology has not been defined, phylogenetic analysis in our study and previous reports indicate that *M. orygis* appears to be circulating in wild animal, human, and livestock populations in India. In light of the World Health Organization End TB Strategy, nationwide screening and continuous surveillance under the umbrella of the One Health approach should be conducted to combat this deadly zoonotic disease.

Acknowledgments

We thank the director of the Indian Council of Agricultural Research—Indian Veterinary Research Institute, the forest departments of Madhya Pradesh and Gujarat and Central Zoo Authority, Government of India for providing necessary permission to conduct this research.

This study received financial contribution from the Department of Biotechnology, Ministry of Science and Technology, Government of India (grant no. BT/ADV/Bovine Tuberculosis/2018).

About the Author

Dr. Sharma is pursuing a PhD in the division of Veterinary Pathology at the Indian Council of Agricultural Research—Indian Veterinary Research Institute (IVRI). Her primary research interests are livestock, poultry, and wildlife disease epidemiology and pathology.

References

1. Refaya AK, Kumar N, Raj D, Veerasamy M, Balaji S, Shanmugam S, et al. Whole-genome sequencing of a *Mycobacterium orygis* strain isolated from cattle in Chennai, India. Microbiol Resour Announc. 2019;8:e01080–19. https://doi.org/10.1128/MRA.01080-19
2. Duffy SC, Srinivasan S, Schilling MA, Stuber T, Danchuk SN, Michael JS, et al. Reconsidering *Mycobacterium bovis* as a proxy for zoonotic tuberculosis: a molecular epidemiological surveillance study. Lancet Microbe. 2020;1:e66–73. https://doi.org/10.1016/S2666-5247(20)30038-0
3. Refaya AK, Ramanujam H, Ramalingam M, Rao GVS, Ravikumar D, Sangamithrai D, et al. Tuberculosis caused by *Mycobacterium orygis* in wild ungulates in Chennai, South India. Transbound Emerg Dis. 2022;69:e3327–33. https://doi.org/10.1111/tbed.14613
4. Thapa J, Nakajima C, Maharjan B, Poudell A, Suzuki Y. Molecular characterization of *Mycobacterium orygis* isolates from wild animals of Nepal. Jpn J Vet Res. 2015;63:151–8.
5. Wilton S, Cousins D. Detection and identification of multiple mycobacterial pathogens by DNA amplification in a single tube. PCR Methods Appl. 1992;1:269–73. https://doi.org/10.1101/gr.1.4.269
6. Warren RM, Gey van Pittius NC, Barnard M, Hesseling A, Engelke E, de Kock M, et al. Differentiation of *Mycobacterium tuberculosis* complex by PCR amplification of genomic regions of difference. Int J Tuberc Lung Dis. 2006;10:818–22.
7. Rahim Z, Thapa J, Fukushima Y, van der Zanden AGM, Gordon SV, Suzuki Y, et al. Tuberculosis caused by *Mycobacterium orygis* in dairy cattle and captured monkeys in Bangladesh: a new scenario of tuberculosis in South Asia. Transbound Emerg Dis. 2017;64:1965–9. https://doi.org/10.1111/tbed.12596
8. van Ingen J, Rahim Z, Mulder A, Boeree MJ, Simeone R, Brosch R, et al. Characterization of *Mycobacterium orygis* as *M. tuberculosis* complex subspecies. Emerg Infect Dis. 2012;18:653–5. https://doi.org/10.3201/eid1804.110888
9. Thapa J, Nakajima C, Gairhe KP, Maharjan B, Paudel S, Shah Y, et al. Wildlife tuberculosis: an emerging threat for conservation in South Asia. In: Lameed GA, editor. Global exposition of wildlife management. London: InTechOpen Limited; 2017. p. 73–90.
10. Dawson KL, Bell A, Kawakami RP, Coley K, Yates G, Collins DM. Transmission of *Mycobacterium orygis* (*M. tuberculosis* complex species) from a tuberculosis patient to a dairy cow in New Zealand. J Clin Microbiol. 2012;50:3136–8. https://doi.org/10.1128/JCM.01652-12

Address for correspondence: Karikalan Mathesh, Center for Wildlife, ICAR-Indian Veterinary Research Institute, Izatnagar-243122, Uttar Pradesh, India; email: karyvet11@gmail.com; Premanshu Dandapat, ICAR-Indian Veterinary Research Institute, Eastern Regional Station, Kolkata (WB), India; email: pdandapat@gmail.com

Article DOI: https://doi.org/10.3201/eid2903.221228

Emergence of *Mycobacterium orygis*–Associated Tuberculosis in Wild Ruminants, India

Appendix

Appendix Figure 1. Weak and debilitated carcasses of spotted deer (A) and bison (B) affected with TB

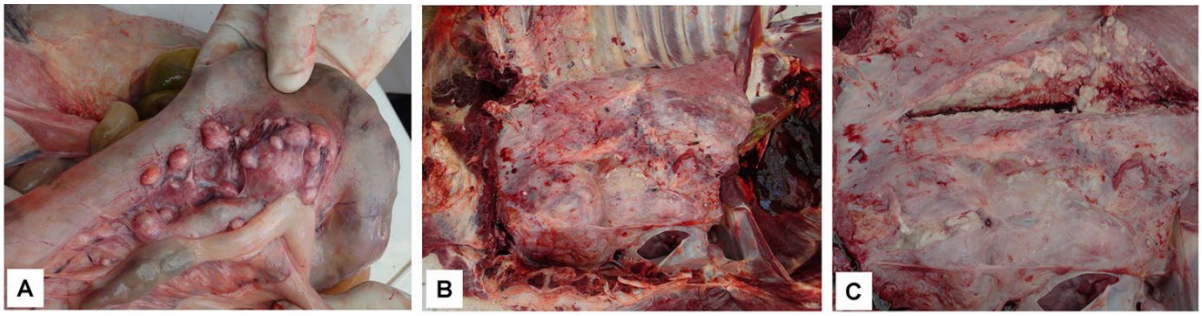

Appendix Figure 2. Spotted deer, enlarged mesenteric lymph nodes (A) showing tuberculous nodules. Multiple poorly demarcated coalescing nodules filled with pale-white caseous material (B & C)

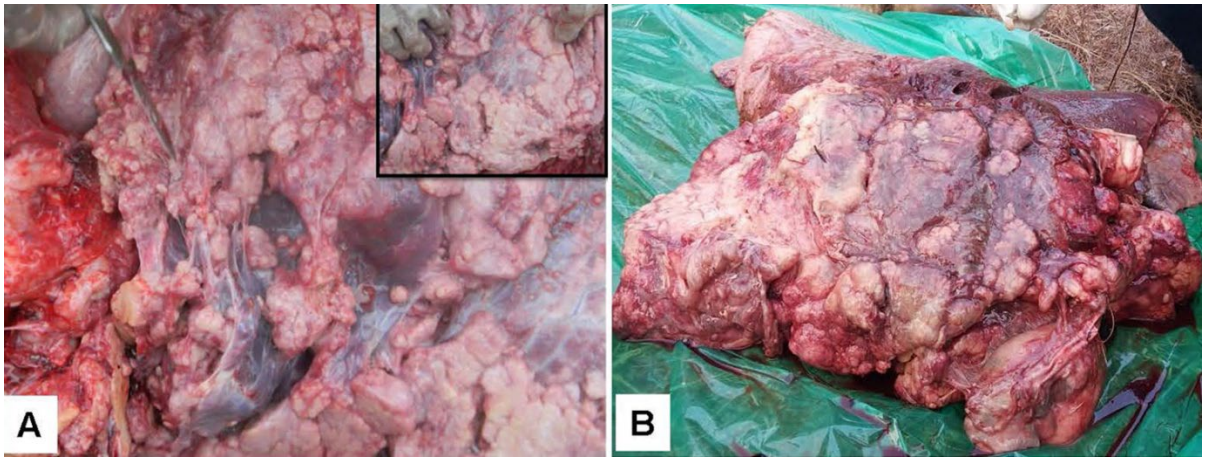

Appendix Figure 3. Bison, multifocal to coalescing, poorly demarcated, variable-sized white caseous nodules on the visceral pleura (A) and the lung parenchyma (B)

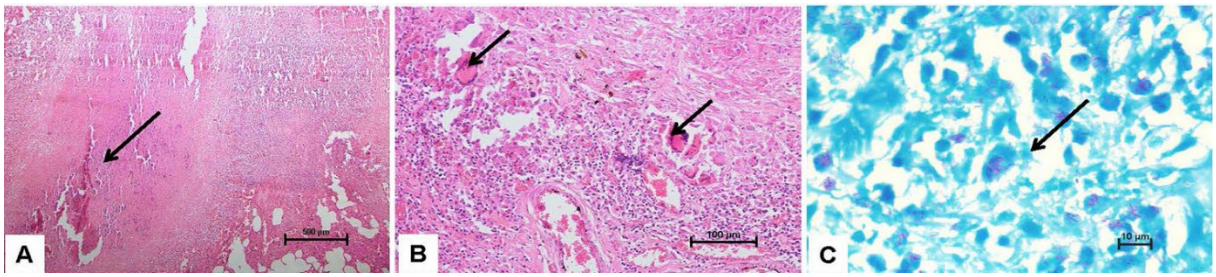

Appendix Figure 4. Spotted deer, lung showing extensive caseo-calcified areas (arrow) surrounded by inflammatory cells with associated emphysema (A) H&E ×40. Higher magnification showing epithelioid cells and giant cells in the periphery of granuloma (B) (arrows) H&E ×200 and acid-fast bacilli inside macrophages (C) ZN ×1000

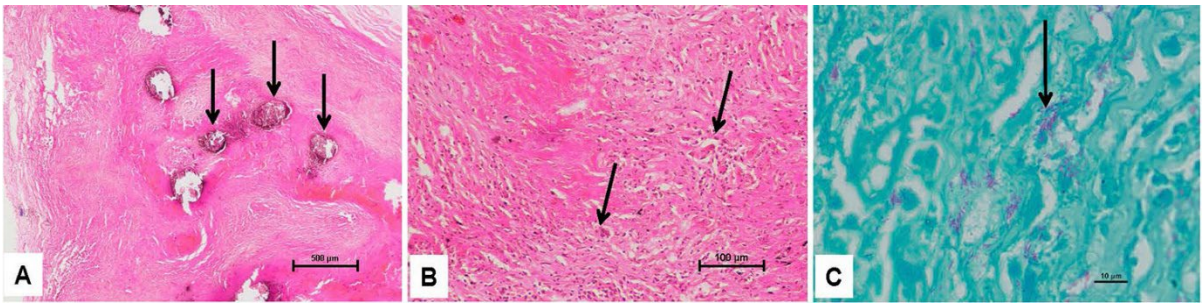

Appendix Figure 5. Bison, lung showing multiple caseo-calcified granulomas (arrows) in the visceral pleura with associated fibrosis (A) H&E ×40. Higher magnification showing attempts of giant cells formation (arrows) in the periphery of granuloma with extensive fibroblasts proliferation (B) H&E ×200 and acid-fast bacteria (arrow) in the caseative granuloma (C) ZN × 1000

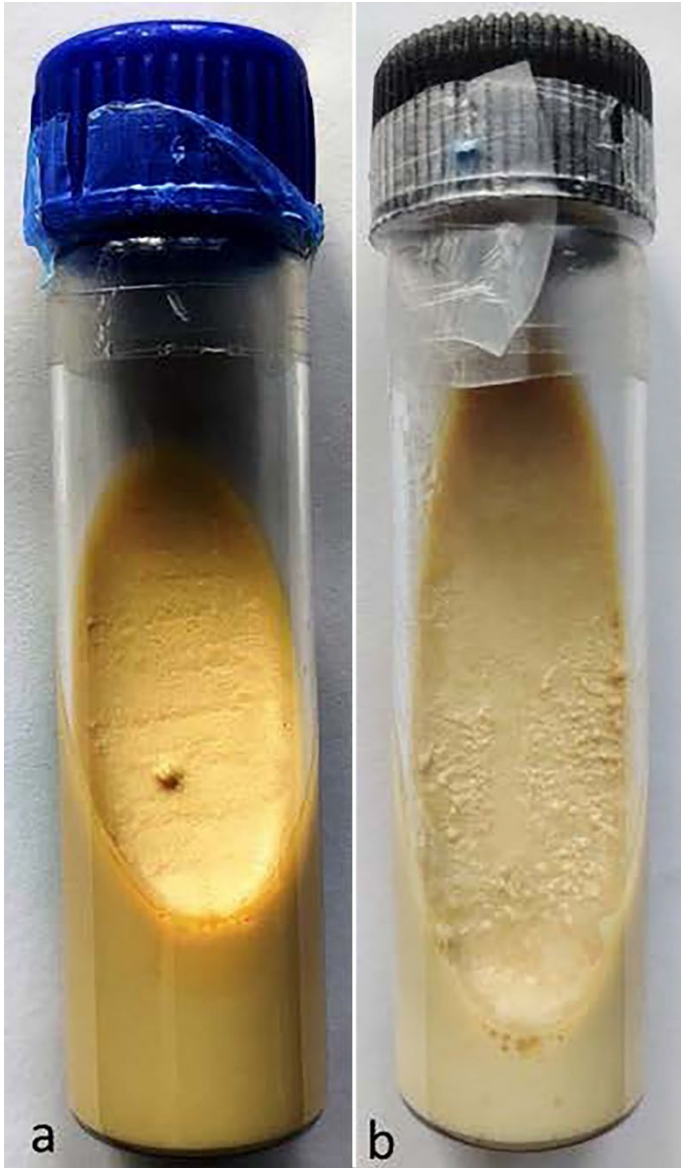

Appendix Figure 6. Granular and moist colonies of *M. orygis* from spotted deer (a) and bison (b) in Löwenstein–Jensen medium (LJ) supplemented with pyruvate for 4 weeks