References:

1. Zhao AV, Crutchley RD, Guduru RC, Ton K, Lam T, Min AC. A clinical review of HIV integrase strand transfer inhibitors (INSTIs) for the prevention and treatment of HIV-1 infection. Retrovirology. 2022;19:22. https://doi.org/10.1186/s12977-022-00608-1
2. Ghazvini K, Keikha M. Human Monkeypox resurgence 2022; a new presentation as a sexual pathogen. Ann Med Surg (Lond). 2022;80:104267. https://doi.org/10.1016/j.amsu.2022.104267
3. Angelo KM, Smith T, Camprubí-Ferrer D, Balerdi-Sarasola L, Díaz Menéndez M, Servera-Negre G, et al.; GeoSentinel Network Collaborators. Epidemiological and clinical characteristics of patients with monkeypox in the GeoSentinel Network: a cross-sectional study. Lancet Infect Dis. 2022;S1473-3099(22)00651-X. https://doi.org/10.1016/S1473-3099(22)00651-X
4. Patrocinio-Jesus R, Peruzzu F. Monkeypox genital lesions. N Engl J Med. 2022;387:66–66. https://doi.org/10.1056/NEJMicm2206893
5. Brundu M, Marinello S, Scaglione V, Ferrari A, Franchin E, Mazzitelli M, et al. The first case of monkeypox virus and acute HIV infection: should we consider monkeypox a new possible sexually transmitted infection? J Dermatol. 2022;1346-8138.16556. https://doi.org/10.1111/1346-8138.16556
6. Boesecke C, Monin MB, van Bremen K, Schlabe S, Hoffmann C. Severe monkeypox-virus infection in undiagnosed advanced HIV infection. Infection. 2022;50:1633–4. https://doi.org/10.1007/s15010-022-01901-z
7. de Sousa D, Patrocínio J, Frade J, Correia C, Borges-Costa J, Filipe P. Human monkeypox coinfection with acute HIV: an exuberant presentation. Int J STD AIDS. 2022;33:936–8. https://doi.org/10.1177/09564624221114998
8. Bížová B, Veselý D, Trojánek M, Rob F. Coinfection of syphilis and monkeypox in HIV positive man in Prague, Czech Republic. Travel Med Infect Dis. 2022;49:102368. https://doi.org/10.1016/j.tmaid.2022.102368
9. Nolasco S, Vitale F, Geremia A, Tramuto F, Maida CM, Sciuto A, et al. First case of monkeypox virus, SARS-CoV-2 and HIV co-infection. J Infect. 2022;S0163-4453(22)00479-0. https://doi.org/10.1016/j.jinf.2022.08.014
10 Hughes CM, Liu L, Davidson WB, Radford KW, Wilkins K, Monroe B, et al. A tale of two viruses: coinfections of monkeypox and varicella zoster virus in the Democratic Republic of Congo. Am J Trop Med Hyg. 2020;104:604–11. https://doi.org/10.4269/ajtmh.20-0589

Address for correspondence: Rachel Burdon, Department of Sexual Health Medicine, Sydney Local Health District, 16 Marsden St, Camperdown, NSW 2050, Australia; email: Rachel.Burdon@health.nsw.gov.au

Intrahost Monkeypox Virus Genome Variation in Patient with Early Infection, Finland, 2022

Hanna Vauhkonen, Hannimari Kallio-Kokko, Eija Hiltunen-Back, Lasse Lönnqvist, Jaana Leppäaho-Lakka, Laura Mannonen, Ravi Kant, Tarja Sironen, Satu Kurkela, Maija Lappalainen, Tomaž Mark Zorec, Samo Zakotnik, Doroteja Vlaj, Miša Korva, Tatjana Avšič-Županc, Mario Poljak, Teemu Smura, Olli Vapalahti

Author affiliations: University of Helsinki, Helsinki, Finland (H. Vauhkonen, R. Kant, T. Sironen, T. Smura, O. Vapalahti); University of Helsinki and Helsinki University Hospital, Uusimaa, Finland (H. Kallio-Kokko, L. Mannonen, S. Kurkela, M. Lappalainen, T. Smura, O. Vapalahti); University of Helsinki and Helsinki University Hospital, Helsinki (E. Hiltunen-Back, L. Lönnqvist); Hospital Nova of Central Finland, Helsinki (J. Leppäaho-Lakka); University of Ljubljana, Ljubljana, Slovenia (T.M. Zorec, S. Zakotnik, D. Vlaj, M. Korva, T. Avšič-Županc, M. Poljak)

DOI: https://doi.org/10.3201/eid2903.221388

Monkeypox virus was imported into Finland during late May–early June 2022. Intrahost viral genome variation in a sample from 1 patient comprised a major variant with 3 lineage B.1.3–specific mutations and a minor variant with ancestral B.1 nucleotides. Results suggest either ongoing APOBEC3 enzyme–mediated evolution or co-infection.

During 2022, an unprecedented multicountry outbreak of monkeypox virus (MPXV) infection among humans was detected. The first verified mpox cases in Europe were reported in mid-May 2022 with no apparent link to MPXV-endemic countries, but patients shared travel history to Lisbon, Portugal, and Gran Canaria, Canary Islands, as well as sexual behavior (men who have sex with men [MSM]) (*1*). The first draft sequence of the outbreak-related genome from Portugal was published on May 19, 2022 (J. Isidro, unpub. data, https://virological.org/t/first-draft-genome-sequence-of-monkeypox-virus-associated-with-the-suspected-multi-country-outbreak-may-2022-confirmed-case-in-portugal/799). During the following weeks, several closely related MPXV genomes were reported from other countries in Europe, resulting from travel-associated and community-transmitted infections. The clinical picture of those infections (anogenital lesions or rash and enlarged

inguinal lymph nodes) (*2*), together with the epidemiologic data, suggested human-to-human transmission by sexual contact, mainly among MSM (*3*); however, other routes of transmission may also have played roles (*4*). As the number of verified mpox cases increased, on July 23, 2022, the World Health Organization declared MPXV a Public Health Emergency of International Concern (https://www.who.int/director-general/speeches), although the epidemic has since waned. We describe the molecular and clinical characteristics of MPXV introduced to Finland during late May–early June 2022 (Table). The patients provided written informed consent for use of their case details and medical images in this study.

We investigated 4 patients who exhibited systemic mpox symptoms, such as fever and skin lesions (Appendix, https://wwwnc.cdc.gov/EID/article/29/3/22-1388-App1.pdf). The patients were epidemiologically unrelated to each other; however, all reported travel in southern Europe, declared themselves to be MSM, and declared recent unprotected sexual exposure with previously unknown partners (Table). Two patients were HIV positive. Orthopoxvirus real-time PCR of individual skin lesion samples detected orthopoxvirus, which was later verified as MPXV by hemagglutinin gene sequencing with MinION (Oxford Nanopore Technologies, https://nanoporetech.com) (Appendix). The sample from patient 1 was also sequenced by MinION and on May 27, 2022, produced an MPXV draft genome. The whole genomes of all samples were subsequently sequenced by using Illumina NovaSeq (https://www.illumina.com). As of November 8, 2022, the total number of verified cases in Finland reached 42, but no further virus transmission from those patients has been reported.

We obtained complete MPXV genomes from 3 of the 4 patients: patient 1 (penis, quantitative cycle [Cq] 19.77), patient 2 (face, Cq 26.29), and patient 4 (perianal skin, Cq 23.4); we could obtain only a fragmental genome from patient 3 (hand, Cq 33.38). In the phylogenetic analysis, the consensus sequence of MPXV genome from patient 1 (GenBank accession no. ON782021) clustered with lineage B.1.3 genomes (Figure). The members of that cluster share 3 substitutions: nonsynonymous G55133A (R665C in OPG074 protein), synonymous C64426T, and nonsynonymous G190660A (R84K in NTB03_gb174 protein), according to National Center for Biotechnology Information reference sequence NC_063383 coordinates (equivalent to the mutations addressed as G55142A, C64435T, G190675A [*5*]). The sequence from patient 2 (GenBank accession no. ON782022) was identical to the early sequences first detected in Portugal (*6*) and thereafter in various other countries. The sequence from patient 4 (GenBank accession no. ON959143) had 4 nt substitutions: C89906T (OPG110: S92F), G94798A (OPG115: E47K), C150831T, and C188491T. Two of those sequences (C89906T and G94798A) were shared with genomes from the United Kingdom, Portugal, Spain, and Germany.

The 3 nt substitutions detected in the patient 1 sequence were not fixed but rather contained minority variants with the frequencies of 10% (G55133A, depth 2231; nucleotide counts G = 233, A = 1997), 12% (C64426T, depth 2685; C = 308, T = 2364), and 13% (G190660A, depth 2685; G = 280, A = 1872). On the other hand, in the members of the same clade from Slovenia (GenBank accession no. ON609725) and France (GenBank accession no. ON622722), all 3 mutations were fixed (allele frequency >99.7%). The mutational signature of the major and minor intralesion single-nucleotide variant (SNV) findings in patient 1 is consistent with the effects of the human apolipoprotein B mRNA-editing catalytic polypeptide-like 3 (APOBEC3) enzyme, which has been suggested to drive the CT>TT and GA>AA conversions

Table. Patient data from study of intrahost viral genome variation from 4 patients with early monkeypox virus infection, Finland, 2022*

Data	Patient no. 1	2	3	4
Age, y	30s	20s	30s	30s
Onset of symptoms	May 19	May 21	Jun 1	Jun 13
Systemic signs/symptoms	Fever, enlarged inguinal lymph nodes	Fever, headache, exhaustion, enlarged inguinal lymph nodes	Fever, myalgia, lymphadenopathy, nausea, myalgia	Fever, headache, anal itch
Lesion sites	Penis	Penis, neck, trunk, face	Trunk, hands, feet, anus	Perianal skin
Evolution of lesions	Synchronous	Asynchronous	Asynchronous	Synchronous
Swab sample lesion sites (C_q value)	Penis (19.77)	Face (26.29), trunk (31.94)	Hand (33.38)	Perianal skin (23.4)
Monkeypox virus sequence†	ON782021‡	ON782022 (face)	NA	ON959143
Sample date	May 24, D5	May 31, D10	Jun 5, D4	Jun 16, D3

*All 4 patients were men who have sex with men who had recent sexual exposure and who had traveled to southern Europe. Cq value, quantitative cycle value of diagnostic orthopoxvirus PCR (Appendix, https://wwwnc.cdc.gov/EID/article/29/3/22-1388-App1.pdf); D, day after first symptom onset; NA, not available.
†GenBank accession numbers.
‡Majority sequence.

in recent MPXV evolution (*6*; A. O'Toole et al., unpub. data, https://virological.org/t/initial-observations-about-putative-apobec3-deaminase-editing-driving-short-term-evolution-of-mpxv-since-2017/830). A similar phenomenon, the fixation of minor intralesion SNVs along the transmission chain, was observed in 5 of the 15

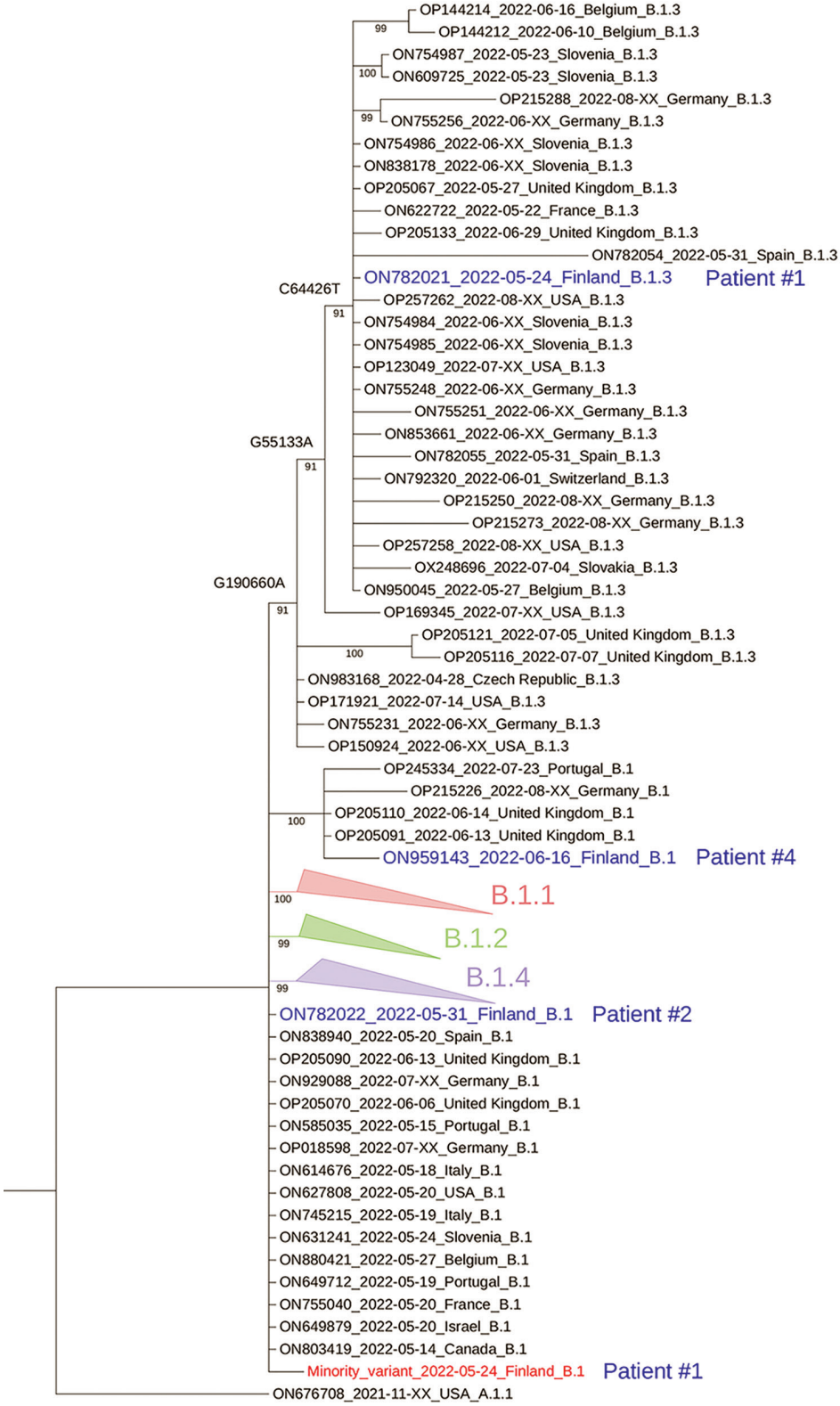

Figure. Phylogenetic tree of monkeypox virus (MPXV) sequences used in study of intrahost viral genome variation in patient with early monkeypox virus infection, Finland, 2022. The tree was inferred by the maximum-likelihood method implemented in IQtree2 software (www.iqtree.org), using 1,000 bootstrap replicates and the Hasegawa-Kishino-Yano plus empirical base frequencies plus invariate sites substitution model (Appendix, https://wwwnc.cdc.gov/EID/article/29/3/22-1388-App1.pdf). The curated dataset of MPXV reference genomes was downloaded from Nextstrain and aligned by using Nextalign (*5*). The reference dataset was downsampled to include only genomes with <5,000 ambiguous genome sites. For the sake of visualization, nodes with bootstrap values <70, as well as clusters with no lineage designation and no representatives from Finland, were deleted; only a subset of nearly identical genomes in the B.1 lineage is shown. Blue indicates the consensus sequences from the 4 patients from Finland; red indicates the hypothetical minority variant sequence (differing from the consensus sequence at sites G55133, C64426, and G190660) from patient 1. Lineage nomenclature (MPXV-1 clade 3, lineage B.1) is as suggested (C. Happi, unpub. data, https://virological.org/t/urgent-need-for-a-non-discriminatory-and-non-stigmatizing-nomenclature-for-monkeypox-virus/8537). The tapering bars indicate clusters of B.1.1 (pink), B.1.2 (green), and B.1.3 (blue), collapsed for clarity. Sequences are identified by GenBank accession number, date, and country of origin.

samples from Portugal sequenced in May 2022 (*6*) and in a publicly available MPXV sequence dataset (A. Nekrutenko et al., unpub. data, https://virological.org/t/mpxv-intrahost-variation-in-the-context-of-apobec-deamination-an-initial-look/856), suggesting that this pattern might be a general pattern of evolution for the 2022 MPXV outbreak. However, in contrast to the previous findings (*6*; A. Nekrutenko et al., unpub. data, https://virological.org/t/mpxv-intrahost-variation-in-the-context-of-apobec-deamination-an-initial-look/856), both the major and minor SNV genotypes from patient 1 could be found fixed in previously reported MPXV sequences.

In conclusion, we demonstrate intrahost MPXV variation within a single lesion from one of the patients with infection introduced to Finland. Most of the sequence reads in that sample contained APOBEC3-related mutations, which may have emerged from the ancestral minor variant present in this sample. However, because the majority and minority nucleotides in that sample are also found fixed in sequences from other countries, we cannot resolve whether this observation relates to contemporary APOBEC3-driven evolution or to co-infection.

Acknowledgments

We gratefully acknowledge the patients for providing consent. We acknowledge the CSC-IT Center for Science, Finland, for providing computational resources.

This study was supported by the Finnish Scientific Advisory Board for Defense, the Academy of Finland (grant no. 336490, 339510), VEO—European Union's Horizon 2020 (grant no. 874735), the Finnish Institute for Health and Welfare, the Jane and Aatos Erkko Foundation, and Helsinki University Hospital Funds (TYH2021343). The study was also supported by the Slovenian Research Agency (research program no. P3-0083).

About the Author

Dr. Vauhkonen is a laboratory coordinator in the Department of Virology at the University of Helsinki. Her research interests include molecular epidemiology of viral zoonoses and next-generation sequencing.

References

1. Perez Duque M, Ribeiro S, Martins JV, Casaca P, Leite PP, Tavares M, et al. Ongoing monkeypox virus outbreak, Portugal, 29 April to 23 May 2022. Euro Surveill. 2022;27:2200424. https://doi.org/10.2807/1560-7917.ES.2022.27.22.2200424
2. Thornhill JP, Barkati S, Walmsley S, Rockstroh J, Antinori A, Harrison LB, et al. Monkeypox virus infection in humans across 16 countries—April–June 2022. N Engl J Med. 2022;387:679–91. https://doi.org/10.1056/NEJMoa2207323
3. Iñigo Martínez J, Gil Montalbán E, Jiménez Bueno S, Martín Martínez F, Nieto Juliá A, Sánchez Díaz J, et al. Monkeypox outbreak predominantly affecting men who have sex with men, Madrid, Spain, 26 April to 16 June 2022. Euro Surveill. 2022;27:2200471. https://doi.org/10.2807/1560-7917.ES.2022.27.27.2200471
4. Karan A, Styczynski AR, Huang CH, Sahoo MK, Srinivasan K, Pinsky BA, et al. Human monkeypox without viral prodrome or sexual exposure, California, USA, 2022. Emerg Infect Dis. 2022;28:2121–3. https://doi.org/10.3201/eid2810.221191
5. Hadfield J, Megill C, Bell SM, Huddleston J, Potter B, Callender C, et al. Nextstrain: real-time tracking of pathogen evolution. Bioinformatics. 2018;34:4121–3. https://doi.org/10.1093/bioinformatics/bty407
6. Isidro J, Borges V, Pinto M, Sobral D, Santos JD, Nunes A, et al. Phylogenomic characterization and signs of microevolution in the 2022 multi-country outbreak of monkeypox virus. Nat Med. 2022;28:1569–72. https://doi.org/10.1038/s41591-022-01907-y

Address for correspondence: Hanna Vauhkonen and Olli Vapalahti, Department of Virology, University of Helsinki, Haartmaninkatu 3, 00014, Helsinki, Uusimaa, Finland; email: hanna.vauhkonen@helsinki.fi and olli.vapalahti@helsinki.fi

New Postmortem Perspective on Emerging SARS-CoV-2 Variants of Concern, Germany

Fabian Heinrich,[1] Tobias Huter,[1] Sophie Mertens, Philine Lange, Jessica Vering, Axel Heinemann, Dominik Sebastian Nörz, Armin Hoffmann, Martin Aepfelbacher, Benjamin Ondruschka,[1] Susanne Krasemann,[1] Marc Lütgehetmann[1]

Author affiliation: University Medical Center Hamburg-Eppendorf, Hamburg, Germany

DOI: https://doi.org/10.3201/eid2903.221297

We performed autopsies on persons in Germany who died from COVID-19 and observed higher nasopharyngeal SARS-CoV-2 viral loads for variants of concern (VOC) compared with non-VOC lineages. Pulmonary inflammation and damage appeared higher in non-VOC than VOC lineages until adjusted for vaccination status, suggesting COVID-19 vaccination may mitigate pulmonary damage.

[1]These authors contributed equally to this article.

Article DOI: https://doi.org/10.3201/eid2903.221388

Intrahost Monkeypox Virus Genome Variation in Patient with Early Infection, Finland, 2022

Appendix

Clinical case description

Patient #1 was a male in his 30s who visited southern Europe and had sex contacts with other men 2-7 days prior to symptoms, which started on 19 May 2022, with 7 unsore papulas appearing in the foreskin. Two days later he noticed a large, egg-size inguinal lymph node. On day 4 he had an onset of fever (ad 40°C), whereafter he contacted health care. He was referred to the infectious disease ward with suspicion of monkeypox and he was examined the next day (D5 after onset). On examination, 7-10 white-rimmed papules were observed under the foreskin (Appendix Figure panel A), as well as an enlarged (diameter 1.5 cm), tender inguinal lymph node. Herpes simplex virus (HSV) and varicella zoster virus (VZV) PCR tests were negative and Orthopox virus (OPXV) PCR test was positive from a lesion swab taken on D5. The serum sample was negative for anti-OPXV antibody in immunofluorescence assay (IFA) using cowpox-infected cells as antigen. The patient was advised to stay home in isolation and to avoid contacts.

Patient #2 was a male in his 20s. A week after possible transmission during a trip to Southern Europe where he had sex with other men, the patient noticed initial symptoms like fever, headache and exhaustion [D0 21 May 2022]. Three days later he detected ulcers on his penis. During the following days, small single vesicles appeared in his neck, back and face. On D10 after the onset, the patient contacted health care because of the penile ulcers. The lesions detected in the clinic were asynchronous, ranging from acne-like papules to umbilicated papules with central ulceration. An additional lesion was detected in the trunk (Appendix Figure panel B) and enlarged inguinal lymph nodes were also observed. DNA samples from the lesions were PCR positive for OPXV.

Patient #3 was a male in his 30s, who fell ill acutely [6 June 2022] with fever, lymphadenopathy, nausea and other gastrointestinal symptoms and myalgia 6 days after unprotected sex with a man during a trip to Southern Europe. Two days later he noticed individual papular skin lesions in his trunk and extremities. D4 after onset, he contacted health care, where asynchronous, papular to crust-covered lesions were noticed, also at the anus. A swab from a lesion in the hand was taken and was shown to be positive for monkeypox virus DNA with a high Ct value (main article Table). In cell culture, however, no infectious virus was observed.

Patient #4 was a male in his 30s, who complained [13 June 2022] with fever, headache and itching in the anus 7-10 days after having sex with other men in Southern Europe. He contacted health care on D2 after the onset of symptoms and three small ulcers were detected in the perianal skin area. In other parts of the skin there were no detectable lesions.

Laboratory procedures

Swab samples were taken from skin lesions into viral transport media. The DNA extraction and Orthopox virus (OPXV) RT-PCR was carried out in HUS Diagnostic Center, Helsinki. DNA was extracted using the MagNA Pure 96 Instrument (Roche Molecular Systems) and OPXV RT-PCR was carried out with the LightCycler Instrument (Roche Molecular Systems) using the conditions described by Putkuri et al (*1*). The quantification cycle (Cq) value was determined as the crossing point (Cp) value given by the instrument software.

OPXV HA gene PCR amplicons for Oxford Nanopore Technologies (ONT) MinION sequencing were obtained by using Superscript III One-Step RT-PCR System (Thermo Fisher Scientific) in a 20 ul reaction volume: 10ul 2x Reaction Mix, 5.6 ul template DNA, 1.8 ul each 0.8uM forward and reverse primers (Forward 5'-GTGATGATGCAACTCTATCATG-3', Reverse 5'-TGTAACTAGATCATCGTATGGAGA-3'), and 0.8 ul Enzyme mix (Putkuri et al. 2009). The PCR program consisted of an initial denaturation at 94°C for 2 min, 40 cycles of following: 94°C 15 sec, 50°C 30 sec, 68°C 20 sec, followed by a final extension at 68°C for 2 min. The PCR product was purified using SpriSelect magnetic beads (Beckman Coulter Life Sciences), quantitated using Qubit (Thermo Fisher Scientific) and approximately 200 fmol of PCR product (~35 ng) was used for ONT sequencing library preparation using the ligation kit

(SQK-LSK110) following the manufacturer's instructions. Approximately 50 fmol of the library was loaded on a R9.4.1 flow cell and sequenced using a MinION Mk1C sequencer and the fast basecall option on MinKNOW software (ONT). Approximately 80.000 reads were sufficient to obtain coverage to clearly differentiate the four monkeypox-specific SNVs within the PCR product, as compared to Cowpox and Vaccinia (C159010A, A159020G, G159037T, T159087C). An one-base mismatch was found to be present in the Forward primer as compared to hMPXV reference.

The whole genome draft sequence was obtained from Patient 1 using ONT MinION sequencer. DNA was semi-randomly amplified using the WTA2 kit (Sigma Aldrich), following the manufacturer's instructions with the reaction volumes reduced to 1:4. Approximately 50 ng of PCR products, with a median size 350 bp and range 200-1200 bp, were used for library preparation by SQ-LSK110 kit and 12 ng of library was used for MinION sequencing. A total of 17876942 mapped reads was obtained after approximately 20 hours of run with a mean coverage 779 of the hMPXV genome.

For complete genome sequencing with Illumina platform, the sequencing libraries were prepared directly from DNA using NEBNext Ultra II FS DNA Library Prep Kit (New England Biolabs) and CleanPlex Plated Unique Dual-Indexed PCR Primers (Paragon Genomics) according to the manufacturer's instructions. The final library amplification was conducted using eight amplification cycles. The libraries were sequenced using Illumina NovaSeq 6000 system with NovaSeq 6000 SP Reagent Kit v1.5 (500 cycles).

Data analysis

The MPXV genome assembly was conducted using the HaVoC-pipeline (*2*). The adaptor sequences and low quality bases (with quality score >30) were trimmed using fastp. The sequence reads were assembled using the BWA-MEM algorithm (*3)* using strain MPXV-UK_P3 (MT903345.1) as a reference, bam files were processed using sambamba and the potential PCR duplicates were removed using SAMTools version 1.15.1 (*4*). The genome coverage metrics are shown in the Appendix Table.

The single nucleotide variants were called using LoFreq version 2 (*5*). Genome Annotation Transfer Utility GATU was used for sequence annotation (*6*) and the annotated

genomes from three cases (MPX-37, MPX-42 and MPX-96) were submitted to GenBank under accession numbers ON782021, ON782022 and ON959143. Raw reads were submitted to NCBI BioProject under accession ID PRJNA914618 (Appendix Table.)

For the phylogenetic analysis a curated dataset of MPXV genomes was retrieved from Nextstrain (*7*) and aligned using NextClade https://clades.nextstrain.org. The sequences with more than 5000 ambiguous nucleotides were excluded from the analysis. Homopolymeric and repeat regions at sites 592-622, 150532-150682, 179077-179277 and 196588-196640 [following the coordinates of reference sequence NC_063383] were excluded from the analysis. The phylogenetic tree was inferred using the maximum likelihood method implemented in IQ-Tree 2 (*8*) with HKY+F+I substitution model (inferred using ModelFinder (*9*)) and 1000 bootstrap replicates and visualized using iTOL v5 (*10*). Nodes with bootstrap support less than 70 were collapsed from the final tree.

Appendix References

1. Putkuri N, Piiparinen H, Vaheri A, Vapalahti O. Detection of human orthopoxvirus infections and differentiation of smallpox virus with real-time PCR. J Med Virol. 2009;81:146–52. PubMed https://doi.org/10.1002/jmv.21385

2. Truong Nguyen PT, Plyusnin I, Sironen T, Vapalahti O, Kant R, Smura T. HAVoC, a bioinformatic pipeline for reference-based consensus assembly and lineage assignment for SARS-CoV-2 sequences. BMC Bioinformatics. 2021;22:373. PubMed https://doi.org/10.1186/s12859-021-04294-2

3. Li H. Aligning sequence reads, clone sequences and assembly contigs with BWA-MEM. arXiv 201;1303.3997v.

4. Li H, Handsaker B, Wysoker A, Fennell T, Ruan J, Homer N, et al.; 1000 Genome Project Data Processing Subgroup. The sequence alignment/map format and SAMtools. Bioinformatics. 2009;25:2078–9. PubMed https://doi.org/10.1093/bioinformatics/btp352

5. Wilm A, Aw PP, Bertrand D, Yeo GH, Ong SH, Wong CH, et al. LoFreq: a sequence-quality aware, ultra-sensitive variant caller for uncovering cell-population heterogeneity from high-throughput sequencing datasets. Nucleic Acids Res. 2012;40:11189–201. PubMed https://doi.org/10.1093/nar/gks918

6. Tcherepanov V, Ehlers A, Upton C. Genome Annotation Transfer Utility (GATU): rapid annotation of viral genomes using a closely related reference genome. BMC Genomics. 2006;7:150. PubMed https://doi.org/10.1186/1471-2164-7-150

7. Aksamentov I, Roemer C, Hodcroft EB, Neher RA. Nextclade: clade assignment, mutation calling and quality control for viral genomes. J Open Source Softw. 2021;6:3773. https://doi.org/10.21105/joss.03773

8. Minh BQ, Schmidt HA, Chernomor O, Schrempf D, Woodhams MD, von Haeseler A, et al. IQ-TREE 2: new models and efficient methods for phylogenetic inference in the genomic era. Mol Biol Evol. 2020;37:1530–4. PubMed https://doi.org/10.1093/molbev/msaa015

9. Kalyaanamoorthy S, Minh BQ, Wong TKF, von Haeseler A, Jermiin LS. ModelFinder: fast model selection for accurate phylogenetic estimates. Nat Methods. 2017;14:587–9. PubMed https://doi.org/10.1038/nmeth.4285

10. Letunic I, Bork P. Interactive Tree Of Life (iTOL) v5: an online tool for phylogenetic tree display and annotation. Nucleic Acids Res. 2021;49(W1):W293–6. PubMed https://doi.org/10.1093/nar/gkab301

Appendix Table. Sequence read coverage metrics for the complete MPXV genomes

Patient no.	Sequencing technique	GenBank accession	BioProject raw read accession	Reads (total)	Reads (quality filtered)	Reads mapped	Reads mapped (duplicates removed)
Patient 1	Illumina Novaseq	ON782021	SAMN32340486	90.19 M	82.30 M	6 209 056	5 248 896
Patient 2	Illumina Novaseq	ON782022	SAMN32340485	176.94 M	160.74 M	4 790 569	2 326 300
Patient 4	Illumina Novaseq	ON959143	SAMN32340484	184.51 M	145.74 M	872 387	438 590

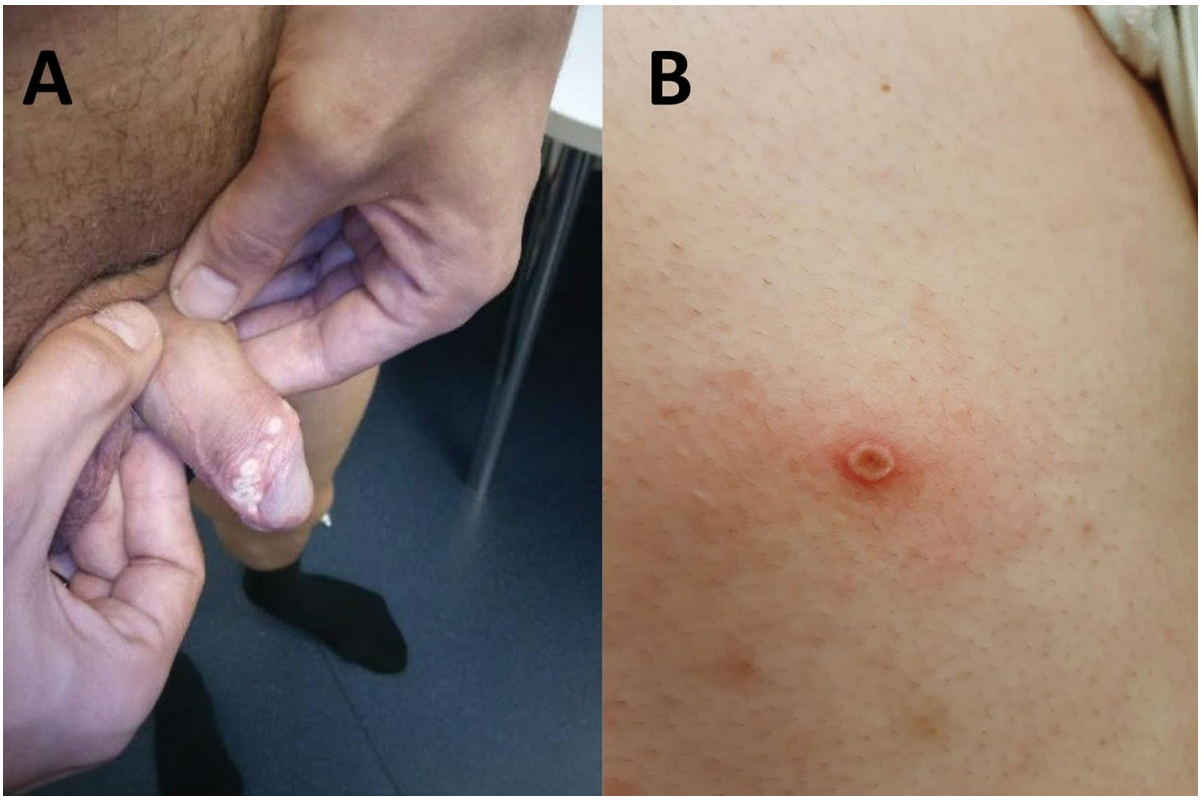

Appendix Figure. Lesions in Finnish MPXV patients. Panel A illustrates the papular lesions found on the foreskin of Patient 1. Panel B illustrates a single lesion found in the trunk of Patient 2.