thousands of intraspecific microbial genomes. Genome Biol. 2014;15:524. https://doi.org/10.1186/s13059-014-0524-x
7. Letunic I, Bork P. Interactive Tree Of Life (iTOL) v4: recent updates and new developments. Nucleic Acids Res. 2019;47(W1):W256–9. https://doi.org/10.1093/nar/gkz239
8. Briese T, Kapoor A, Mishra N, Jain K, Kumar A, Jabado OJ, et al. Virome capture sequencing enables sensitive viral diagnosis and comprehensive virome analysis. MBio. 2015;6:e01491–15. https://doi.org/10.1128/mBio.01491-15
9. van Elk C, van de Bildt M, van Run P, de Jong A, Getu S, Verjans G, et al. Central nervous system disease and genital disease in harbor porpoises (*Phocoena phocoena*) are associated with different herpesviruses. Vet Res (Faisalabad). 2016;47:28. https://doi.org/10.1186/s13567-016-0310-8
10. Brooke CJ, Riley TV. *Erysipelothrix rhusiopathiae*: bacteriology, epidemiology and clinical manifestations of an occupational pathogen. J Med Microbiol. 1999;48:789–99. https://doi.org/10.1099/00222615-48-9-789

Address for correspondence: Els M. Broens, Department of Biomolecular Health Sciences, Faculty of Veterinary Medicine, Utrecht University, Yalelaan 1, 3584 TD, Utrecht, the Netherlands; email: e.m.broens@uu.nl

Powassan Virus Infection Detected by Metagenomic Next-Generation Sequencing, Ohio, USA

Marjorie Farrington,[1] Jamie Elenz, Matthew Ginsberg, Charles Y. Chiu, Steve Miller, Scott F. Pangonis

Author affiliations: Children's Hospital Medical Center of Akron, Akron, Ohio, USA (M. Farrington, M. Ginsberg, S.F Pangonis); Columbiana County Health District, Lisbon, Ohio, USA (J. Elenz); University of California, San Francisco, California, USA (C.Y. Chiu, S. Miller)

DOI: https://doi.org/10.3201/eid2904.221005

We describe a 4-year-old male patient in Ohio, USA, who had encephalitis caused by Powassan virus lineage 2. Virus was detected by using metagenomic next-generation sequencing and confirmed with IgM and plaque reduction neutralization assays. Clinicians should recognize changing epidemiology of tickborne viruses to enhance encephalitis diagnosis and management.

1Current affiliation: St. Louis Children's Hospital, St. Louis, Missouri, USA.

Powassan virus (POWV) is a tickborne flavivirus that causes encephalitis with severe neurologic sequelae (*1*). In the United States, POWV infections occur primarily in the Northeast and Great Lakes regions (*2*). We report a case of human POWV infection in Ohio.

A 4-year-old boy was brought to the emergency department because of fever, vomiting, and convulsive status epilepticus. He had no neurologic history or developmental delays. Mosquito and tick exposure history was substantial, although no engorged ticks were recently removed. The patient had not traveled outside of Ohio.

Results of a computed tomography scan of the head were unremarkable. We initiated intravenous vancomycin, ceftriaxone, and acyclovir. Magnetic resonance imaging showed left temporal pulvinar and thalamic T2-weighted fluid attenuated inversion recovery hyperintensity and restricted diffusion; an electroencephalogram showed lateralized periodic discharges. Cerebrospinal fluid (CSF) was collected by lumbar puncture, revealing a leukocyte count of 44 cells/μL (reference range <10 cells/μL) of which 85% were lymphocytes; glucose and protein levels were normal. The patient's BIOFIRE FILMARRAY Meningitis/Encephalitis PCR panel (bioMérieux, https://www.biomerieux-diagnostics.com) was negative (Table). He was admitted to the pediatric intensive care unit, and seizures were controlled with anticonvulsants. Tests for infectious and noninfectious causes of meningitis and encephalitis were negative (Table). Antimicrobial drugs were discontinued after negative bacterial cultures were observed. Acyclovir was discontinued after PCR of CSF for herpes simplex virus was negative.

On hospitalization day 5, severe neurologic decline developed, and brain magnetic resonance imaging was repeated. New areas of T2 hyperintensity and restricted diffusion and thalamic microhemorrhages in a rhombencephalitis pattern were identified. Lumbar puncture was repeated, revealing considerable lymphocytic pleocytosis and elevated protein (156 mg/dL). Leading diagnoses were autoimmune encephalitis and acute necrotizing encephalopathy of childhood (ANEC). The patient exhibited severe encephalopathy, nystagmus, right hemiparesis, and diffuse hypertonia. He was treated with high dose methylprednisolone, plasmapheresis, and intravenous immunoglobulins.

Genetic testing for familial ANEC type 1 was negative. We sent CSF obtained on hospital day 5 to the University of California San Francisco for metagenomic

Table. Test results for infectious and noninfectious causes of meningitis and encephalitis in study of Powassan virus infection detected by metagenomic next-generation sequencing, Ohio, USA*

Tests	Results
Infectious causes	
CSF meningitis encephalitis PCR panel†	No organisms detected
CSF bacterial culture	Negative
Lyme disease serology	Negative
Serum arbovirus IgG and IgM panel, reference range <1:10‡	<1:10
EBV viral capsid antigen IgM and IgG, antibody index <0.2‡	Negative
EBV nuclear antigen IgG, antibody index <0.2‡	Negative
Bartonella henselae and *B. quintana* antibodies	
IgG, <1:128	Negative
IgM, <1:20	Negative
Noninfectious causes	
Serum antinuclear antibody	Negative
Serum myelin oligodendrocyte glycoprotein	Negative

*CSF, cerebrospinal fluid; EBV, Epstein-Barr virus.
†BIOFIRE FILMARRAY Meningitis/Encephalitis PCR panel (bioMérieux, https://www.biomerieux-diagnostics.com). Panel included *Streptococcus pneumoniae, S. agalactiae, Haemophilus influenzae, Neisseria meningitidis, Listeria monocytogenes, Escherichia coli*, *Cryptococcus neoformans/gattii*, varicella-zoster virus, cytomegalovirus, herpes simplex virus types 1 and 2, *Enterovirus*, human herpesvirus 6, and *Parechovirus*.
‡Acute and convalescent serum samples were sent to Mayo Clinic Laboratories (https://www.mayocliniclabs.com) for arbovirus and EBV analysis. Arbovirus panel included La Crosse encephalitis virus, eastern equine encephalitis virus, western equine encephalitis virus, West Nile encephalitis virus, and St. Louis encephalitis virus.

next-generation sequencing (mNGS), which detected a single 140-nt POWV sequence (Appendix, https://wwwnc.cdc.gov/EID/article/29/4/22-1005-App1.pdf). We performed phylogenetic analysis of the sequence and assigned the patient's virus to lineage 2 (Figure, panel A); the sequence mapped to the nonstructural *NS3* gene (Figure, panel B). We performed BLAST (*3*) sequence alignments in GenBank, which yielded matches to POWV genomes (Figure, panel C). CSF samples obtained before the patient received intravenous Igs were sent for confirmatory testing to the CDC Arbovirus Diagnostic Laboratory, Division of Vector-Borne Diseases, National Center for Emerging and Zoonotic Infectious Diseases (https://www.cdc.gov/ncezid/dvbd/specimensub), which showed IgM against POWV (capture ELISA), negative POWV-specific PCR, and a positive plaque reduction neutralization test at 1:8 dilution (reference range <1:2), confirming the final diagnosis was ANEC caused by POWV. The patient continued having severe neurologic sequalae requiring a tracheostomy, gastrostomy tube, and inpatient rehabilitation. At follow-up 1 year after admission, he had been decannulated, was able to orally ingest liquids and solids, and ambulated independently, but he had substantial language and cognitive deficits.

Diagnostic yield for patients with encephalitis from any cause is 37% (*4*); mNGS enables detection of nearly all pathogens in a single assay and can improvwe diagnostic yield for patients with CNS infections (*5*). We identified 1 nucleotide sequence aligning to POWV, which is below the preestablished reporting threshold for a positive result of ≥3 reads spanning ≥3 regions of the viral genome (*5*). Thus, our finding was potentially a false positive, especially because POWV is not endemic to Ohio. However, POWV has never been a contaminant in clinical mNGS analyses of >4,000 CSF samples at the University of California San Francisco laboratory, and our result was confirmed as a true positive by a plaque reduction neutralization test. Of note, a case of POWV encephalitis identified by mNGS from 10 genomic sequencing reads has been reported (*6*). Furthermore, POWV-specific PCR of our patient's CSF was negative, consistent with a low viral titer near the limit of detection by molecular assays. Patients with POWV encephalitis are often PCR negative because viremia precedes CNS disease development (*7*).

The number of POWV cases reported has increased over the past few decades (*2*), likely because of tick range expansion. *Ixodes scapularis* is the only tick species in northeastern Ohio that can transmit POWV (*8*). Tick range expansion might be caused by increasing temperatures from climate change (*9*), migration of animal hosts, and changes in land use or host populations (*10*). Ticks carrying POWV lineage 2 were not identified on the family's property. However, healthcare and public health workers should be aware of changing epidemiology and potential emerging tickborne infections in nonendemic regions.

In conclusion, we identified a POWV infection in Ohio by using mNGS. Tests for autoimmune etiologies, familial ANEC (type 1), and other viral agents were negative, excluding alternative diagnoses. Our case highlights the ability of mNGS to identify rare or unexpected pathogens that cause encephalitis. Providers should recognize

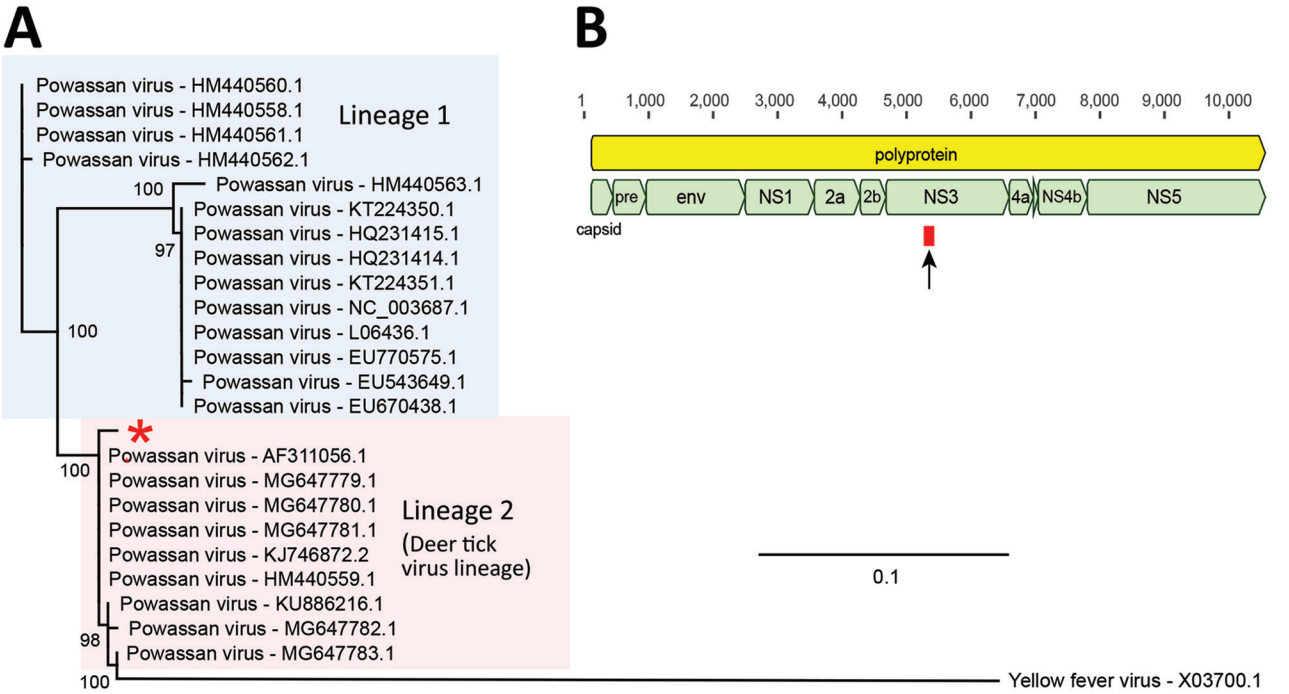

C

Description	Query coverage	E-value	% Identity	Accession no.
Powassan virus isolate RTS92 polyprotein gene, complete cds	100%	1E-61	98.6%	MG647781.1
Powassan virus isolate RTS82 polyprotein gene, complete cds	100%	1E-61	98.6%	MG647780.1
Powassan virus isolate RTS81 polyprotein gene, complete cds	100%	1E-61	98.6%	MG647779.1
Powassan virus isolate LI-1 polyprotein gene, complete cds	100%	1E-61	98.6%	KJ746872.2
Powassan virus isolate 17103-1037, complete genome	100%	1E-61	98.6%	OL704372.1
Powassan virus isolate 18103-167-010, complete genome	100%	1E-61	98.6%	OL704348.1
Powassan virus isolate 19103-41-001, complete genome	100%	1E-61	98.6%	OL704334.1
Powassan virus isolate 19103-37-004, complete genome	100%	1E-61	98.6%	OL704333.1
Powassan virus isolate 19103-37-002, complete genome	100%	1E-61	98.6%	OL704332.1
Powassan virus isolate 19103-14-001, complete genome	100%	1E-61	98.6%	OL704329.1

Figure. Identification and phylogenetic analysis of Powassan virus found in cerebrospinal fluid of 4-year-old boy detected by metagenomic next-generation sequencing, Ohio, USA. A) Phylogenetic analysis of the 140-bp region in the Powassan virus genome corresponding to the single sequence read detected by metagenomic next-generation sequencing. Single read from the patient in this study was aligned with sequences from 23 representative Powassan virus genomes from lineage 1 (blue shaded box) and lineage 2 (deer tick virus lineage, pink shaded box) and 1 yellow fever virus sequence as an outgroup by using MAFFT v7.388 (Appendix reference *11*, https://wwwnc.cdc.gov/EID/article/29/4/22-1005-App1.pdf). Phylogenetic tree was constructed by using the maximum-likelihood method and PhyML 3.0 software (Appendix reference *12*); support values for the main branches are shown. Powassan virus from our patient (red asterisk) belongs to lineage 2. GenBank accession numbers are shown for each sequence. Scale bar indicates nucleotide substitutions per site. B) Powassan virus genome showing major capsid and nonstructural genes. Single sequence read from the patient mapped to the *NS3* gene (arrow and red box). C) List of top 10 GenBank reference sequences matching the patient's 140-nt read after using MegaBLAST (https://blast.ncbi.nlm.nih.gov) alignment as default setting, each showing 98.6% sequence identity. If Powassan virus sequences were excluded from the reference database, no other matches in GenBank were found. Cds, coding sequence; env, envelope protein; NS, nonstructural; pre, M protein precursor peptide.

changing epidemiology of tickborne viruses, such as POWV, to enhance encephalitis diagnosis and management. When cases are identified, local public health departments should complete comprehensive entomological and epidemiologic studies to determine virus prevalence.

About the Author

Dr. Farrington recently completed her pediatrics residency at the Children's Hospital Medical Center of Akron in 2022. She is currently working as a pediatric hospitalist at the St. Louis Children's Hospital–Washington University.

References

1. Kemenesi G, Bányai K. Tick-borne flaviviruses, with a focus on Powassan virus. Clin Microbiol Rev. 2018;32:e00106-17. https://doi.org/10.1128/CMR.00106-17
2. Centers for Disease Control and Prevention. Powassan virus [cited 2022 May 3]. https://www.cdc.gov/powassan/statistics.html
3. Altschul SF, Gish W, Miller W, Myers EW, Lipman DJ. Basic local alignment search tool. J Mol Biol. 1990;215:403–10. https://doi.org/10.1016/S0022-2836(05)80360-2
4. Glaser CA, Honarmand S, Anderson LJ, Schnurr DP, Forghani B, Cossen CK, et al. Beyond viruses: clinical profiles and etiologies associated with encephalitis. Clin Infect Dis. 2006;43:1565–77. https://doi.org/10.1086/509330
5. Miller S, Naccache SN, Samayoa E, Messacar K, Arevalo S, Federman S, et al. Laboratory validation of a clinical metagenomic sequencing assay for pathogen detection in cerebrospinal fluid. Genome Res. 2019;29:831–42. https://doi.org/10.1101/gr.238170.118
6. Piantadosi A, Kanjilal S, Ganesh V, Khanna A, Hyle EP, Rosand J, et al. Rapid detection of Powassan virus in a patient with encephalitis by metagenomic sequencing. Clin Infect Dis. 2018;66:789–92. https://doi.org/10.1093/cid/cix792
7. Hermance ME, Thangamani S. Powassan virus: an emerging arbovirus of public health concern in North America. Vector Borne Zoonotic Dis. 2017;17:453–62. https://doi.org/10.1089/vbz.2017.2110
8. Eisen RJ, Eisen L, Beard CB. County-scale distribution of *Ixodes scapularis* and *Ixodes pacificus* (Acari: Ixodidae) in the continental United States. J Med Entomol. 2016;53:349–86. https://doi.org/10.1093/jme/tjv237
9. Bouchard C, Dibernardo A, Koffi J, Wood H, Leighton PA, Lindsay LR. N increased risk of tick-borne diseases with climate and environmental changes. Can Commun Dis Rep. 2019;45:83–9 https://doi.org/10.14745/ccdr.v45i04a02
10. Diuk-Wasser MA, VanAcker MC, Fernandez MP. Impact of land use changes and habitat fragmentation on the eco-epidemiology of tick-borne diseases. J Med Entomol. 2021;58:1546–64. https://doi.org/10.1093/jme/tjaa209

Address for correspondence: Scott F Pangonis, Children's Medical Center of Akron, 1 Perkins Sq, Akron, OH 44321, USA; email: spangonis@akronchildrens.org

Rickettsia conorii Subspecies *israelensis* in Captive Baboons

Giovanni Sgroi, Roberta Iatta, Grazia Carelli, Annamaria Uva, Maria Alfonsa Cavalera, Piero Laricchiuta, Domenico Otranto

Author affiliations: Experimental Zooprophylactic Institute of Southern Italy, Portici, Italy (G. Sgroi); University of Bari Aldo Moro, Bari, Italy (G. Sgroi, R. Iatta, G. Carelli, A. Uva, M.A. Cavalera, D. Otranto); Zoosafari Park Fasano, Brindisi, Italy (P. Laricchiuta); Bu-Ali Sina University, Hamedan, Iran (D. Otranto)

DOI: https://doi.org/10.3201/eid2904.221176

Hamadryas baboons (*Papio hamadryas*) may transmit zoonotic vector-borne pathogens to visitors and workers frequenting zoological parks. We molecularly screened 33 baboons for vector-borne pathogens. Three (9.1%) of 33 animals tested positive for *Rickettsia conorii* subspecies *israelensis*. Clinicians should be aware of potential health risks from spatial overlapping between baboons and humans.

Papio hamadryas baboons (order Primates, family Cercopithecidae) are frequently hosted in zoological gardens worldwide. The natural susceptibility of baboons to many zoonotic agents (*1*) may present a potential risk for transmission of emerging infectious diseases to humans. Nevertheless, few data are available on vector-borne pathogens of human concern that are hosted by baboons (e.g., *Rickettsia africae*, *Babesia microti*–like parasites, and *Anaplasma phagocytophilum*) (*1*). Data are likewise scarce on the role of *P. hamadryas* baboons in circulating arthropod vectors in zoological gardens and the resulting risk for transmitting vector-borne pathogens to persons frequenting such areas. We aimed to determine the occurrence of zoonotic vector-borne pathogens in a zoopark in the Apulia region of southern Italy and assess baboons' potential roles as reservoirs of emerging pathogens. Our study was approved by the University of Bari Aldo Moro ethics committee (Prot. Uniba 176/19).

During February–December 2020, we anesthetized baboons in the zoopark and housed them in cages for blood sampling. For each baboon, we recorded age, sex, weight, and body condition score (1–5); we obtained peripheral blood samples by cephalic vein puncture. To determine complete blood count and for molecular analysis, we collected 2 mL blood

Article DOI: https://doi.org/10.3201/eid2904.221005
EID cannot ensure accessibility for supplementary materials supplied by authors. Readers who have difficulty accessing supplementary content should contact the authors for assistance.

Powassan Virus Infection Detected by Metagenomic Next-Generation Sequencing, Ohio, USA

Appendix

A single 140-nt sequence from Powassan virus was detected by metagenomic next-generation sequencing in the cerebrospinal fluid of a 4-year-old boy.

>NDX550313_RUO:156:HKNFTBGXK:1:22109:2530:9011#ATCTCAGG+ATAGCCTT/1

CAGCATCACAGTCCTGGACATGCATCCTGGAGCGGGAAAGACACACAGAGTCCTTC
CCGAGCTGATTCGTGAATGCATTGACAAAAGATTGAGGACTGTTGTGTTGGCCCCAA
CGCGGGTTGTTCTGAAAGAGATGGAAA

Appendix References

11. Katoh K, Standley DM. MAFFT: iterative refinement and additional methods. Methods Mol Biol. 2014;1079:131–46. PubMed https://doi.org/10.1007/978-1-62703-646-7_8

12. Guindon S, Dufayard J-F, Lefort V, Anisimova M, Hordijk W, Gascuel O. New algorithms and methods to estimate maximum-likelihood phylogenies: assessing the performance of PhyML 3.0. Syst Biol. 2010;59:307–21. PubMed https://doi.org/10.1093/sysbio/syq010