Fatal Case of Heartland Virus Disease Acquired in the Mid-Atlantic Region, United States

Sichen Liu,[1] Suraj Kannan,[1] Monica Meeks, Sandra Sanchez, Kyle W. Girone, James C. Broyhill, Roosecelis Brasil Martines, Joshua Bernick, Lori Flammia, Julia Murphy, Susan L. Hills, Kristen L. Burkhalter, Janeen J. Laven, David Gaines, Christopher J. Hoffmann

Heartland virus (HRTV) disease is an emerging tickborne illness in the midwestern and southern United States. We describe a reported fatal case of HRTV infection in the Maryland and Virginia region, states not widely recognized to have human HRTV disease cases. The range of HRTV could be expanding in the United States.

Heartland virus (HRTV) is a bandavirus spread by *Amblyomma americanum* (lone star) ticks in the midwestern and southern United States (*1*). Many cases of HRTV infection have been characterized by severe illness or death, mostly among men >50 years of age with multiple underlying conditions (*1*–*7*). HRTV infection in humans typically manifests as a nonspecific febrile illness characterized by malaise, myalgias, arthralgias, and gastrointestinal distress, along with thrombocytopenia, leukopenia, hyponatremia, and elevated liver transaminases (*3*). Most reported hospitalized patients recover, but deaths have occurred and have been associated with secondary hemophagocytic lymphohistiocytosis (HLH) (*4*,*5*).

Since HRTV was discovered in 2009 in Missouri, USA, human HRTV disease cases have also been reported in Kansas, Oklahoma, Arkansas, Tennessee, Kentucky, Indiana, Illinois, Iowa, Georgia, Pennsylvania, New York, and North Carolina according to the Centers for Disease Control and Prevention (CDC; https://www.cdc.gov/heartland-virus/statistics/index.html). Studies have documented HRTV RNA in *A. americanum* ticks and HRTV-neutralizing antibodies in vertebrate animals in these states (*8*–*13*). However, the distribution of *A. americanum* ticks is wider and growing, possibly because of climate change, which could lead to HRTV range expansion (*3*,*11*). Of note, vertebrate animals with neutralizing antibodies to HRTV have been documented in states without confirmed human cases, including Texas, Florida, South Carolina, and Louisiana in the south and Vermont, New Hampshire, and Maine in the northeast (*12*,*13*). To date, no seropositive animals have been reported from Maryland or Virginia in the mid-Atlantic region. We describe a fatal human case of HRTV infection with secondary HLH in which initial infection likely occurred in either Maryland or Virginia.

The Study

The patient was a man in his late 60s who had a medical history of splenectomy from remote trauma, coronary artery disease, and hypertension. He was seen at an emergency department in November 2021 for 5 days of fever, nonbloody diarrhea, dyspnea, myalgias, and malaise. At initial examination, he appeared fatigued but was alert and oriented. Laboratory results were notable for hyponatremia, mildly elevated liver enzymes, leukopenia, and thrombocytopenia (Table). The patient had homes in rural areas of Maryland and Virginia and had not traveled outside of this area in the previous 3 months. He spent time outdoors on his properties but did not recall attached ticks or tick bites. Despite the lack of known tick bites, the symptom constellation and potential exposure led clinicians to highly suspect tickborne illness; they prescribed doxycycline and discharged the patient home.

Author affiliations: National Institute of Allergy and Infectious Diseases, Bethesda, Maryland, USA (S. Liu); Johns Hopkins University School of Medicine, Baltimore, Maryland, USA (S. Kannan, M. Meeks, S. Sanchez, C.J. Hoffman); Virginia Department of Health, Richmond, Virginia, USA (K.W. Girone, J.C. Broyhill, J. Bernick, L. Flammia, J. Murphy, D. Gaines); Centers for Disease Control and Prevention, Atlanta, Georgia, USA (R.B. Martines); Centers for Disease Control and Prevention, Fort Collins, Colorado, USA (S.L. Hills, K.L. Burkhalter, J.J. Laven)

DOI: https://doi.org/10.3201/eid2905.221488

[1]These first authors contributed equally to this article.

Two days later, on day 7 after symptom onset, the patient returned to the emergency department with confusion, an unsteady gait, and new fecal and urinary incontinence; he was admitted for inpatient management. He had progressive encephalopathy with hyponatremia and rising transaminases (Table). Results of neurologic workup and imaging were unremarkable (Table). Computed tomography imaging of the abdomen and pelvis showed new pelvic and inguinal lymphadenopathy. The patient was treated with hypertonic saline, intravenous doxycycline, and piperacillin/tazobactam.

Because of clinical deterioration, he was transferred to a tertiary care center. At arrival at the tertiary center, he was fatigued and disoriented. Physical examination demonstrated new hepatomegaly and lower extremity livedo reticularis. Results of broad testing for infectious etiologies was negative (Appendix Table, https://wwwnc.cdc.gov/EID/article/29/5/22-1488-App1.pdf). Laboratory results demonstrated increased creatine kinase (9,567 U/L), lactate (2.5 mg/dL), lactate dehydrogenase (1,709 U/L), and ferritin (47,445 ng/mL). Interleukin 2 receptor, a marker for HLH, was also elevated (9,390 pg/mL) (Table). Immunosuppressive agents for management of likely secondary HLH were deferred while clinicians conducted a diagnostic work-up of the underlying disease process. An arboviral disease was the leading diagnostic consideration, but limited availability of commercial diagnostic testing for tickborne diseases delayed diagnosis.

The patient's clinical course continued to deteriorate. He had acute respiratory failure, renal failure, and a cardiac arrest. He was transitioned to comfort care and died on day 13 after symptom onset.

Because of concern for arboviral illness, the Virginia Department of Health (VDH) initiated an investigation and sent a serum specimen to CDC for testing (Appendix). Quantitative reverse transcription PCR was notably positive for HRTV RNA (Appendix Table). Autopsy findings identified

Table. Laboratory findings in a fatal case of heartland virus disease acquired in the mid-Atlantic region, United States*

Test	Reference range	Days after symptom onset				
		5	7	9	11	13
Temperature, °C	35.5–38.3	36.8	38.5	38.5	39.1	36.9
Blood cell counts						
Leukocyte count, × 10^3 cells/μL	4.50–11.00	2.4	3.7	3.5	2.48	3.25
Absolute neutrophil count, cells/μL	1.50–7.80	ND	ND	ND	0.99	0.88
Absolute lymphocyte count, cells/μL	1.10–4.80	ND	ND	ND	1.22	1.76
Hemoglobin, g/dL	13.9–16.3	14.5	14.9	14.6	14.4	11.7
Platelets, × 10^3/μL	150–350	178	106	82	59	61
Blood chemistry test results						
Sodium, mmol/L	135–148	126	115	120	129	136
Potassium, mmol/L	3.5–5.1	3.7	3.3	4.2	4.4	4.4
Carbon dioxide, mmol/L	21–31	22	22	20	17	18
Anion gap, mmol/L	7–16	13	15	12	12	11
Blood urea nitrogen, mg/dL	7–22	12	12	16	26	68
Creatinine, mg/dL	0.6–1.3	1.0	1.3	1.2	1.4	4.4
Aspartate aminotransferase, units/L	≤37	45	359	434	590	617
Alanine aminotransferase, units/L	≤40	46	238	262	209	156
Alkaline phosphatase, units/L	30–120	69	64	53	67	89
Cerebrospinal fluid test results						
Leukocyte count, cells/mm^3	0–5	ND	2	ND	ND	ND
Glucose, mg/dL	40–70	ND	80	ND	ND	ND
Protein, mg/dL	12–60	ND	58	ND	ND	ND
Cardiac test results						
Troponin I, ng/mL	<0.04	ND	ND	ND	0.21	0.38
Troponin T, high sensitivity, ng/L	0–19	14	22	30	ND	ND
Pro-BNP, pg/mL	5–125	ND	ND	ND	4,258	ND
Lipid panel test results						
Cholesterol, total, mg/dL	≤200	ND	ND	ND	69	ND
Triglycerides, mg/dL	≤150	ND	ND	ND	147	ND
Other test results						
D-dimer, mg/L	0.00–0.49	ND	ND	2.72	3.71	ND
Creatine kinase, U/L	24–195	ND	ND	ND	8,727	11,083
Lactic acid, mmol/L	0.5–2.0	1.6	1.8	ND	2.5	2.4
Lactate dehydrogenase, U/L	118–273	ND	ND	1,412	1,709	ND
Ferritin, ng/mL	30–400	ND	ND	ND	47,445	174,957
Fibrinogen, mg/dL	170–422	ND	ND	199	224	170
C-reactive protein, mg/dL	<0.5	ND	1.2	0.6	0.5	ND
Interleukin 2 receptor, pg/mL	532–1,891	ND	ND	ND	9,390	ND

*BNP, B-type natriuretic peptide; ND, not done.

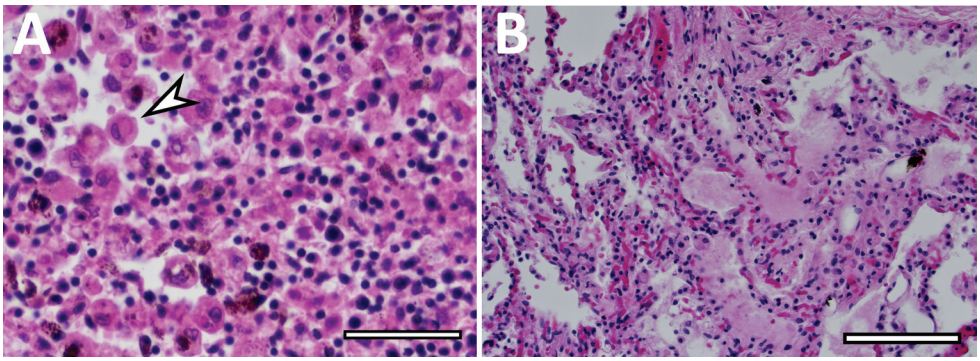

Figure 1. Postmortem autopsy findings in a fatal case of heartland virus disease acquired in the mid-Atlantic region, United States. A) Hematoxylin and eosin stain of patient accessory spleen; arrow indicates congestion with hemophagocytic histiocytes. Scale bar indicates 50 μm. B) Hematoxylin and eosin stain showing pulmonary hyperinflammation, including pleural thickening and adhesions, and pulmonary fibrosis, edema, and calcifications. Scale bar indicates 125 μm.

markedly congested accessory spleens with abundant histiocytes, phagocytosing erythrocytes, and pulmonary hyperinflammation (Figure 1). Immunohistochemistry testing of heart, spleen, kidney, and liver samples were positive for HRTV at CDC (Figure 2). Immunohistochemistry of the spleen was negative for Epstein-Barr virus (EBV) at the clinical institution. The autopsy report concluded that the cause of death was respiratory failure secondary to hyperinflammation due to HLH, likely triggered by HRTV infection.

VDH performed tick drags at the patient's 2 properties in eastern Maryland and central Virginia during early- to mid-June 2022. VDH collected a total of 193 ticks across the properties, which were sent to CDC for testing (Appendix). The tick pools collected from both properties tested negative for HRTV RNA.

Conclusions

HRTV disease has been reported in >50 patients in states across the midwestern and southern United States (*1*–*7*). A bite from an *A. americanum* tick is the only known means of environmental HRTV transmission (*1*). Corresponding to *A. americanum* tick seasonal activity, all reported cases have occurred during April–September, and symptoms developed during June in most case-patients (*1*,*3*). Because the incubation period for HRTV is estimated to be 2 weeks, this patient was likely infected in late October. Adult ticks are minimally active at that time; however, larval ticks can become infected with HRTV and can still be observed during October (*1*,*14*). We suspect this patient was bitten by larval ticks unknowingly because of their small size, and that the bite marks healed before his clinical signs and symptoms appeared.

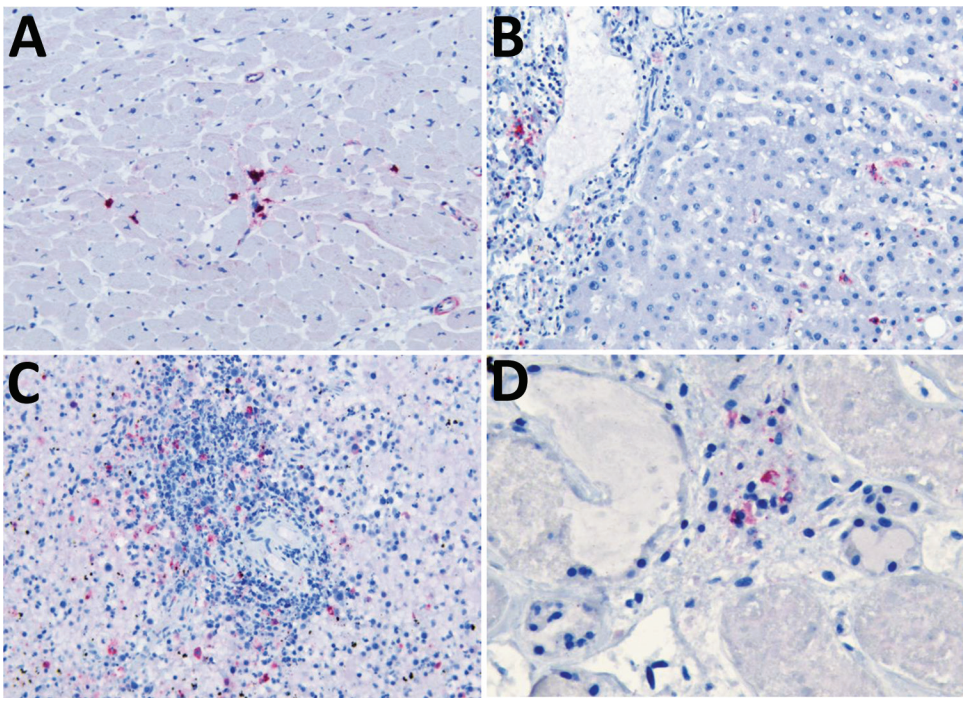

Figure 2. Viral immunostaining of samples from a fatal case of heartland virus disease acquired in the mid-Atlantic region, United States. Heartland virus antigen was detected in multiple organs. A) Mononuclear interstitial inflammatory cell of myocardium. Original magnification ×20. B) Periportal macrophages and Kupffer cells in liver. Original magnification ×20. C) Large hematopoietic cells of spleen. Original magnification ×20. D) Inflammatory interstitial cells of kidney. Original magnification ×40.

Maryland and Virginia fall within the *A. americanum* tick distribution area, but we found no previous reports of HRTV illness from those states during a literature search, and CDC had no reported cases from those states. Among 193 ticks collected during tick drags of both properties, no HRTV-infected vectors were found, but this result does not exclude HRTV in either state. Previous studies report low overall minimum infection rates among *A. americanum* ticks from other states, ranging from 0.4 to 11/1,000 ticks (1 infected tick/90–2,174 collected) (*1*,*8*,*10*,*11*). We suspect the Virginia property was the likely location of infection, based on the number of ticks VDH collected while sampling an area that the patient frequented 10–14 days before symptom onset and because fewer ticks were collected from the Maryland property (Appendix).

The patient's clinical and laboratory findings were consistent with HLH secondary to HRTV infection. HLH has been documented in several cases of infection with the related *Bandavirus*, severe fever with thrombocytopenia syndrome virus, and in at least 1 case of HRTV infection (*1*,*4*). Reports showed corticosteroids and ribavirin did not effectively treat severe fever with thrombocytopenia syndrome–triggered HLH, but preliminary clinical data shows potential benefit from favipiravir (*1*,*15*). Currently, clinical management for HRTV infection is supportive care (*3*).

We hypothesize that HRTV infection is underrecognized and mainly diagnosed when severe disease leads to additional testing at referral centers. Although lack of responsiveness to appropriate antimicrobial agents for bacterial tickborne illness might suggest severe disease (*2*), self-limited disease likely is undiagnosed or diagnosed as another tickborne disease. Because tick ranges are increasing overall, incidence of previously regional tickborne infections, such as HRTV, likely will continue to increase. Expanding testing capabilities for arbovirus and tickborne infections, including multiplex testing, would enable real-time assessment and management of patients with potential arboviral and other tickborne infections.

Acknowledgments

We thank the patient's family for their kindness with this study. We also thank Luciana Silva-Flannery for performing immunohistochemistry for HRTV, and the manuscript's anonymous reviewers.

About the Authors

Dr. Liu is an infectious disease fellow at the National Institute of Allergy and Infectious Diseases, National Institutes of Health, Bethesda, Maryland, USA. His research interest is in local, targeted antimicrobial therapy. Mr. Kannan is an MD candidate at the Johns Hopkins School of Medicine and a PhD candidate in the Johns Hopkins Department of Biomedical Engineering, Baltimore, Maryland, USA. His research interests include internal medicine and the interface of evidence-based medicine and patient-centered decision-making.

References

1. Brault AC, Savage HM, Duggal NK, Eisen RJ, Staples JE. Heartland virus epidemiology, vector association, and disease potential. Viruses. 2018;10:1–17. https://doi.org/10.3390/v10090498
2. McMullan LK, Folk SM, Kelly AJ, MacNeil A, Goldsmith CS, Metcalfe MG, et al. A new phlebovirus associated with severe febrile illness in Missouri. N Engl J Med. 2012;367:834–41. https://doi.org/10.1056/NEJMoa1203378
3. Staples JE, Pastula DM, Panella AJ, Rabe IB, Kosoy OI, Walker WL, et al. Investigation of heartland virus disease throughout the United States, 2013–2017. Open Forum Infect Dis. 2020;7:a125. https://doi.org/10.1093/ofid/ofaa125
4. Carlson AL, Pastula DM, Lambert AJ, Staples JE, Muehlenbachs A, Turabelidze G, et al. Heartland virus and hemophagocytic lymphohistiocytosis in immunocompromised patient, Missouri, USA. Emerg Infect Dis. 2018;24:893–7. https://doi.org/10.3201/eid2405.171802
5. Fill MA, Compton ML, McDonald EC, Moncayo AC, Dunn JR, Schaffner W, et al. Novel clinical and pathologic findings in a heartland virus-associated death. Clin Infect Dis. 2017;64:510–2.
6. Muehlenbachs A, Fata CR, Lambert AJ, Paddock CD, Velez JO, Blau DM, et al. Heartland virus-associated death in Tennessee. Clin Infect Dis. 2014;59:845–50. https://doi.org/10.1093/cid/ciu434
7. Decker MD, Morton CT, Moncayo AC. One confirmed and 2 suspected cases of heartland virus disease. Clin Infect Dis. 2020;71:3237–40. https://doi.org/10.1093/cid/ciaa647
8. Dupuis AP II, Prusinski MA, O'Connor C, Maffei JG, Ngo KA, Koetzner CA, et al. Heartland virus transmission, Suffolk County, New York, USA. Emerg Infect Dis. 2021;27:3128–32. https://doi.org/10.3201/eid2712.211426
9. Newman BC, Sutton WB, Moncayo AC, Hughes HR, Taheri A, Moore TC, et al. Heartland virus in lone star ticks, Alabama, USA. Emerg Infect Dis. 2020;26:1954–6. https://doi.org/10.3201/eid2608.200494
10. Romer Y, Adcock K, Wei Z, Mead DG, Kirstein O, Bellman S, et al. Isolation of heartland virus from lone star ticks, Georgia, USA, 2019. Emerg Infect Dis. 2022;28:786–92. https://doi.org/10.3201/eid2804.211540
11. Tuten HC, Burkhalter KL, Noel KR, Hernandez EJ, Yates S, Wojnowski K, et al. Heartland virus in humans and ticks, Illinois, USA, 2018–2019. Emerg Infect Dis. 2020;26:1548–52. https://doi.org/10.3201/eid2607.200110
12. Clarke LL, Ruder MG, Mead DG, Howerth EW. Heartland virus exposure in white-tailed deer in the Southeastern United States, 2001–2015. Am J Trop Med Hyg. 2018;99:1346–9. https://doi.org/10.4269/ajtmh.18-0555
13. Riemersma KK, Komar N. Heartland virus neutralizing antibodies in vertebrate wildlife, United States, 2009–2014. Emerg Infect Dis. 2015;21:1830–3. https://doi.org/10.3201/eid2110.150380

14. Jackson LK, Gaydon DM, Goddard J. Seasonal activity and relative abundance of *Amblyomma americanum* in Mississippi. J Med Entomol. 1996;33:128–31. https://doi.org/10.1093/jmedent/33.1.128
15. Suemori K, Saijo M, Yamanaka A, Himeji D, Kawamura M, Haku T, et al. A multicenter non-randomized, uncontrolled single arm trial for evaluation of the efficacy and the safety of the treatment with favipiravir for patients with severe fever with thrombocytopenia syndrome. PLoS Negl Trop Dis. 2021;15:e0009103. https://doi.org/10.1371/journal.pntd.0009103

Address for correspondence: Christopher J. Hoffmann, Johns Hopkins University, 1550 Orleans St, CRBII 1M11, Baltimore, MD 21205, USA; email: choffmann@jhmi.edu

December 2022

Zoonotic Infections

- SynopsesClinical and Epidemiologic Characteristics and Therapeutic Management of Patients with *Vibrio* Infections, Bay of Biscay, France, 2001–2019
- Transmission of SARS-CoV-2 through Floors and Walls of Quarantine Hotel, Taiwan, 2021
- Iceland as Stepping Stone for Spread of Highly Pathogenic Avian Influenza Virus between Europe and North America
- Systematic Review and Meta-analysis of Lyme Disease Data and Seropositivity for *Borrelia burgdorferi*, China, 2005–2020
- *Acinetobacter baumannii* among Patients Receiving Glucocorticoid Aerosol Therapy during Invasive Mechanical Ventilation, China
- Observational Cohort Study of Evolving Epidemiologic, Clinical, and Virologic Features of Monkeypox in Southern France
- Continued Circulation of Tick-Borne Encephalitis Virus Variants and Detection of Novel Transmission Foci, the Netherlands
- Household Transmission of SARS-CoV-2 from Humans to Pets, Washington and Idaho, USA
- National Monkeypox Surveillance, Central African Republic, 2001–2021
- Development of Differentiating Infected from Vaccinated Animals (DIVA) Real-Time PCR for African Horse Sickness Virus Serotype 1
- Severe and Rare Case of Human *Dirofilaria repens* Infection with Pleural and Subcutaneous Manifestations, Slovenia



- Daily Rapid Antigen Exit Testing to Tailor University COVID-19 Isolation Policy
- Orthopoxvirus Seroprevalence and Infection Susceptibility in France, Bolivia, Laos, and Mali
- Association between Conflict and Cholera in Nigeria and the Democratic Republic of the Congo
- Emergence and Evolutionary Response of *Vibrio cholerae* to a Novel Bacteriophage, the Democratic Republic of the Congo
- Hedgehogs as Amplifying Hosts of Severe Fever with Thrombocytopenia Syndrome Virus, China
- Myocarditis Attributable to Monkeypox Virus Infection in 2 Patients, United States, 2022
- Monkeypox Virus Detection in Different Clinical Specimen Types
- Monkeypox after Occupational Needlestick Injury from Pustule
- Possible Occupational Infection of Healthcare Workers with Monkeypox Virus, Brazil
- Natural Mediterranean Spotted Fever Foci, Qingdao, China
- Highly Diverse Arenaviruses in Neotropical Bats, Brazil
- Highly Pathogenic Avian Influenza A(H5N1) Clade 2.3.4.4b Virus in Poultry, Benin, 2021
- Hepatitis E Virus Infections in Free-Ranging and Captive Cetaceans, Spain, 2011–2022
- Mass Mortality Caused by Highly Pathogenic Influenza A(H5N1) Virus in Sandwich Terns, the Netherlands, 2022
- Sylvatic Transmission of Chikungunya Virus among Nonhuman Primates in Myanmar
- Pandemic or Panzootic—A Reflection on Terminology for SARS-CoV-2 Infection
- Hemotropic Mycoplasma spp. in Aquatic Mammals, Amazon Basin, Brazil
- Human Thelaziosis Caused by *Thelazia callipaeda* Worm, Hungary
- Severe Human Case of Zoonotic Infection with Swine-Origin Influenza A Virus, Denmark,
- Autochthonous *Angiostrongylus cantonensis* Lungworms in Urban Rats, Valencia, Spain, 2021
- Laboratory Features of Trichinellosis and Eosinophilia Threshold for Testing, Nunavik, Quebec, Canada, 2009–2019
- Isolation of Bat Sarbecoviruses, Japan

EMERGING INFECTIOUS DISEASES

To revisit the December 2022 issue, go to:
https://wwwnc.cdc.gov/eid/articles/issue/28/12/table-of-contents

Article DOI: https://doi.org/10.3201/eid2905.221488

Fatal Case of Heartland Virus Disease Acquired in the Mid-Atlantic Region, United States

Appendix

CDC Serology Testing

Given the severity of the illness, fatal outcome, and the fact that symptoms were consistent with tickborne arboviral illness, the Virginia Department of Health (VDH) initiated an investigation and sent a serum specimen obtained during laboratory testing before death to the Centers for Disease Control and Prevention (CDC) Arboviral Diseases Branch in Fort Collins, Colorado for testing. RT-qPCR was negative for Bourbon viral RNA but positive for heartland virus (HRTV) RNA and HRTV was isolated. IgM serology was negative for Powassan virus.

Tick HRTV Testing

To determine the likely location where the patient acquired HRTV and inform public health measures, the VDH performed tick drags using standard methods (*1*) at the patient's two properties in eastern Maryland and central Virginia in early- to mid-June 2022. At the Maryland property, the landscape was well maintained. Surveyors were not able to collect any ticks via their tick drags on the manicured, high human traffic portion of the property. Ticks that were collected were from a minimally accessible overgrown area of the property. In total, the survey covered 860 m^2 and yielded 31 nymph and 7 adult stage *A. americanum* ticks. The central Virginia farm was noted to be of forest and field environment and more readily yielded ticks. Tick drags were performed along the property, including a trail within the farm that the patient frequented 10–14 days before symptom onset. In total, the survey covered 1,620 m^2 and yielded 134 nymph and 15 adult *A. americanum* ticks, as well as 6 adult *Haemaphysalis longicornis* ticks.

Tick pool homogenization, RNA extraction, and viral screening were performed by RT-qPCR with previously described protocols (*2*). Tested adult tick pools ranged from 1–5 ticks in size, and nymph tick pools ranged from 6–25 ticks per pool. None of the tick pools collected from either property tested positive for HRTV RNA.

Immunohistochemistry

CDC Infectious Diseases Pathology Branch (IDPB) received formalin-fixed, paraffin-embedded samples from heart, spleen, kidney, and liver and conducted an immunohistochemical assay for HRTV using a rabbit polyclonal serum raised against HRTV nucleocapsid protein, as previously described (*3*), at 1:1,000 dilution and using a Mach 4 Universal AP Polymer Kit (Biocare Medical) with Permanent Red Chromogen (Cell Marque/Millipore Sigma).

References

1. Brinkerhoff RJ, Gilliam WF, Gaines D. Lyme disease, Virginia, USA, 2000–2011. Emerg Infect Dis. 2014;20:1661–8. PubMed https://doi.org/10.3201/eid2010.130782

2. Savage HM, Godsey MS, Lambert A, Panella NA, Burkhalter KL, Harmon JR, et al. First detection of heartland virus (Bunyaviridae: Phlebovirus) from field collected arthropods. Am J Trop Med Hyg. 2013;89:445–52. PubMed https://doi.org/10.4269/ajtmh.13-0209

3. McMullan LK, Folk SM, Kelly AJ, MacNeil A, Goldsmith CS, Metcalfe MG, et al. A new phlebovirus associated with severe febrile illness in Missouri. N Engl J Med. 2012;367:834–41. PubMed https://doi.org/10.1056/NEJMoa1203378

Appendix Table. Infectious disease testing for patient with Heartland virus, mid-Atlantic, USA*

Test	Result
Viral	
Influenza A/B PCR, NP swab	Negative
SARS-CoV-2 PCR, NP swab	Negative
Respiratory viral panel, NP swab	Negative
HAV IgM, serum	Negative
HBV Core IgM + Hbs Ag, serum	Negative
HCV antibody, serum	Negative
CMV PCR, CSF	Negative
Enterovirus PCR, CSF	Negative
HSV1/2 PCR, CSF	Negative
HHV6 PCR, CSF	Negative
Varicella-zoster virus PCR, CSF	Negative
Human parechovirus, PCR, CSF	Negative
HIV1/2 antigen + antibody, serum	Negative
CMV PCR, serum	Negative
Epstein-Barr virus PCR, serum	**Viral load 1,280**
Varicella-zoster virus PCR, serum	Negative
Fungal	
Cryptococcus neoformans PCR, CSF	Negative
Fungal smear, blood	No hyphae
Beta D-glucan, serum	<31 (negative)
Galactomannan, serum	0.13 (negative)
Histoplasma antigen, urine	Negative
Histoplasma antibodies, serum	Negative
Blastomyces antibodies, serum	Negative
Coccidioides total antibodies, serum	Negative
Vector-borne and zoonotic	
Lyme IgG + IgM, serum	Negative
Babesia microti antibodies, serum	Negative
Erlichia panel PCR, serum	Negative
Rickettsia SFG IgM, serum	Negative
Rickettsia SFG IgG, serum	Positive
West Nile Virus IgM, serum	Positive
Anaplasma phagocytophilum PCR, serum	Negative
Coxiella burnetii IgG + IgM, serum	Negative
Leptospira PCR, serum	Negative
Bourbon virus PCR, serum	Negative
Powassan virus IgM, serum	Negative
Heartland virus PCR, serum	**Positive**
Bacterial	
Escheria coli K1 PCR, CSF	Negative
Haemophilus influenzae PCR, CSF	Negative
Listeria monocytogenes PCR, CSF	Negative
Neisseria meningitidis PCR, CSF	Negative
Streptococcus agalactiae PCR, CSF	Negative
Streptococcus pneumoniae PCR, CSF	Negative
Legionella pneumophila antigen, urine	Negative
Aerobic and anaerobic culture, blood	No growth
Culture, urine	No growth

*Bold text indicates positive results. CMV, cytomegaly virus; CSF, cerebrospinal fluid; HAV, hepatitis A virus; HBV, hepatitis B virus; HCV, hepatitis C virus; HHV6; human herpes virus 6; HSV, herpes simplex virus; NP, nasopharyngeal.