

5. Nakadai A, Kuroki T, Kato Y, Suzuki R, Yamai S, Yaginuma C, et al. Prevalence of *Salmonella* spp. in pet reptiles in Japan. *J Vet Med Sci*. 2005;67:97-101. <https://doi.org/10.1292/jvms.67.97>
6. Ebani VV, Fratini F, Bertelloni F, Cerri D, Tortoli E. Isolation and identification of mycobacteria from captive reptiles. *Res Vet Sci*. 2012;93:1136-8. <https://doi.org/10.1016/j.rvsc.2012.05.006> PMID: 22657144
7. Aubry A, Mougari F, Reibel F, Cambau E. *Mycobacterium marinum*. *Microbiol Spectr*. 2017;5. <https://doi.org/10.1128/microbiolspec.TNMI7-0038-2016>
8. Osman MM, Shanahan JK, Chu F, Takaki KK, Pinckert ML, Pagán AJ, et al. The C terminus of the mycobacterium ESX-1 secretion system substrate ESAT-6 is required for phagosomal membrane damage and virulence. *Proc Natl Acad Sci U S A*. 2022;119:e2122161119. <https://doi.org/10.1073/pnas.2122161119>
9. Meoli A, Deolmi M, Iannarella R, Esposito S. Non-tuberculous mycobacterial diseases in children. *Pathogens*. 2020;9:553.
10. van Ingen J. Diagnosis of nontuberculous mycobacterial infections. *Semin Respir Crit Care Med*. 2013;34:103-9. <https://doi.org/10.1055/s-0033-1333569>

Address for correspondence: Niaz Banaei, Department of Pathology, Stanford University, 3375 Hillview Ave, Palo Alto, CA 94304, USA; email: nbanaei@stanford.edu

Microscopic Evidence of Malaria Infection in Visceral Tissue from Medici Family, Italy

Frank Maixner, Dennis Drescher, Giulia Boccalini, Dario Piombino-Mascalì, Marek Janko, Nicole Berens-Riha, Bum Jin Kim, Michelle Gamble, Jolanthe Schatterny, Rory E. Morty, Melanie Ludwig, Ben Krause-Kyora, Robert Stark, Hyun Joo An, Jens Neumann, Giovanna Cipollini, Rudolf Grimm, Nicole Kilian, Albert Zink

Author affiliations: Eurac Research, Bolzano, Italy (F. Maixner, G. Boccalini, G. Cipollini, A. Zink); University Hospital Heidelberg, Heidelberg, Germany (D. Drescher, J. Schatterny, R.E. Morty, M. Ludwig, N. Kilian); Vilnius University, Vilnius, Lithuania (D. Piombino-Mascalì); Technical University of Darmstadt, Darmstadt, Germany (M. Janko, R. Stark); Institute of Tropical Medicine, Antwerp, Belgium (N. Berens-Riha); University of Munich, Munich, Germany (N. Berens-Riha); Oregon State

University, Corvallis, Oregon, USA (B.J. Kim); Chungnam National University, Daejeon, Korea (B.J. Kim, H.J. An); Heritage and Archaeological Research Practice, Edinburgh, Scotland, UK (M. Gamble); Kiel University, Kiel, Germany (B. Krause-Kyora); Ludwig Maximilian University, Munich (J. Neumann); Agilent Technologies, Santa Clara, California, USA (R. Grimm)

DOI: <https://doi.org/10.3201/eid2906.230134>

Microscopy of mummified visceral tissue from a Medici family member in Italy identified a potential blood vessel containing erythrocytes. Giemsa staining, atomic force microscopy, and immunohistochemistry confirmed *Plasmodium falciparum* inside those erythrocytes. Our results indicate an ancient Mediterranean presence of *P. falciparum*, which remains responsible for most malaria deaths in Africa.

The Medici family was a powerful family from Florence, Italy, that gained prominence under Cosimo de' Medici in the early 15th century (1). Dynastic power granted Medici family members a burial at the San Lorenzo Basilica in central Florence (Appendix Figure 1, panel A, <https://wwwnc.cdc.gov/EID/article/29/6/23-0134-App1.pdf>). Burial was preceded by an embalming procedure in which inner organs (viscera) were removed and placed in large terracotta jars (Appendix Figure 1, panel B).

In 2011, selected jars of organs from Medici family members were opened centuries after burial to examine their contents, revealing that multiple tissue pieces were still present (Appendix). The Institute for Mummy Studies at Eurac Research (Bolzano, Italy) received samples from the organs; we performed microscopic and molecular analysis (Appendix) of a 2.5 cm × 1.5 cm tissue piece (ID 1297) from 1 jar (Appendix Figure 1, panel C). Using microscopy, we identified a potential blood vessel containing erythrocytes (Figure, panel A). Diameters (7.24, SD ±0.14 μm; n = 37) and discocyte shapes of cells within the blood vessel were characteristic of erythrocytes (2). We conducted further microscopic evaluation of single cells and found the potential presence of a parasite that might have resided within the erythrocytes during the lifetime of the deceased family member. Giemsa staining of tissue sections confirmed our first impression (Figure, panel B) and suggested the parasite was *Plasmodium* spp.; members of this genus are the causative agent of different types of human malaria (3). We used atomic force microscopy to identify the ring stage, an immature developmental stage of *P. falciparum* that is dominant in peripheral blood of infected patients and a diagnostic

hallmark (Figure, panel C). We verified the presence of *P. falciparum* by using immunohistochemistry with polyclonal mouse antiserum against *Plasmodium* spp.-specific aldolase (Appendix Figure 1, panels D, E) and a monoclonal antibody against *P. falciparum*-specific histidine-rich protein HRPII (Appendix Figure 1, panels F, G). We confirmed results by using immunofluorescence analysis with antibody against *P. falciparum* endoplasmic reticulum

resident protein Pf39 (Appendix Figure 1, panels H, I). All isotype controls were negative (Appendix Figure 1, panels E, G, I). Not all observed parasitized erythrocytes were labeled by the antiserum, likely because of tissue degradation over the centuries. We verified a progressed state of biomolecule degradation by additional DNA-based analysis.

We determined that parasitemia was 38% in the Medici tissue, which appeared high (Appendix

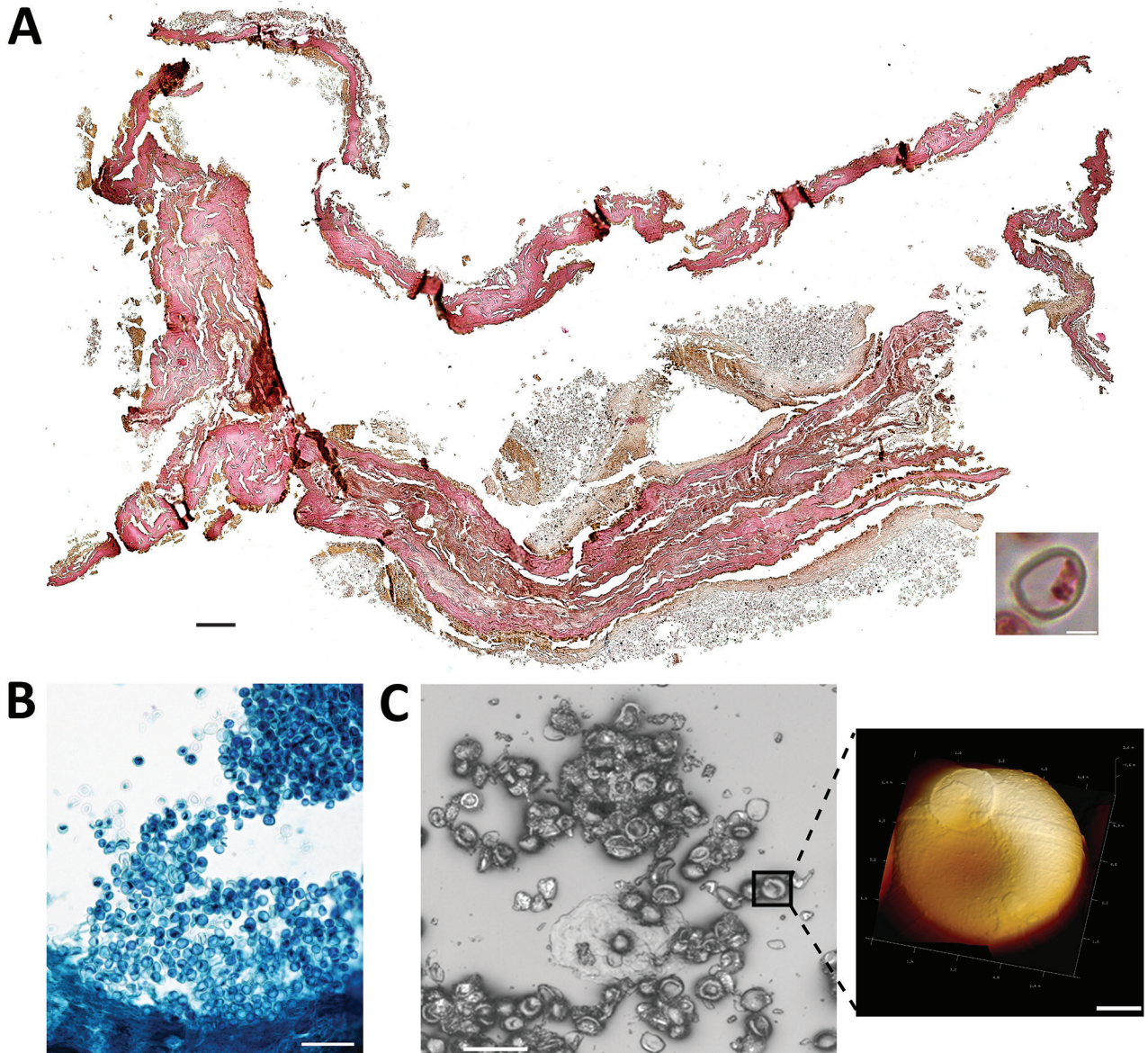


Figure. Microscopic analysis of malaria infection in visceral tissue from Medici family, Italy. We evaluated a 2.5 cm × 1.5 cm tissue piece (ID 1297) from 1 jar containing viscera of a Medici family member and identified a potential blood vessel containing erythrocytes. A) Histological cross section of the tissue stained with hematoxylin and eosin; scale bar indicates 200 μ m. Inset shows a possible erythrocyte; scale bar indicates 3 μ m. B) Giemsa staining of a paraffin section of viscera suggesting the presence of parasites within the erythrocytes. Scale bar indicates 50 μ m. C) Atomic force microscopy (AFM) of the tissue section. An optical microscope was used to define appropriate sample areas for AFM imaging (left image); scale bar indicates 20 μ m. Enlarged area at right shows a ring stage of *Plasmodium falciparum* in an erythrocyte; scale bar indicates 2 μ m.

Figure 1, panel J). However, instead of peripheral blood, we investigated tissues that might have had higher than expected parasitemia from sequestration of erythrocytes parasitized by mature asexual developmental stages (trophozoite and schizonts) of *P. falciparum* (4). Erythrocytes were visible in the tissue and were not washed away after embedding, further suggesting the presence of malaria parasites because they can trigger blood coagulation that might have kept the cells in place (5). High parasitemia within tissues is likely dependent on *P. falciparum* developmental stages (4). Erythrocytes infected with juvenile ring stages can be found in the peripheral blood of patients, whereas mature developmental stages are absent (6). Erythrocytes that contain more mature developmental stages can adhere to endothelial cells that line blood vessels within inner organs (6).

The most striking parasite-derived erythrocyte modification is the establishment of secretory organelles, known as Maurer's clefts, that reside within the cytoplasm of terminally differentiated host erythrocytes infected with *P. falciparum* (7). Similar organelles also exist in the cytoplasm of erythrocytes infected by other pathogenic *Plasmodium* spp. (7). During *P. falciparum* infections, Maurer's clefts are crucial for initiating host-parasite interactions; they are responsible for severe disease and patient death by enabling protein trafficking that causes cytoadherence within organs (4). By using Giemsa staining, we observed delicate stipplings within the cytoplasm of infected erythrocytes in the Medici tissue, indicative of Maurer's clefts (Appendix Figure 1, panel J). We quantified the stipplings; numbers were comparable to what can be observed within infected erythrocytes of malaria patients and in vitro-infected erythrocyte cultures.

We performed glycan analysis by using mass spectrometry and molecular analyses (Appendix). We identified a unique glycan found in erythrocyte B antigen (Appendix Figure 2, panels A–D), further indicating the presence of erythrocytes in the tissue. However, parasite DNA was undetectable by PCR. Metagenomic sequencing showed only 0.06% of all reads were host DNA; 2 reads could be unambiguously assigned to *P. falciparum* (Appendix Figure 2, panel E).

Medici family members were known to hunt in marshlands around Florence and in Tuscany that served as breeding grounds for mosquito vectors capable of transmitting *Plasmodium* spp. parasites (8). In 2010, immunoassays were used to analyze bones of 4 Medici family members who might have died from malaria; *P. falciparum* was detected (9). Our

observations agree with previous studies of ancient human remains, suggesting a Mediterranean presence of malaria from the era of ancient Egypt to modern times (10). Malaria remains a major health threat for persons in Africa, mostly affecting pregnant women and children. Malaria is a curable disease; however, persons in malaria-endemic areas still lack access to proper healthcare. Developing *Plasmodium* resistance to standard treatments further hampers positive therapeutic outcomes.

Acknowledgments

We thank Donatella Lippi and Elsa Pacciani for their support during the initial phase of the study.

Funding was provided by the European Regional Development Fund 2014–2020_CALL-FESR 2017 Research and Innovation_Autonomous Province of Bolzano-South Tyrol_Project: FESR1078-MummyLabs.

About the Author

Dr. Maixner is coordinator at the EURAC Institute for Mummy Studies and head of the ancient DNA laboratory. His research interests focus on genomic and relationship analysis of ancient human remains and identification of ancient pathogens that caused disease.

References

1. The Medici: citizens and masters. In: Black R, Law JE, editors. Villa I Tatti Series 32, the Harvard University Center for Italian Renaissance Studies. Cambridge (MA): Harvard University Press; 2015.
2. Kilian N, Dittmer M, Cyrklaff M, Ouermi D, Bisseye C, Simpore J, et al. Haemoglobin S and C affect the motion of Maurer's clefts in *Plasmodium falciparum*-infected erythrocytes. *Cell Microbiol*. 2013;15:1111–26. <https://doi.org/10.1111/cmi.12102>
3. World Health Organization. World malaria report 2021 [cited 2023 Jan 1]. <https://www.who.int/teams/global-malaria-programme/reports/world-malaria-report-2021>
4. Cyrklaff M, Sanchez CP, Kilian N, Bisseye C, Simpore J, Frischknecht F, et al. Hemoglobins S and C interfere with actin remodeling in *Plasmodium falciparum*-infected erythrocytes. *Science*. 2011;334:1283–6. <https://doi.org/10.1126/science.1213775>
5. Francischetti IMB, Seydel KB, Monteiro RQ. Blood coagulation, inflammation, and malaria. *Microcirculation*. 2008;15:81–107. <https://doi.org/10.1080/10739680701451516>
6. Lee WC, Russell B, Rénia L. Sticking for a cause: the falciparum malaria parasites cytoadherence paradigm. *Front Immunol*. 2019;10:1444. <https://doi.org/10.3389/fimmu.2019.01444>
7. Mundwiler-Pachlatko E, Beck HP. Maurer's clefts, the enigma of *Plasmodium falciparum*. *Proc Natl Acad Sci USA*. 2013;110:19987–94. <https://doi.org/10.1073/pnas.1309247110>

8. Menning CB. The noble hunt: the "Libro della caccia" of Angelo del Bufalo. *Yale Univ Libr Gaz*. 2001;76:27-35.
9. Fornaciari G, Giuffra V, Ferroglio E, Gino S, Bianucci R. *Plasmodium falciparum* immunodetection in bone remains of members of the Renaissance Medici family (Florence, Italy, sixteenth century). *Trans R Soc Trop Med Hyg*. 2010;104:583-7. <https://doi.org/10.1016/j.trstmh.2010.06.007>
10. Boualam MA, Pradines B, Drancourt M, Barbieri R. Malaria in Europe: a historical perspective. *Front Med*. 2021;8:691095. <https://doi.org/10.3389/fmed.2021.691095>

Address for correspondence: Albert Zink, Institute for Mummy Studies, Eurac Research, Viale Druso 1, 39100 Bolzano, Italy; email: albert.zink@eurac.edu

Enhanced Adenovirus Vaccine Safety Surveillance in Military Setting, United States

John Iskander, Scott Blanchet, Caitlin Springer, Patrick Rockwell, Dana Thomas, Satish Pillai

Author affiliations: United States Coast Guard, Washington, DC, USA (J. Iskander, D. Thomas, S. Pillai); United States Coast Guard Academy, New London, Connecticut, USA (S. Blanchet, C. Springer, P. Rockwell)

DOI: <https://doi.org/10.3201/eid2906.230331>

The US Coast Guard Academy began adenovirus vaccination of incoming cadets in 2022. Of 294 vaccine recipients, 15%–20% had mild respiratory or systemic symptoms within 10 days postvaccination but no serious adverse events after 90 days. Our findings support the continued use of adenovirus vaccines in congregate military settings.

Adenovirus infection results in considerable illness among congregate military populations (1). US Food and Drug Administration–approved use of a live, oral, bivalent adenovirus vaccine for military populations began in 2011 and was associated with substantial decreases in adenovirus infection incidence at US military basic training centers (2,3). The US Naval Academy introduced adenovirus vaccination in 2018 after a large adenovirus outbreak (4). An adenovirus outbreak involving ≈300 cadets occurred at the US

Coast Guard Academy (CGA) in 2019 (5). Adenovirus vaccines were introduced for incoming first-year CGA cadets on June 28, 2022. To supplement postlicensure data on adenovirus vaccine safety (6), we monitored postvaccination signs and symptoms in those cadets.

We developed a monitoring system to account for military training features, such as restricted cellphone access and a time-sensitive, regimented curriculum. For sick call visits occurring ≤10 days after vaccination, the CGA clinic used a monitoring tool (Appendix, <https://wwwnc.cdc.gov/EID/article/29/6/23-0331-App1.pdf>) consisting of 17 postvaccination signs or symptoms obtained from clinical trial results (7,8). We measured vaccine uptake and inability to swallow pills and monitored cadets for 90 days after vaccination for US Food and Drug Administration–defined serious adverse events (9).

Cadets received an in-person briefing from CGA clinic staff on June 27, 2022. The CGA training cadre, with whom the cadets had daily contact, were briefed by clinic leadership on the paper-based reporting tool, reporting requirements, and referring ill cadets to the CGA clinic. Before vaccination, cadets were given the Centers for Disease Control and Prevention adenovirus vaccine information statement and opportunity to ask questions. Subsequently, if cadets sought care for illness at the CGA clinic, staff used the reporting tool to record whether any of the 17 signs and symptoms were present.

During the initial vaccination period (June 28–30, 2022), 293 (97.3%) of 301 first-year cadets received the adenovirus vaccine; 4 (1.3%) cadets were unable to swallow the vaccine. Of 4 cadets isolated for COVID-19 during the initial vaccination period, only 1 subsequently received the vaccine. Of 294 vaccinated cadets, a total of 159 (54.1%) received 1 other vaccine and 53 (18.0%) received ≥2 additional vaccines.

The average age of the 294 vaccine recipients was 18.25 years; 57% were male, and 43% female. During June 30–July 8, 2022, ≈100 first-year cadets sought care at the CGA clinic for illness, and 65 (22.1%) cadets reported ≥1 vaccine surveillance sign or symptom. Commonly reported signs and symptoms were cough (20.1%), sore throat (17.0%), headache (16.0%), fatigue (16.0%), nasal congestion (15.3%), and shortness of breath (11.6%) (Table). Frequencies of gastrointestinal symptoms among cadets seeking care at the clinic during the 10-day period after vaccination were 2.3% for abdominal pain, 3.7% for diarrhea, 4.0% for vomiting, and 8.3% for nausea (Table). During the 90 days after vaccination, no serious adverse events were reported, including hospitalization, Guillain-Barre syndrome, or death.