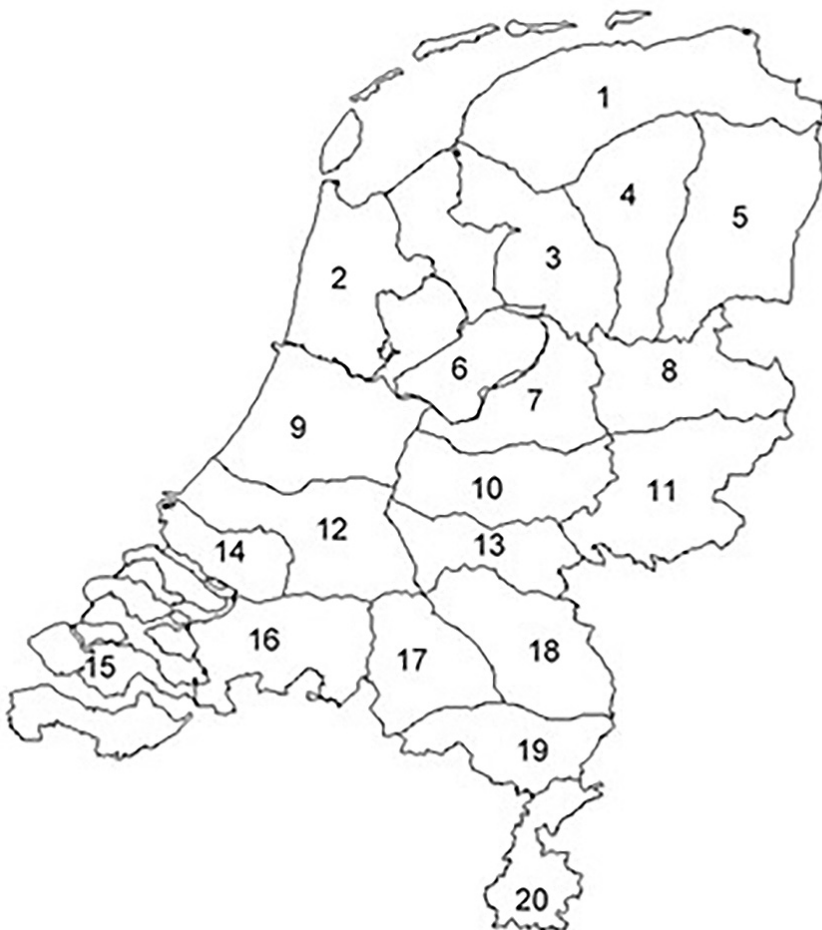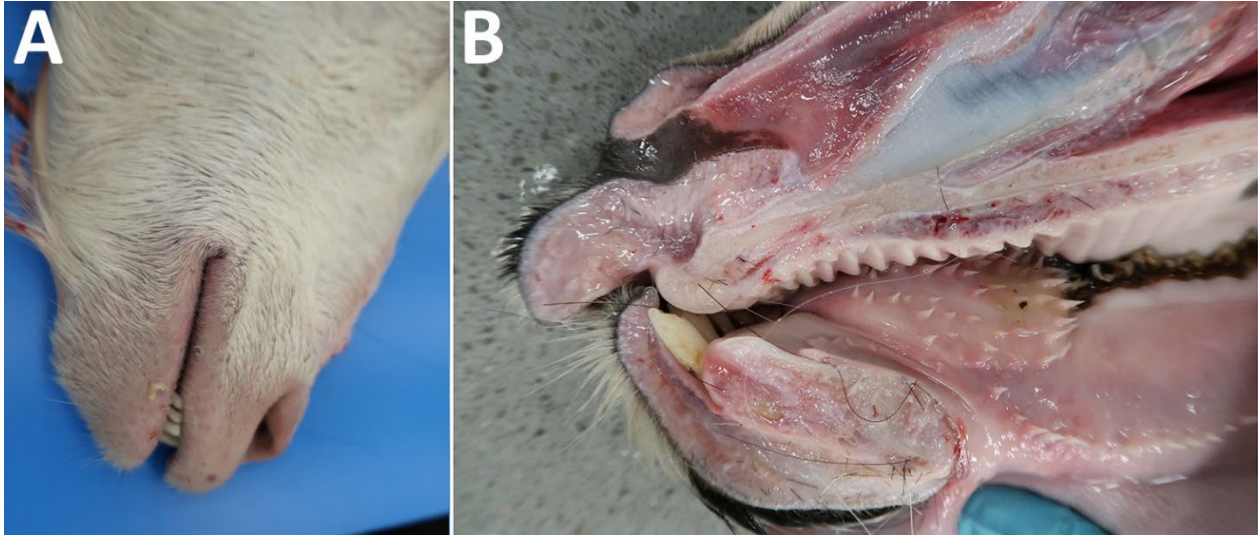


Emergence of Bluetongue Virus Serotype 3, the Netherlands, September 2023

Appendix



Appendix Figure 1. Location of each of the 20 compartments within the Netherlands proposed by the European Union Commission Decision 2005/393/EC.



Appendix Figure 2. Edema formation in the head of a goat caused by bluetongue virus serotype 3 infection in the Netherlands. Bluetongue disease was reported in a goat on September 19, 2023, and showed signs of edema of the lips along with fever. A) Goat head. B) Cross-section of goat head.