

EID cannot ensure accessibility for supplementary materials supplied by authors. Readers who have difficulty accessing supplementary content should contact the authors for assistance.

Ophthalmomyiasis Outbreak Caused by *Oestrus ovis* Infection, Algeria, 2025

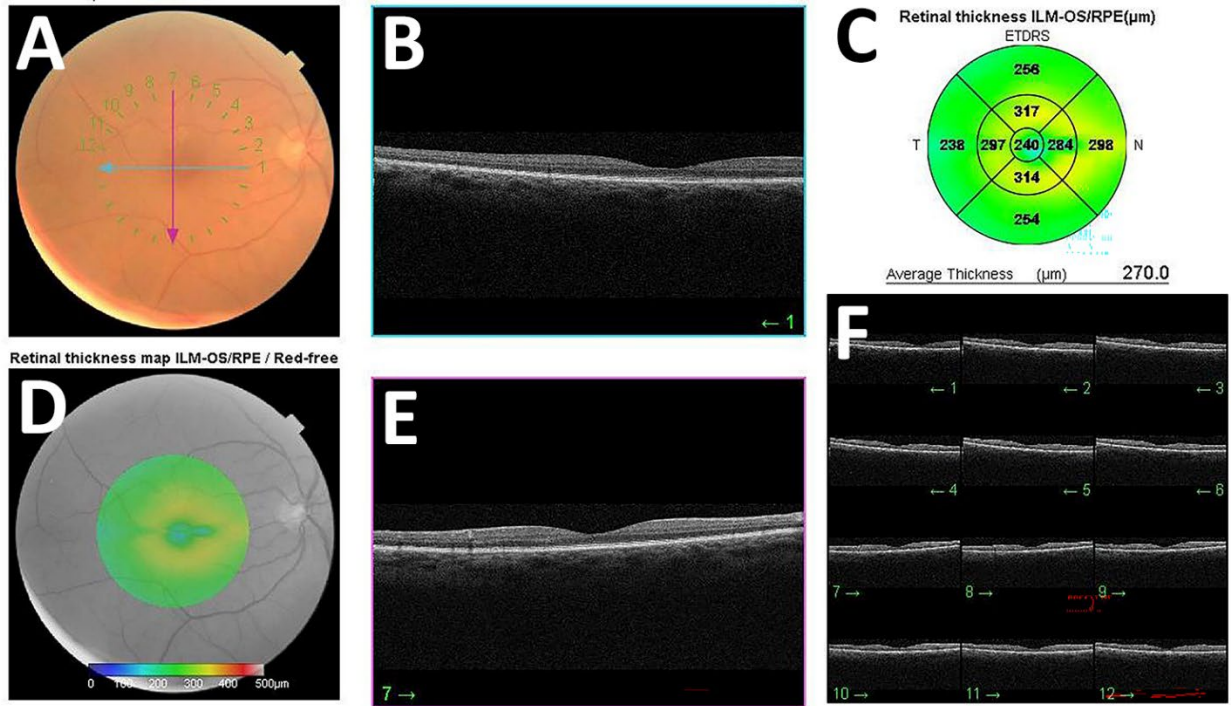
Appendix

Appendix Table 1. Demographic characteristics, sheep exposure history, ocular findings, larvae burden, and timing of disease onset among 17 patients with acute external ophthalmomyiasis caused by *Oestrus ovis* after sheep exposure during Eid al-Adha, Algeria, 2025*

Patient No.	Sex	Age	Affected eye	Sheep exposure	Symptoms	Slit-lamp examination findings	Larvae numbers	From exposure to first symptom	From exposure to slit-lamp examination
1	F	35	OS	Yes	Foreign body sensation, redness, itching, tearing, Feeling of fullness, pricking pain, photophobia	motile larvae (1–2mm) in conjunctiva, palpebral edema, conjunctival congestion, mucous discharge, epiphora, mucous discharge, punctate keratitis	22	2h	5h
2	F	26	OD	Yes	Foreign body sensation, redness	motile larvae (1–2mm) in conjunctiva, conjunctival congestion, mucous discharge	4	4h	6h
3	M	46	OS	Yes	Foreign body sensation, redness, Feeling of fullness, eye discharge	motile larvae (1–2mm) in conjunctiva, conjunctival congestion, edema, mucous discharge	7	6h	10h
4	M	28	OS	Yes	Foreign body sensation, redness, itching, tearing, Feeling of fullness, pricking pain, photophobia, eye discharge, burning feeling	motile larvae (1–2mm) in conjunctiva, conjunctival congestion, edema, mucous discharge, epiphora, corneal epithelial defects	15	4h	9h
5	M	37	OS	Yes	Foreign body sensation, redness, itching, tearing, Feeling of fullness, pricking pain, photophobia, eye discharge	motile larvae (1–2mm) in conjunctiva, conjunctival congestion, edema, mucous discharge, epiphora, punctate keratitis	18	1h	8h
6	F	38	OS	Yes	Foreign body sensation, redness, itching, tearing, feeling of fullness, pricking pain, photophobia, eye discharge	motile larvae (1–2mm) in conjunctiva, conjunctival congestion, edema, mucous discharge, epiphora, punctate keratitis	16	2h	7h
7	F	42	OS	Yes	Foreign body sensation, redness, pricking pain, burning feeling, eye discharge	motile larvae (1–2mm) in conjunctiva, conjunctival congestion, mucous discharge	8	5h	8h

Patient No.	Sex	Age	Affected eye	Sheep exposure	Symptoms	Slit-lamp examination findings	Larvae numbers	From exposure to first symptom	From exposure to slit-lamp examination
8	M	34	OD	Yes	Foreign body sensation, redness, itching, tearing, pricking pain, feeling of fullness, photophobia, eye discharge	motile larvae (1–2mm) in conjunctiva, conjunctival congestion, edema, mucous discharge, punctate keratitis	14	1h	9h
9	M	43	OS	Yes	Foreign body sensation, redness, eye discharge	motile larvae (1–2mm) in conjunctiva, conjunctival congestion, mucous discharge	7	5h	10h
10	M	39	OS	Yes	Foreign body sensation, redness, itching, tearing, feeling of fullness, pricking pain, photophobia, burning feeling, eye discharge	motile larvae (1–2mm) in conjunctiva, conjunctival congestion, edema, mucous discharge, corneal epithelial defects	17	3h	25h
11	M	45	OS	Yes	Foreign body sensation, redness, itching, tearing, feeling of fullness, pricking pain, photophobia, burning feeling, eye discharge	motile larvae (1–2mm) in conjunctiva, conjunctival congestion, edema, epiphora, mucous discharge, corneal epithelial defects	9	4h	29h
12	M	41	OD	Yes	Foreign body sensation, redness, tearing, pricking pain, photophobia, burning feeling, eye discharge	motile larvae (1–2mm) in conjunctiva, conjunctival congestion, edema, epiphora, mucous discharge, punctate keratitis	5	3h	27h
13	F	32	OD	Yes	Foreign body sensation, redness, itching, pricking pain	motile larvae (1–2mm) in conjunctiva, conjunctival congestion, punctate keratitis	7	5h	26h
14	F	33	OS	Yes	Foreign body sensation, redness, itching, pricking pain, feeling of fullness, eye discharge	motile larvae (1–2mm) in conjunctiva, conjunctival congestion, edema, mucous discharge, punctate keratitis	6	2h	32h
15	M	36	OD	Yes	Foreign body sensation, redness, itching, feeling of fullness, photophobia, burning feeling, eye discharge	motile larvae (1–2mm) in conjunctiva, conjunctival congestion, edema, mucous discharge	9	4h	30h
16	F	41	OS	Yes	Foreign body sensation, redness, itching, feeling of fullness, eye discharge	motile larvae (1–2mm) in conjunctiva, conjunctival congestion, edema, mucous discharge	8	10h	28h
17	M	44	OS	No	Foreign body sensation, redness, itching	motile larvae (1–2mm) in conjunctiva, conjunctival congestion, edema	7	-	0h

*F indicates female; M, male; OD, right eye; OS, left eye; h, hours; and mm, millimeters. Larvae were clinically identified as *Oestrus ovis*. The final 2 columns indicate the intervals from sheep exposure to first symptom onset and to slit-lamp examination, respectively.



Appendix Figure. Posterior segment evaluation in patients with acute external ophthalmomyiasis caused by *Oestrus ovis* after sheep exposure during Eid al-Adha, Algeria, 2025. Representative color fundus photography, red-free fundus imaging, and optical coherence tomography images show no evidence of posterior segment involvement, including no retinal, choroidal, vitreous, or optic nerve abnormalities attributable to intraocular larval migration. OCT, optical coherence tomography.